

## Secondary Syphilis with Persisting Hard Chancre on the Forearm

Pedro Andrade<sup>1</sup>, Maria J. Juliao<sup>2</sup>, José P. Reis<sup>1</sup> and Américo Figueiredo<sup>1</sup>

<sup>1</sup>Department of Dermatology and Venereology, and <sup>2</sup>Department of Anatomical Pathology, Coimbra University Hospital, 3000-075 Coimbra, Portugal.  
E-mail: pedro.andrade@portugalmail.com

Accepted Jan 16, 2012; Epub ahead of print May 8, 2012

Syphilis is a treponemal infection, which is distributed worldwide and transmitted, in most cases, by sexual contact with infected mucosae. In its primary stage, typical lesions arise on the genitals in most cases, and occasionally on oral, pharyngeal or anorectal areas (1). Due to the characteristic lack of symptoms and frequent location in occult mucosal areas, primary syphilis might be misdiagnosed or remain unnoticed. Secondary manifestations are polymorphic and arise inconsistently in time, giving rise to frequent diagnostic difficulties.

We describe here a case of secondary syphilis with persisting hard chancre on the forearm.

### CASE REPORT

A 43-year-old man was observed with a mildly pruritic generalized erythematous maculopapular eruption (Fig. 1), with thin scale in some areas, affecting mainly the trunk and proximal limbs, sparing the palms and soles, without mucosal involvement. The eruption had arisen 10 days previously, on the 8<sup>th</sup> day of antibiotic therapy with levofloxacin 500 mg twice daily, which had been prescribed by his general physician for a nodular lesion on the forearm, and persisted after a short treatment with prednisone 20 mg daily. The single asymptomatic round ulcerated nodular lesion had arisen nearly 30 days previously on the middle third of the volar surface of the left forearm: it was approximately 1.5 cm in

width, had raised indurated erythematous borders and did not respond to the antibiotic or steroid treatments (Fig. 1). No preceding local trauma or insect bite was reported by the patient. Complete physical examination did not reveal enlarged lymph nodes or other significant changes.

This previously healthy patient had 2 regular male sexual partners in the previous 6 months, and reported irregularly protected insertive fisting oral and anal sex with both. There was no history of genital ulceration or sexually transmitted infections (STI).

A blood cell count and a basic serum biochemical analysis were performed and did not reveal any significant results, concerning eosinophil count, liver and kidney functions and serum C-reactive protein. Interestingly, a reactive rapid plasma reagin test (RPR) was obtained (titre 1/32) and confirmed by a reactive treponemal IgM/IgG chemiluminescence immunoassay (CLIA), allowing the establishment of secondary syphilis as a definitive diagnosis. The patient described the regular practice of insertive unprotected anal fisting with both sexual partners and the recent occurrence of similar generalized cutaneous lesions in one of them. Histopathological examination of a biopsy of the forearm nodule revealed a very dense dermal infiltrate with abundant lymphocytes, plasma cells and histiocytes (Fig. 1), consistent with an extragenital syphilitic hard chancre; the presence of spirochetes was confirmed by high magnitude observation using Warthin-Starry staining

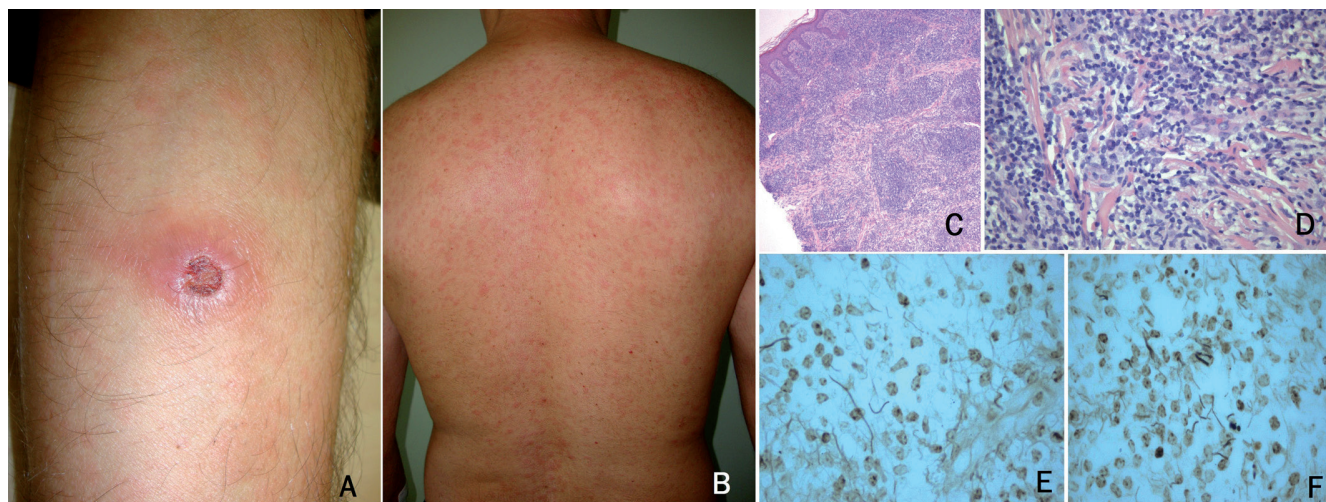


Fig. 1. (A) Ulcerated nodular lesion in the volar surface of the left forearm. (B) Mildly pruritic maculopapular exanthema affecting mainly the trunk and the proximal limbs. (C and D) Histological analysis of the nodular lesion on the forearm: dense dermal lymphocytic, plasmocytic and histiocytic infiltrate (haematoxylin and eosin (H&E)  $\times 50$  and  $\times 400$ , respectively). (E and F) Histological analysis of the nodular lesion on the forearm: curved shaped spirochetes (Warthin-Starry,  $\times 1000$ ).

(Fig. 1). A sparse dermal lymphocytic and plasmocytic infiltrate was observed on histopathological analysis of one of the disseminated erythematous patches, as expected for secondary syphilis.

Serological and molecular tests for other sexually transmitted diseases (hepatites B and C viruses (HCV), HIV and *Chlamydia trachomatis* infections) were negative. Treatment was performed with a single intramuscular dose of benzathine penicillin (2,400,000 U). No adverse effects were observed following the treatment. Complete regression of all cutaneous lesions was observed within 16 days, resulting in a small atrophic scar on the left forearm. Both sexual partners were traced, submitted to STI screening and offered treatment with a single intramuscular dose of benzathine penicillin (2,400,000 U); one of them presented with typical syphilitic exanthema with extension to palms and soles, and reacted both to RPR and CLIA; no clinical lesions were observed and RPR/CLIA tests were not reactive in the other sexual partner.

## DISCUSSION

Extragenital hard chancres are not uncommon, particularly in females and men who have sex with men (MSM) performing receptive anal or oral sex, and are frequently located in the oral cavity, anorectal mucosa, and perianal/perioral skin (1). Hard chancres occurring in other locations are extremely rare, and have been described on the nipples (2–4), the ear (5) and the nose (6) (secondary to local bites), and also the fingers (7, 8) and hand (9) (in association with manipulation of infected mucosae). Fisting, also known as mano-brachial sex, is a sexual practice consisting of the introduction of the hand and forearm in the vagina or rectum, being increasingly common (but not exclusive) among MSM. It is frequently associated with illicit drug consumption (mainly inhaled amyl or butyl nitrates) and has been recently confirmed as an independent risk factor for HCV and human papillomavirus transmission (10, 11). An association between syphilis and fisting has rarely been described (12). In fact, to our knowledge, this is the first reported case of a hard chancre located in the forearm, resulting from the direct contact with infected anorectal mucosa in the context of unprotected fisting. It is also noteworthy that unconventional sexual practices might give rise to atypical presentations of sexually transmitted infections, other than the classically described. Interestingly, a similar exanthema in the setting of a genital ulcer would be promptly interpreted as syphilis.

However, in this case, being unaware of the particular sexual habits of the patient, a clinical diagnosis of hard chancre would be highly unlikely, even in the setting of a secondary syphilis-like generalized cutaneous eruption. The absence of the palmar-plantar syphilitids typically observed in secondary syphilis and the context of recent drug exposure lead to misinterpretation of the exanthema as a non-related maculopapulous adverse drug reaction. Syphilis has shown itself once more as a fascinating disease, giving rise to surprising clinical presentations. A complete anamnesis and a high level of suspicion are crucial for a correct diagnosis and must be always employed. Therefore, it must always be considered in the differential diagnosis of an undistinctive pleomorphic exanthema and excluded by serological testing.

*The authors declare no conflicts of interest.*

## REFERENCES

1. Hausteil UF, Pfeil B, Zschiesche A. Analysis of 1983–1991 Leipzig University Dermatology Clinic observed cases of syphilis. *Hautarzt* 1993; 44: 23–29.
2. Lee JY, Lin MH, Jung YC. Extragenital syphilitic chancre manifesting as a solitary nodule of the nipple. *J Eur Acad Dermatol Venereol* 2006; 20: 886–887.
3. Oh Y, Ahn SY, Hong SP, Bak H, Ahn SK. A case of extragenital chancre on a nipple from a human bite during sexual intercourse. *Int J Dermatol* 2008; 47: 978–980.
4. Sim JH, Lee MG, In SI, Park BC, Kang HY, Lee ES, Kim YC. Erythematous erosive patch on the left nipple—quiz case. Diagnosis: extragenital syphilitic chancres. *Arch Dermatol* 2010; 146: 81–86.
5. Ripa AS, Bartlett AG. Extragenital chancre of the ear. *Arch Derm Syphilol* 1947; 56: 264–266.
6. Fathallah A, Rahim GF. Primary syphilis of the bridge of the nose. *J R Fac Med Iraq* 1946; 10: 36.
7. Anemüller W, Bräuninger W, Krahl D, Trzynski A, Rose C. Chancre of the finger. A circuitous route to diagnosis. *Hautarzt* 2008; 59: 499–502.
8. Ramoni S, Cusini M, Boneschi V, Galloni C, Marchetti S. Primary syphilis of the finger. *Sex Transm Dis* 2010; 37: 468.
9. De Koning GA, Blog FB, Stolz E. A patient with primary syphilis of the hand. *Br J Vener Dis* 1977; 53: 386–388.
10. Schmidt AJ, Rockstroh JK, Vogel M, An der Heiden M, Baillot A, Krznanic I, et al. Trouble with bleeding: risk factors for acute hepatitis C among HIV-positive gay men from Germany – a case-control study. *PLoS One* 2011; 6: e17781.
11. Jin F, Prestage GP, Kippax SC, Pell CM, Donovan B, Templeton DJ, et al. Risk factors for genital and anal warts in a prospective cohort of HIV-negative homosexual men: the HIM study. *Sex Transm Dis* 2007; 34: 488–493.
12. Cusini M, Zerboni R, Muratori S, Monti M, Alessi E. Atypical early syphilis in an HIV-infected homosexual male. *Dermatologica* 1988; 177: 300–304.