

## Recurrent Postpartum Impetigo Herpetiformis Presenting After a "Skip" Pregnancy

Darshan C. Vaidya<sup>1</sup>, George Kroumpouzou<sup>1</sup> and Lionel Bercovitch<sup>1,2\*</sup>

<sup>1</sup>Department of Dermatology, The Warren Alpert Medical School of Brown University, 593 Eddy Street, APC 10, Providence, RI 02903, and <sup>2</sup>Women and Infants Hospital of Rhode Island, Providence, USA. \*E-mail: lionel\_bercovitch@brown.edu  
Accepted December 20, 2011.

Impetigo herpetiformis (IH) (pustular psoriasis of pregnancy) is a rare, potentially life-threatening pustular dermatosis of pregnancy that typically occurs in the third trimester and can be associated with hypocalcemia (1) and/or low serum levels of vitamin D (2). Although some authors consider IH as a distinct pregnancy dermatosis (3), most concur that it is a variant of generalized pustular psoriasis triggered by pregnancy. IH usually resolves postpartum, but occasionally can run a protracted course or be exacerbated by oral contraceptives (4). When treatment is necessary, the disease typically responds to oral corticosteroids. To our knowledge, only 4 cases of postpartum IH have been reported previously (5–8). We report here the fifth case of postpartum IH, and notably the first to present after a "skip" pregnancy and occur later rather than earlier in the successive pregnancy.

### CASE REPORT

A 27-year-old, gravida 2 para 2, Hispanic woman delivered a healthy, full-term baby girl. She underwent tubal ligation on postpartum day one. Several hours post-procedure, she developed a pruritic, erythematous papular eruption on the abdomen. On the second postpartum day, the eruption became diffuse, involving the face, abdomen, chest, back, upper extremities and thighs, with concomitant facial and lip edema. She subsequently developed widespread confluent vesicopustules on her abdomen (Fig. 1) with prominent discrete and coalescing reddish-pink plaques on her upper extremities and thighs. The eruption progressed over the next 12 h with the appearance of pinpoint pustules within the erythematous plaques on the chest, neck, upper extremities and thighs. No mucous membrane or palmoplantar involvement was noted. The patient denied any systemic or constitutional symptoms. She had no known drug allergies, and had received a single 5 million-unit dose of intravenous penicillin during labor for streptococcus Group B colonization, along with morphine and oxycodone with acetaminophen.

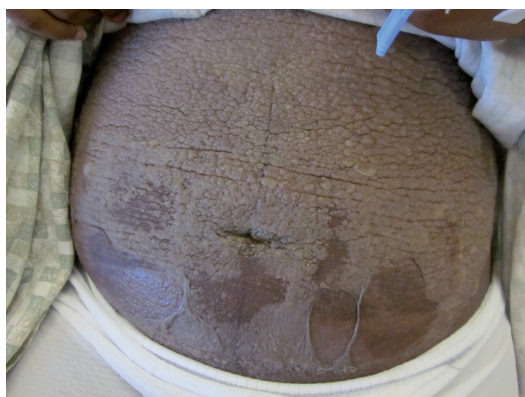

Fig. 1. Confluent, vesiculopustular lesions on the abdomen, associated with extensive erosions and pseudoverrucous features.

She had progressive leukocytosis (white blood cell count  $17.7 \times 10^9/l$  on postpartum day 3), and blood cultures were negative. Laboratory investigations revealed serum albumin 2.1 g/dl (normal 3.2–5.0 g/dl), calcium 7.9 mg/dl (8.8–10.3 mg/dl) and normal phosphorus level. The histopathologic features were those of pustular psoriasis (Fig. 2). Stains for microorganisms and direct immunofluorescence were negative. Subsequently, the patient was treated with an oral prednisone taper, starting at 40 mg/day, to which she responded dramatically with resolution of pustules.

### DISCUSSION

Whether hypocalcemia is a primary or secondary phenomenon in IH has not been adequately addressed (9). Our patient had a history of third trimester IH in her first pregnancy, an uneventful second pregnancy, and experienced postpartum IH following her third pregnancy. She had hypoalbuminemia (2.8 g/dl) and low-normal calcium 8.9 mg/dl during the third trimester of her first pregnancy. All pregnancies were reportedly with the same partner. Her first pregnancy produced a full-term male baby, while her second and third pregnancies produced full-term female babies. She denied a personal or family history of psoriasis. The disease in her first and third pregnancies may have been triggered by low or low-normal calcium, which can develop in pregnancy secondary to hypoalbuminemia, as seen in our case. The corrected serum calcium (9.4 mg/dl) and phosphorus were normal in our patient, which rules out hypoparathyroidism and vitamin D deficiency. Furthermore, hypoparathyroidism has been typically reported after surgical procedures, such as parathyroidectomy or thyroidectomy, and there is no history of such in our patient.

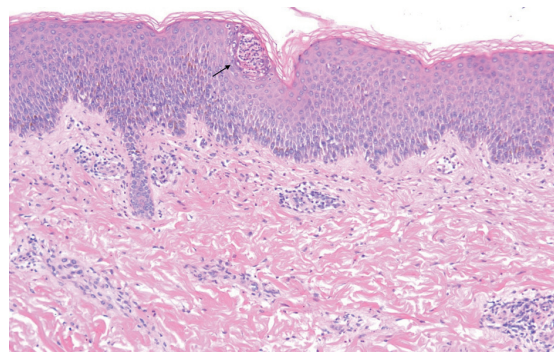


Fig. 2. Skin biopsy from the right arm shows histopathologic features of pustular psoriasis, including an intraepidermal spongiform pustule (arrow), acanthosis, mild psoriasiform hyperplasia and a sparse dermal infiltrate with scattered neutrophils (hematoxylin-eosin stain; original magnification  $\times 10$ ).

The differential diagnosis includes acute generalized exanthematous pustulosis (AGEP), subcorneal pustular dermatosis, *id* reaction, and toxin-mediated erythemas. The last 3 entities can be ruled out in our patient by the constellation of clinical and pathological findings. Nevertheless, the differentiation of IH from AGEP can be challenging, and some authors have suggested that AGEP may be a form of pustular psoriasis triggered by drugs or infections (10). Our patient had been on penicillin several days prior to the onset of the eruption, which could have triggered AGEP. Nevertheless, the patient had taken penicillin or penicillin-derived antibiotics on numerous occasions prior to and following this eruption without any adverse effects. Furthermore, the patient had third trimester IH in her first pregnancy, which occurred prior to having received penicillin at the time of labor. Furthermore, the patient had a “skip” pregnancy, in which she also received penicillin at the time of labor. Also, the absence of fever and eosinophilia, a history of IH in first pregnancy, and dramatic response to oral steroids favor IH in our case. Furthermore, classic histopathologic features of pustular psoriasis (acanthosis and psoriasiform hyperplasia) that were observed in our case are typically absent in AGEP. Histopathologic features of AGEP that would allow differentiation from similar diseases, such as marked edema of the papillary dermis, mixed superficial, interstitial, and mid/deep-dermal infiltrates containing conspicuous neutrophils and eosinophils, exocytosis of eosinophils, and single-cell necrosis of keratinocytes (10), were absent in our case.

Historically reported maternal morbidities associated with IH, such as tetany, seizures, delirium, and death secondary to cardiac or renal failure, are now uncommon (4). Placental insufficiency and/or fluid/electrolyte imbalance can lead to stillbirth, neonatal death, intrauterine growth restriction, or fetal abnormalities. Intensive fetal monitoring is, therefore, of utmost importance in the management of IH. The treatment of choice is systemic corticosteroids at a prednisone dosage of up to 60 mg/day. Improvement of IH has been reported with calcium and vitamin D supplementation (1). In corticosteroid-unresponsive severe cases, cyclosporine has been used successfully to treat IH (11). Case reports have demonstrated successful treatment of postpartum IH with oral retinoids (12) or psoralen plus ultraviolet light A (PUVA) (13). Recalcitrant IH has been treated postpartum with a combination of PUVA and clofazimine or methotrexate. In severe cases that are unresponsive to treatment, where maternal and/or fetal status is rapidly deteriorating, termination of pregnancy may be warranted.

In patients with history of IH, recurrences in subsequent pregnancies are expected with earlier onset and increased morbidity (4). Our patient uniquely had a “skip” pregnancy and later onset (postpartum day 1) than in her prior affected pregnancy. There has been no satisfactory explanation for “skip” pregnancies in various pregnancy

dermatoses. “Skip” pregnancies in herpes gestationis have been attributed to a change in consort or expression of identical human leukocyte antigen (HLA)-DR antigens by mother and fetus, although this theory has been debated (14). Nevertheless, to the best of our knowledge there was no change in consort in our case, and there is little information in the literature on HLA in IH. Tada et al. (15) reported IH in 2 sisters with similar HLA antigens, but one with a more severe course, suggesting that genetic factors may interact with environmental factors, such as pregnancy and hypocalcemia, to determine the expression of IH. As shown in this case, physicians should have a high index of suspicion for the diagnosis of IH when dealing with postpartum generalized vesiculopustular eruptions.

## REFERENCES

1. Bajaj AK, Swarum V, Gupta OP, Gupta SC. Impetigo herpetiformis. *Dermatologica* 1977; 155: 292–295.
2. Ott F, Krakowski A, Tur E, Lipitz R, Weisman Y, Brenner S. Impetigo herpetiformis with lowered serum level of vitamin D and its diminished intestinal absorption. *Dermatologica* 1982; 164: 360–365.
3. Lotem M, Katzenelson V, Rotem A, Hod M, Sandbank M. Impetigo herpetiformis: a variant of pustular psoriasis or a separate entity? *J Am Acad Dermatol* 1989; 20: 338–341.
4. Oumeish OY, Farraj SE, Bataineh AS. Some aspects of impetigo herpetiformis. *Arch Dermatol* 1982; 118: 103–105.
5. Ross MG, Tucker DC, Hayashi RH. Impetigo herpetiformis as a cause of postpartum fever. *Obstet Gynecol* 1984; 64 (3S): 49S–51S.
6. Abut YC, Bay B, Aldemir T. Postpartum impetigo herpetiformis complicated with hypovolemic shock. *Eur J Anaesthesiol* 2009; 26: 441–443.
7. Fouda UM, Fouda RM, Ammar HM, Salem M, Darouti ME. Impetigo herpetiformis during the puerperium triggered by secondary hypoparathyroidism: a case report. *Cases J* 2009; 2: 9338.
8. Park HS, Youn SJ, Sung HT, Kim WS, Lee ES. A case of impetigo herpetiformis occurring in puerperium. *Korean J Dermatol* 2004; 42: 758–761.
9. Thio HB, Vermeer BJ. Hypocalcemia in impetigo herpetiformis: a secondary transient phenomenon? *Arch Dermatol* 1991; 127: 1587–1588.
10. Halevy S, Kardaun SH, Davidovici B, Wechsler J. The spectrum of histopathological features in acute generalized exanthematous pustulosis: a study of 102 cases. *Br J Dermatol* 2010; 163: 1245–1252.
11. Imai N, Watanabe R, Fujiwara H, Ito M, Nakamura A. Successful treatment of impetigo herpetiformis with oral cyclosporine during pregnancy. *Arch Dermatol* 2002; 138: 128–129.
12. Gimenez-Garcia R, Gimenez Garcia MC, Llorente de la Fuente A. Impetigo herpetiformis: response to steroids and etretinate. *Int J Dermatol* 1989; 28: 551–552.
13. Breier-Maly J, Ortel B, Breier F, Schmidt JB, Hönigsmann H. Generalized pustular psoriasis of pregnancy (impetigo herpetiformis). *Dermatol* 1999; 198: 61–64.
14. Ibbotson SH and Lawrence CM. An uninvolved pregnancy in a patient after a previous episode of herpes gestationis (letter). *Arch Dermatol* 1995; 131: 1091–1092.
15. Tada J, Fukushima S, Fujiwara Y, Akagi Y, Kodama H, No-hara N. Two sisters with impetigo herpetiformis. *Clin Exp Dermatol* 1989; 14: 82–84.