

## Erythrodermic Psoriasis Improved by Panitumumab, But Not Bevacizumab

Aya Nishizawa, Takahiro Satoh\* and Hiroo Yokozeki

Department of Dermatology, Graduate School, Tokyo Medical and Dental University, 1-5-45 Yushima, Bunkyo-ku, 113-8519, Japan. \*E-mail: tasa-1688.derm@tmd.ac.jp

Accepted January 10, 2012.

Psoriasis is considered to be a disease mediated by Th17/Th1 immunity, with the production of interleukin (IL)-17, IL-22, and interferon (IFN)- $\gamma$ . Previous evidence has also demonstrated the possible involvement of epidermal growth factor receptor (EGFR) ligands and vascular endothelial growth factor (VEGF) (1–5). Panitumumab is a human monoclonal antibody targeting EGFR. On the other hand, bevacizumab is a humanized monoclonal antibody that binds VEGF. Here, we observed clinical effects of these antibodies administered for rectal cancer in a patient with psoriasis.

### CASE REPORT

A 77-year-old man presented with a 35-year history of psoriasis, which was diagnosed at the age of 41 years. The patient had been treated with topical corticosteroids, activated vitamin D3 analogue ointment, oral etretinate, and psoralen plus ultraviolet A (PUVA) therapy, which resulted in only partial and transient improvement. At the age of 65 years, the skin symptoms worsened and became erythrodermic (Fig. 1A–C). At the age of 67 years, he developed rectal cancer that was treated surgically. However, due to subsequent multiple metastases to the lung and lymph nodes, mFOLFOX6 therapy (modified combination therapy of folinic acid and fluorouracil with oxaliplatin) in combination with

bevacizumab (anti-vascular endothelial growth factor (anti-VEGF) antibody, 290 mg/day, 2-week intervals) was initiated and continued for 20 months, but it failed to inhibit tumour progression. Treatment with CPT-11 (irinotecan) in combination with bevacizumab for an additional year was also ineffective. Subsequently, chemotherapy was changed to CPT-11 and panitumumab (anti-EGFR antibody, 290 mg/day, 2-week intervals). Notably, when panitumumab was first given, the erythrodermic eruption showed dramatic improvement within approximately 10 days after treatment (Fig. 1D), despite the fact that bevacizumab had been ineffective for skin symptoms. Although a few small psoriatic lesions recurred periodically within 2 weeks, subsequent administration of panitumumab cleared the skin lesions, and the skin symptoms are currently well controlled together with the metastatic tumour lesions. Therapeutic effects on skin symptoms lasted at least 6 months after the initiation of panitumumab therapy.

### DISCUSSION

Psoriasis is a chronic skin disease involving keratinocyte proliferation, altered differentiation, and vascularization. EGFR and its endogenous ligands are over-expressed in skin lesions and serum in psoriasis (5, 6), leading to keratinocyte proliferation. Levels of

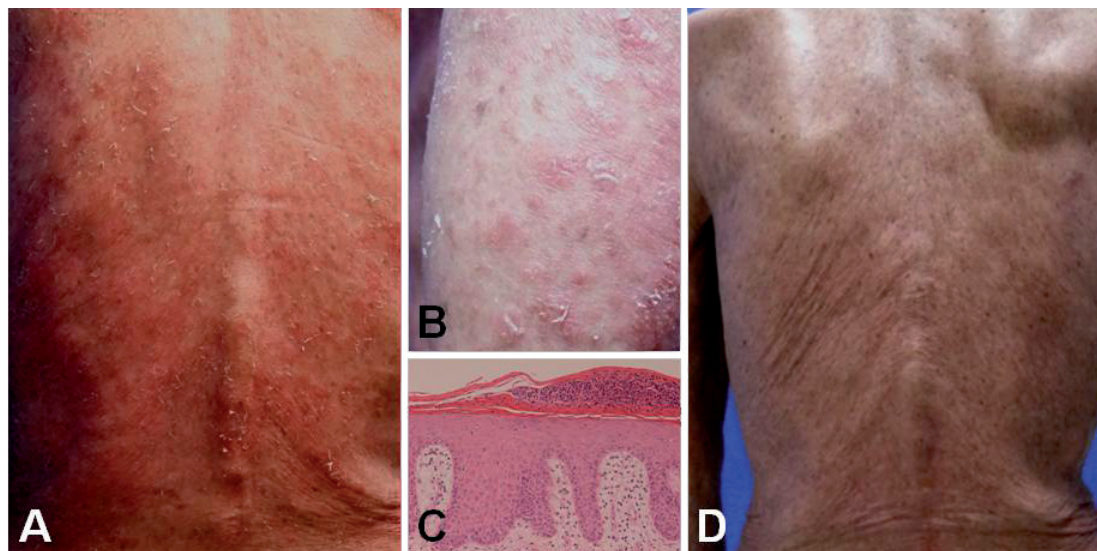


Fig. 1. Clinical and histopathological features of the case. (A, B) Before panitumumab therapy. Erythematous plaques with scales are distributed over the entire body and extremities and coalesce to form an erythrodermic eruption. (C) The epidermis shows parakeratotic hyperkeratosis with thinning of the granular layer and marked acanthosis (haematoxylin and eosin (H&E) staining, original magnification  $\times 200$ ). (D) Ten days after initial administration of panitumumab. Diffuse erythema and plaques have improved remarkably.

VEGF have also been shown to be increased in plasma and skin lesions of psoriasis (1–4), contributing to dermal vascularization. The VEGF level correlates with disease severity of the psoriasis (7, 8). The present case suggests that EGFR signalling contributes greatly to the development of psoriatic skin lesions, since panitumumab, an anti-EGFR antibody, exhibited remarkable therapeutic effects on skin symptoms in the erythrodermic psoriasis patient. This was consistent with earlier findings that cetuximab (a monoclonal antibody against EGFR) and tyrosine kinase inhibitors for EGFR signalling ameliorated psoriasis lesions and inhibited proliferation of psoriatic keratinocytes (9–11). Interestingly, however, blocking of VEGF by bevacizumab had no effects on clinical symptoms. Thus, VEGF may not be an ideal therapeutic target for psoriasis, although vascularization induced by VEGF is one of the important components of the histopathological findings in psoriasis.

*The authors declare no conflicts of interest.*

## REFERENCES

1. Bhushan M, McLaughlin B, Weiss JB, Griffiths CE. Levels of endothelial cell stimulating angiogenesis factor and vascular endothelial growth factor are elevated in psoriasis. *Br J Dermatol* 1999; 141: 1054–1060.
2. Coimbra S, Oliveira H, Reis F, Belo L, Rocha S, Quintanilha A, et al. Interleukin (IL)-22, IL-17, IL-23, IL-8, vascular endothelial growth factor and tumour necrosis factor- $\alpha$  levels in patients with psoriasis before, during and after psoralen-ultraviolet A and narrowband ultraviolet B therapy. *Br J Dermatol* 2010; 163: 1282–1290.
3. Nielsen HJ, Christensen IJ, Svendsen MN, Hansen U, Werther K, Brunner N, et al. Elevated plasma levels of vascular endothelial growth factor and plasminogen activator inhibitor-1 decrease during improvement of psoriasis. *Inflamm Res* 2002; 51: 563–567.
4. Simonetti O, Lucarini G, Goteri G, Zizzi A, Biagini G, Lo Muzio L, et al. VEGF is likely a key factor in the link between inflammation and angiogenesis in psoriasis: results of an immunohistochemical study. *Int J Immunopathol Pharmacol* 2006; 19: 751–760.
5. Anderson KS, Petersson S, Wong J, Shubbar E, Lokko NN, Carlstrom M, et al. Elevation of serum epidermal growth factor and interleukin 1 receptor antagonist in active psoriasis vulgaris. *Br J Dermatol* 2010; 163: 1085–1089.
6. Nanney LB, Stoscheck CM, Magid M, King LE, Jr. Altered [125I]epidermal growth factor binding and receptor distribution in psoriasis. *J Invest Dermatol* 1986; 86: 260–265.
7. Flisiak I, Zaniewski P, Rogalska M, Mysliwiec H, Jaroszewicz J, Chodyncka B. Effect of psoriasis activity on VEGF and its soluble receptors concentrations in serum and plaque scales. *Cytokine* 2010; 52: 225–229.
8. Flisiak I, Zaniewski P, Rogalska-Taranta M, Chodyncka B. Effect of psoriasis therapy on VEGF and its soluble receptors serum concentrations. *J Eur Acad Dermatol* 2012; 26: 302–307.
9. Ben-Bassat H. Biological activity of tyrosine kinase inhibitors: novel agents for psoriasis therapy. *Curr Opin Investig Drugs* 2001; 2: 1539–1545.
10. Neyns B, Meert V, Vandenbroucke F. Cetuximab treatment in a patient with metastatic colorectal cancer and psoriasis. *Curr Oncol* 2008; 15: 196–197.
11. Wierzbička E, Tourani JM, Guillet G. Improvement of psoriasis and cutaneous side-effects during tyrosine kinase inhibitor therapy for renal metastatic adenocarcinoma. A role for epidermal growth factor receptor (EGFR) inhibitors in psoriasis? *Br J Dermatol* 2006; 155: 213–214.