

## Time-course of the Change in Titre of Antibodies Against Type VII Collagen in a Patient with Epidermolysis Bullosa Acquisita

Mika Sato<sup>1</sup>, Asako Ishitsuka<sup>1</sup>, Yoshinao Shibuya<sup>1</sup>, Hiroyuki Kanoh<sup>1</sup>, Hiroshi Koga<sup>2</sup>, Takashi Hashimoto<sup>2</sup> and Mariko Seishima<sup>1\*</sup>

Departments of Dermatology, <sup>1</sup>Gifu University Graduate School of Medicine, 1-1 Yanagido, Gifu City 501-1194 and <sup>2</sup>Kurume University School of Medicine and Kurume University Institute of Cutaneous Cell Biology, Fukuoka, Japan. \*E-mail: marikoseishima@yahoo.co.jp  
Accepted December 11, 2011.

Epidermolysis bullosa acquisita (EBA) is an acquired mechanobullous disease, characterized clinically by blisters and erosions of the skin and mucous membranes. Patients with EBA have circulating autoantibodies against type VII collagen, which is composed of 3 central identical collagenous  $\alpha$  helical chains. Each  $\alpha$  chain is flanked by the 145-kDa amino-terminal non-collagenous 1 (NC1) domain and the 34-kDa carboxy-terminal NC2 domain. Many epitopes in type VII collagen are located within the NC1 domain (1–3), and a few epitopes are located within the NC2 domain (4). Diagnosis of EBA is usually made by direct immunofluorescence (DIF), indirect IF (IIF) using 1 M NaCl-split skin, or immunoblot analysis using dermal extracts. However, immunoblot analysis cannot detect autoantibodies against conformation-dependent epitopes, because denatured antigen sources are used as substrates. An enzyme-linked immunosorbent assay (ELISA) for detecting antibodies to NC1 and NC2 domains has been developed (5). We determined antibody titres to these antigens during the time-course of EBA using a commercially available ELISA kit in a patient with recurrent EBA. Antibody titres were reduced in parallel with the clinical activity of EBA.

### CASE REPORT

A 53-year-old Japanese woman with a body weight of 40 kg noticed many bullae on the whole skin (Fig. 1a, 1b) and the oral mucous membrane (Fig. 1c). Histological study showed subepidermal bulla formation (Fig. 1e). DIF of a biopsy specimen from a bulla showed linear deposition of immunoglobulin (Ig) G and C3 in the basement membrane zone (Fig. 1f). IIF using normal human skin sections showed IgG anti-basement membrane zone antibodies, which reacted to the dermal side in IIF using 1 M NaCl-split skin. Immunoblot assay with extracts from normal human dermis showed that the patient's serum reacted with a 290-kDa antigen that was identical to that detected by EBA control serum (Fig. 1d, lane 1), showing IgG antibodies to type VII collagen (Fig. 1d, lane 3). In contrast, the patient's serum did not show reactivity to any antigens in the extract from normal human epidermis, p200 antigen (Fig. 1d, lane 2), or laminin 332. Antibodies to desmoglein 1 and 3, bullous pemphigoid (BP) 180, and BP 230 were not detected in the patient's serum by ELISA. A diagnosis of EBA was made based on clinical features and histopathological findings, DIF, IIF using 1 M NaCl-split skin, and immunoblot assay using dermal extracts. The patient was treated with prednisolone at a dose of 1 mg/kg/day, but bullae continued to be observed, without any improvement. The addition of cyclosporine 2.5 mg/kg/day reduced bulla formation, and the dose of prednisolone could therefore be gradually reduced. However, bulla formation exacerbated when the patient was being treated with 0.3 mg/kg/day of prednisolone and 2.5 mg/kg/day

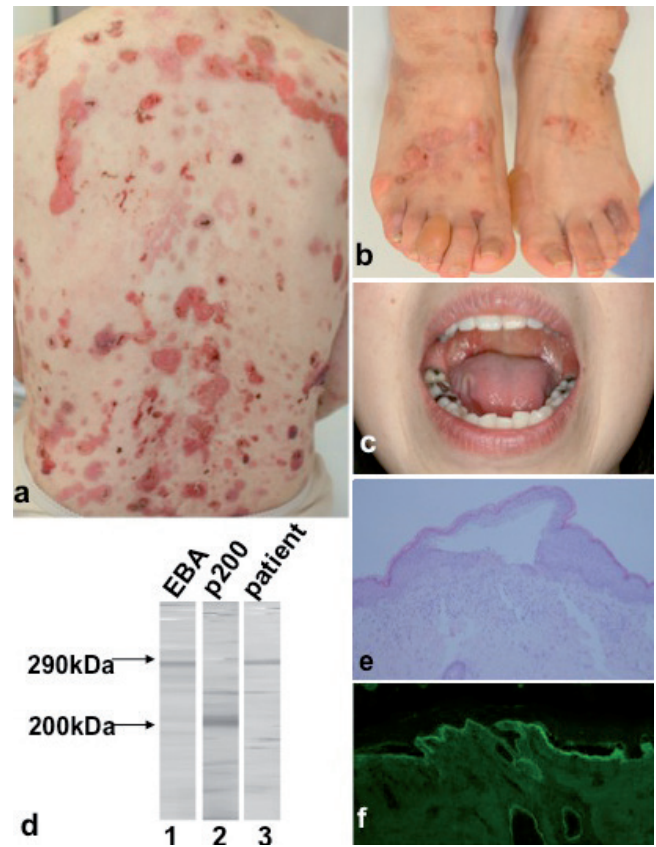


Fig. 1. (a–c) Clinical features, (d) immunoblot assay using extracts from normal human dermis, (e) histopathology, and (f) immunopathology at the time of recurrence. (a) Multiple erosions and blisters on the back, (b) dorsal aspects of the feet, and (c) soft palate and tongue. (d) The patient's serum reacted with the 290-kDa band of collagen type VII (lane 3). Lane 1: control serum from an epidermolysis bullosa acquisita (EBA) patient, lane 2: control serum from an anti-laminin gamma 1 (p200) pemphigoid patient. (e) A subepidermal blister with lymphocytes and neutrophils in the upper dermis (original magnification,  $\times 200$ ). (f) Linear deposits of IgG at the dermal-epidermal junction by direct immunofluorescence.

of cyclosporine, 2 years after the first consultation. At this time, the clinical, histopathological, and IF findings were the same as those observed at the first consultation, which indicated a recurrence of EBA. The pemphigus disease area index (PDAI) (6), which is usually used to evaluate clinical activity of pemphigus, was 99 points at that time.

We determined antibody titres against type VII collagen using the commercially available anti-type VII collagen ELISA kit (MBL, Nagoya, Japan), which detects antibodies to recombinant human NC1 and NC2 proteins of type VII collagen. Each sample was run in duplicate and the results were expressed as median values. The index value was calculated using the following equation: (optical density – negative control) / (positive control – negative control)  $\times 100$  and cut-off value (mean + 5 standard

deviation (SD) was 6.14. Antibody titres to type VII collagen were 113.9 and 81.4, at the first consultation and 8 weeks after the first consultation, respectively. Unfortunately, no measurements had been performed during the remission period. After EBA recurrence, antibody titres against type VII collagen were measured weekly by ELISA during the time-course of the disease: the antibody titre was 168.5 at the time of recurrence.

Following the administration of intravenous methylprednisolone, at a dose of 500 mg/day for 3 days, after EBA recurrence, the dose of prednisolone was increased to 1 mg/kg/day. Colchicine 0.5–1 mg/day (9) and cyclosporine 2.5 mg/kg/day were added to the prednisolone treatment (Fig. 2). This treatment regimen led to the cessation of blister and erosion formation, but many milia remained. Antibody titres to type VII collagen gradually reduced during the time-course of the disease in correlation with the clinical improvement seen with treatments. Antibody titre was decreased to 10.4 ELISA index, and PDAI was 0 point 14 weeks after the recurrence.

## DISCUSSION

In the present patient the dose of prednisolone was gradually reduced along with continuous monitoring of antibody titres to type VII collagen by ELISA. ELISA is more useful for monitoring antibody titres to type VII collagen compared with IIF using normal skin and 1 M NaCl-split skin, and immunoblot analysis using dermal extracts. Although many reports have described monitoring antibody titres in cases of BP (8) and pemphigus (9), few reports have described the determination of antibody titres to type VII collagen by ELISA in patients with EBA (5). When we measured antibody titre to type VII collagen by ELISA in another untreated patient

with EBA, the titre was 54.9. More data are required to determine the antibody titres where EBA is clinically visible. Autoantibodies in EBA have recently been evaluated by ELISA using NC1 and NC2 domains (5), and 2% of EBA sera have been found to bind exclusively to the NC2 domain. Therefore, although some reports have described the use of an ELISA only for the NC1 domain (2, 5), an ELISA using a combination of the NC1 and NC2 domains of type VII collagen is more useful for the diagnosis and monitoring of disease activity in EBA. As there is no index for clinical disease activity of EBA, we evaluated disease activity using PDAI, which is usually used for pemphigus patients (6). The present case shows that autoantibodies measured by ELISA clearly fluctuated in parallel with PDAI. These findings indicate that an ELISA could be valuable for monitoring the disease activity of EBA, and ELISA scores may be useful for tapering corticosteroid use and for therapeutic planning.

*The authors declare no conflicts of interest.*

## REFERENCES

- Lapierre JC, Woodley DT, Parente MG, Iwasaki T, Wynn KC, Christiano AM, et al. Epitope mapping of type VII collagen. Identification of discrete peptide sequences recognized by sera from patients with acquired epidermolysis bullosa. *J Clin Invest* 1993; 92: 1831–1839.
- Chen M, Chan LS, Cai X, O'Toole EA, Sample JC, Woodley DT. Development of an ELISA for rapid detection of anti-type VII collagen autoantibodies in epidermolysis bullosa acquisita. *J Invest Dermatol* 1997; 108: 68–72.
- Woodley DT, Chang C, Saadat P, Ram R, Liu Z, Chen M. Evidence that anti-type VII collagen antibodies are pathogenic and responsible for the clinical, histological, and immunological features of epidermolysis bullosa acquisita. *J Invest Dermatol* 2005; 124: 958–964.
- Chen M, Keene DR, Costa FK, Tahk SH, Woodley DT. The carboxyl terminus of type VII collagen mediates antiparallel dimer formation and constitutes a new antigenic epitope for epidermolysis bullosa acquisita autoantibodies. *J Biol Chem* 2001; 276: 21649–21655.
- Saleh MA, Ishii K, Kim Y-J, Murakami A, Ishii N, Hashimoto T, et al. Development of NC1 and NC2 domains of type VII collagen ELISA for the diagnosis and analysis of the time course of epidermolysis bullosa acquisita patients. *J Dermatol Sci* 2011; 62: 169–175.
- Rosenbach M, Murrell D, Bystryk J-C, Dulay S, Dick S, Fakhrazadeh S, et al. Reliability and convergent validity of two outcome instruments for pemphigus. *J Invest Dermatol* 2009; 129: 2404–2410.
- Ishii N, Hamada T, Dainichi T, Karashima T, Nakama T, Yasumoto S, et al. Epidermolysis bullosa acquisita: what's new? *J Dermatol* 2010; 37: 220–230.
- Kobayashi M, Amagai M, Kuroda-Kinoshita K, Hashimoto T, Shirakata Y, Hashimoto K, et al. BP180 ELISA using bacterial recombinant NC16a protein as a diagnostic and monitoring tool for bullous pemphigoid. *J Dermatol Sci* 2002; 30: 224–232.
- Cheng SW, Kobayashi M, Kinoshita-Kuroda K, Tanikawa A, Amagai M, Nishikawa T. Monitoring disease activity in pemphigus with enzyme-linked immunosorbent assay using recombinant desmoglein 1 and 3. *Br J Dermatol* 2002; 147: 261–265.

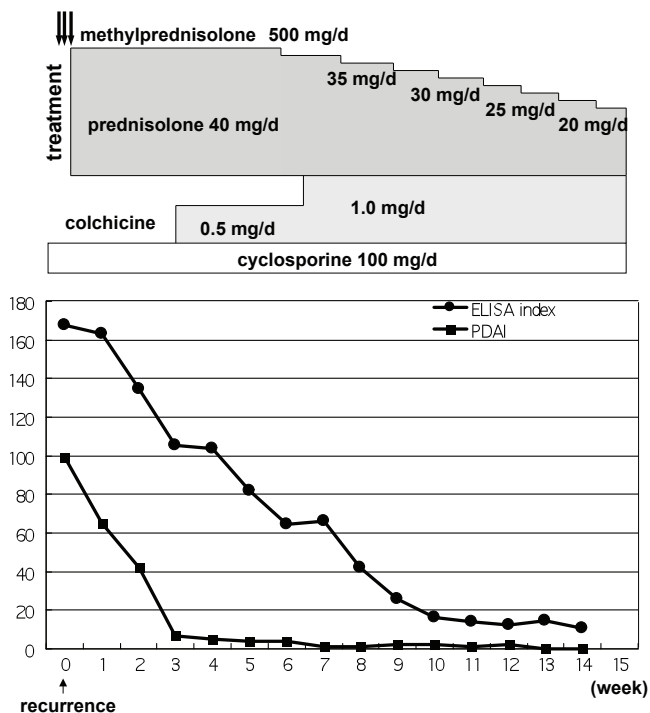


Fig. 2. Time-course of pemphigus disease area index (PDAI), antibody titre against type VII collagen (enzyme-linked immunosorbent assay (ELISA) index) and treatments in the present patient.