

**Toxic Epidermal Necrolysis Arising as a Sequela of Drug-induced Hypersensitivity Syndrome**Hideaki Watanabe<sup>1</sup>, Ryohei Koide<sup>2</sup> and Masafumi Iijima<sup>1</sup>*Departments of <sup>1</sup>Dermatology and <sup>2</sup>Ophthalmology, Showa University School of Medicine, 1-5-8 Hatanodai, Shinagawa-ku, Tokyo 142-8666, Japan. E-mail: hwatanabe@med.showa-u.ac.jp*  
Accepted November 7, 2011.

Toxic epidermal necrolysis (TEN) is a life-threatening adverse reaction that can be induced by various drugs (1). Drug-induced hypersensitivity syndrome (DIHS) (2), also referred to as drug rash with eosinophilia and systemic symptoms (DRESS) (3), is a different drug reaction caused by a limited number of specific drugs (e.g. anticonvulsants and allopurinol) (2–4). DIHS/DRESS involves multi-organ systemic reactions characterized by a rash, fever, haematopoietic dysfunction, and liver dysfunction (2–4). We describe here a fatal case of TEN which we believe represents a new type of overlap between DIHS/DRESS and TEN.

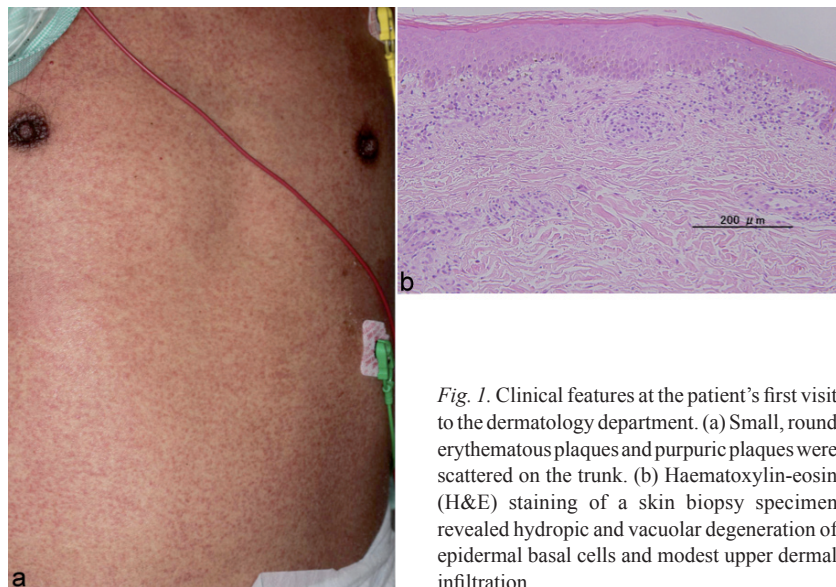
**CASE REPORT**

A 54-year-old Japanese man with a 10-year history of hypertension and hyperlipidaemia was admitted to our hospital's Neurosurgery Department on 27 November 2010 with a severe headache. Thalamic bleeding was detected by computed tomography. Beginning on 2 December 2010, the patient was treated for convulsions with oral phenytoin. He underwent a haematoma evacuation procedure on 3 December 2010. Erythematous lesions began to appear on the 41<sup>st</sup> day of phenytoin administration (11 January 2011), and the patient was referred to the Dermatology Department.

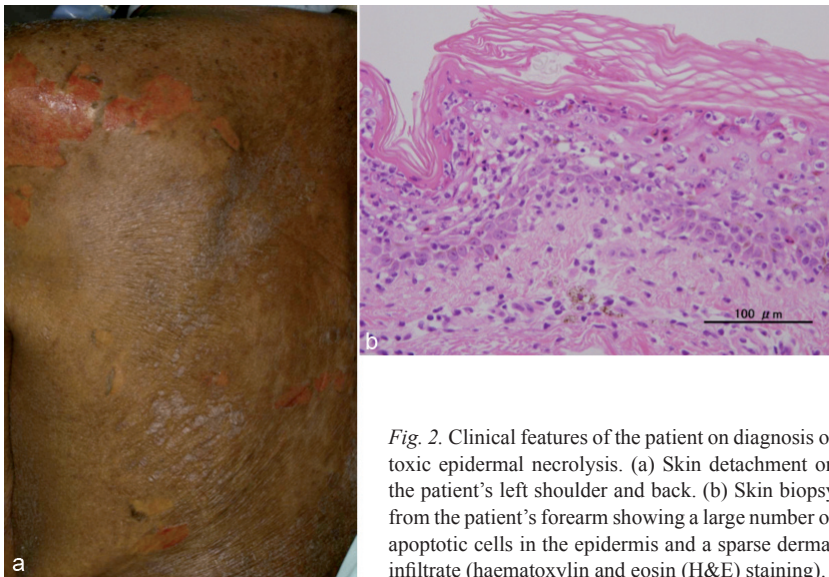
Physical examination revealed fever (39.4°C), bilateral cervical lymphadenopathy, facial oedema with erythema, and small, round, erythematous and purpuric

plaques on the trunk and extremities (Fig. 1a). The patient was negative for Nikolsky's sign. Laboratory investigations revealed the following: white blood cell count,  $18.4 \times 10^9/l$  (normal  $3.5\text{--}9 \times 10^9/l$ ) with 17.5% eosinophils (0–7%); aspartate aminotransferase, 64 IU/l (10–30 IU/l); alanine aminotransferase, 170 IU/l (5–25 IU/l); hypogammaglobulinaemia (IgG, 760 mg/dl; IgA, 51 mg/dl; IgM, 43 mg/dl; normal IgG: 800–1,750 mg/dl, IgA: 100–450 mg/dl, IgM: 45–300 mg/dl); and C-reactive protein, 8.69 mg/dl (<0.2 mg/dl). A skin biopsy obtained from the patient's forearm revealed hydropic and vacuolar degeneration of epidermal basal cells and modest upper dermal infiltration. No extensive epidermal necrosis was found (Fig. 1b). A lymphocyte transformation test (LTT) for phenytoin was positive (stimulation index (SI)=4.2, cut-off for LTT, SI=1.8). These findings fulfilled the criteria for DIHS/DRESS (2–4) and phenytoin therapy was discontinued. The patient was given systemic prednisolone (0.5 mg/kg daily) as recommended previously (3).

Although prednisolone ameliorated the skin rash, both renal dysfunction and haematopoietic organ dyscrasia had occurred, and dialysis and blood transfusion were required. Hyperbilirubinaemia was detected one week after the onset of DIHS/DRESS. One month after the onset of DIHS/DRESS, the patient's serum bilirubin level reached 42.4 mg/dl (0.3–1.0 mg/dl); it subsequently decreased while maintaining the same dose of systemic prednisolone (0.5 mg/kg, daily). Two months after the onset of DIHS/DRESS (on 12 March 2011), the patient had a tarry stool, and gastric bleeding was detected by gastrointestinal endoscopy. The administration of omeprazole was started. On 16 March 2011, ocular complications, including pseudomembranous formations and corneal epithelial defects, as well as an extensive haemorrhagic erosion on the lips, diffuse erythematous targetoid lesions, epidermal sheets, and skin detachment were seen (Fig. 2a). The patient was positive for Nikolsky's sign. An LTT for omeprazole was not performed. A skin biopsy of an erythematous targetoid lesion on the patient's forearm showed a large number of apoptotic cells in the epidermis and a sparse perivascular infiltrate, compo-



*Fig. 1. Clinical features at the patient's first visit to the dermatology department. (a) Small, round erythematous plaques and purpuric plaques were scattered on the trunk. (b) Haematoxylin-eosin (H&E) staining of a skin biopsy specimen revealed hydropic and vacuolar degeneration of epidermal basal cells and modest upper dermal infiltration.*



*Fig. 2.* Clinical features of the patient on diagnosis of toxic epidermal necrolysis. (a) Skin detachment on the patient's left shoulder and back. (b) Skin biopsy from the patient's forearm showing a large number of apoptotic cells in the epidermis and a sparse dermal infiltrate (haematoxylin and eosin (H&E) staining).

sed mainly of mononuclear cells, in the dermis (Fig. 2b). These findings were compatible with TEN (5).

The patient underwent 8 rounds of conventional plasmapheresis and was treated with intravenous immunoglobulin (5 g/day for 3 days), as recommended by other groups (6, 7). Even with a maximal skin detachment of 80%, the skin lesions resolved within 2 weeks. However, high levels of amylase, trypsin, and elastase 1 were found after the detection of TEN symptoms. Despite treatment with a protease inhibitor (gabexate mesilate), the patient's levels of pancreatic enzyme did not decrease. The patient died of multiple organ failure on day 88 after the onset of DIHS/DRESS.

## DISCUSSION

In this case, clinical symptoms of TEN appeared 2 months after the onset of DIHS/DRESS. Until now, only two cases of DIHS/DRESS associated with Stevens-Johnson syndrome (SJS)/TEN-like skin manifestations have been reported in the English literature (8, 9). Although both reported cases fulfilled all or most of the criteria for DIHS/DRESS, mucosal lesions and/or epidermal necrosis were seen from the onset of DIHS/DRESS. Recently, Tohyama et al. (3) demonstrated that the onset of SJS/TEN occurred within 3 weeks of the start of drug administration in 67% of cases, that DIHS/DRESS most frequently occurred at 4–5 weeks, and that overlapping cases developed symptoms at 4–5 weeks, as our patient did. DIHS/DRESS has several unique features that cannot be explained solely by drug aetiology. They include: delayed onset (as described above), a paradoxical worsening of clinical symptoms after withdrawal of the causative drug(s), and unexplained cross-reactivity to multiple drugs with different structures (10). Our patient had been treated with omeprazole for 4 days before the onset of TEN.

Therefore, although an LTT for omeprazole was not performed, we cannot exclude the possibility that the patient had cross-reactivity to omeprazole, and that this might have been the trigger for the subsequent development of TEN.

Our patient initially had DIHS/DRESS, and subsequently developed TEN. Based on these findings, we propose that overlapping DIHS/DRESS and SJS/TEN can occur as 2 subtypes: DIHS/DRESS and SJS/TEN both present from the onset, and SJS/TEN arising as a sequela of DIHS/DRESS.

## ACKNOWLEDGEMENT

This work was partly supported by Health and Labour Sciences Research Grants (Research on Intractable Diseases) from the Ministry of Health, Labour and Welfare of Japan.

*The authors declare no conflicts of interest.*

## REFERENCES

- Roujeau JC, Stern RS. Severe adverse cutaneous reactions to drug. *N Engl J Med* 1994; 331: 1272–1285.
- Seishima M, Yamanaka S, Fujisawa T, Tohyama M, Hashimoto K. Reactivation of human herpesvirus (HHV) family members other than HHV-6 in drug-induced hypersensitivity syndrome. *Br J Dermatol* 2006; 155: 344–349.
- Tohyama M, Hashimoto K. New aspects of drug-induced hypersensitivity syndrome. *J Dermatol* 2011; 38: 222–228.
- Bocquet H, Bagot M, Roujeau JC. Drug-induced pseudo-lymphoma and drug hypersensitivity syndrome (drug rash with eosinophilia and systemic symptoms: DRESS). *Semin Cutan Med Surg* 1996; 15: 250–257.
- Côté B, Wechsler J, Bastuji-Garin S, Assier H, Revuz J, Roujeau JC. Clinicopathologic correlation in erythema multiforme and Stevens-Johnson syndrome. *Arch Dermatol* 1995; 131: 1268–1272.
- Narita YM, Hirahara K, Mizukawa Y, Kano Y, Shiohara T. Efficacy of plasmapheresis for the treatment of severe toxic epidermal necrolysis: is cytokine expression analysis useful in predicting its therapeutic efficacy? *J Dermatol* 2011; 38: 236–245.
- Viard I, Wehrli P, Bullani R, Schneider P, Holler N, Salomon D, et al. Inhibition of toxic epidermal necrolysis by blockade of CD95 with human intravenous immunoglobulin. *Science* 1998; 282: 490–493.
- Teraki Y, Murota H, Izaki S. Toxic epidermal necrolysis due to zonisamide associated with reactivation of human herpesvirus 6. *Arch Dermatol* 2008; 144: 232–235.
- Viera MH, Perez OA, Patel JK, Jones I, Berman B. Phenytoin-associated hypersensitivity syndrome with features of DRESS and TEN/SJS. *Cutis* 2010; 85: 312–317.
- Shiohara T, Inaoka M, Kano Y. Drug-induced hypersensitivity syndrome (DIHS): A reaction induced by a complex interplay among herpesviruses and antidrug immune responses. *Allergol Int* 2006; 55: 1–8.