

Topical Tacrolimus and 50% Zinc Oxide Paste for Hailey-Hailey Disease: Less is More

Calogero Pagliarello¹, Andrea Paradisi², Caterina Dianzani³, Mauro Paradisi³ and Paolo Persichetti⁴

¹Health Services Research Unit, IDI-IRCCS, Via dei Monti di Creta 104, IT-00167 Rome, ²Dermatology Department, Catholic University of Sacred Heart, ³Dermatology Unit, and ⁴Plastic and Reconstructive Surgery Department, Campus Bio-Medico Medical School, Rome, Italy. E-mail: calogero.pagliarello@libero.it

Accepted October 26, 2011.

Hailey-Hailey disease (HHD) is an autosomal dominant condition characterized histologically by suprabasal acantholysis, resulting in oozing erosions in the flexures. It is particularly difficult to control during the hot summer months when sweat and friction aggravate the eruption. We report here a half-side treatment comparison between 50% zinc oxide paste (ZnOP) alone versus tacrolimus with 50% ZnOP on top of tacrolimus in a case of HHD. Almost complete remission was observed using 50% ZnOP alone. This case suggests that tacrolimus should be used with caution in patients with HHD.

CASE REPORT

A 64-year-old man, who was otherwise healthy, and was a farmer, was referred for treatment of an exacerbation of HHD (Fig. 1 a, b). The lesions had started in the second decade of life in the axillae, and had waxed and waned over the years. His father has the same disease, with groin, neck, and axillae involvement. Skin biopsy performed at the onset of the disease was consistent with HHD, and anti-desmoglein-1 and -3 antibodies were negative. He had been treated previously with 10 mg/day and 25 mg/day acitretin, topical calcitriol and 2% eosin solution without improvement, and with oral corticosteroid (prednisone 25mg/day) for severe relapses. For minor flare-ups he found only betamethasone 0.1% plus gentamicin 0.1% cream and antiseptics (potassium permanganate) to be valuable and practical. This time his usual topical treatment was not effective, despite the fact that his general practitioner added a course of parenteral piperacillin sodium 2 g plus 0.25 g/day tazobactam for 10 days on an empirical basis and replaced topical betamethasone with various other corticosteroids (0.1% methylprednisolone aceponate, clobetasol propionate 0.05%, prednicarbate 0.1%).

The patient refused treatment with CO₂ laser ablation and botulinum toxin type A. He stated his preference for topical treatment, avoiding oral or intralesional corticosteroids, because he would then be allowed to self-manage HHD without the need for repeated clinical follow-ups.

Topical tacrolimus has been reported to be effective in the treatment of HHD (1, 2). The patient reported that friction and excessive sweat production aggravated his symptoms, which worsened during the summer. Therefore, 50% ZnOP in olive oil, because of its drying and protective properties, was added to the tacrolimus

treatment and used as the internal control (3) in order to establish the possible therapeutic effect of tacrolimus.

His right axilla was treated with tacrolimus ointment 0.1% and 50% ZnOP on top of tacrolimus, applied twice daily, and his left axilla was treated with 50% ZnOP alone, applied twice daily.

After 3 months, the axilla treated with ZnOP alone had a better outcome (Fig. 1c, d). The patient experienced no side-effects or burning sensation. He is currently treating each relapse with 50% ZnOP, sufficient to prevent further lesions developing.

DISCUSSION

Although this treatment regimen is not definitively curative, it has no side-effects, is inexpensive, and allows the patient to self-manage his condition without medical supervision. Moreover, the patient was pleased to observe the complete re-epithelialization of a large fissured area that was hitherto unresponsive to treatment.

In the present case, excessive sweat production with maceration, promoting bacterial and fungal overgrowth, represented the main aggravating factor. In another case of recalcitrant HHD, cadexomer iodine powder was used effectively for its capability of absorbing wound exudates (4). The 50% ZnOP we used consisted of two immiscible components with comparable absorptive

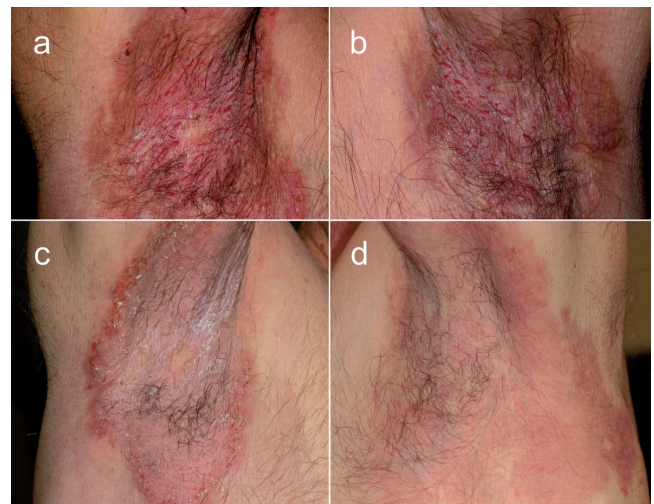


Fig. 1. (a, b) Patient with Hailey-Hailey disease before treatment. (c) After 3 months of tacrolimus plus 50% zinc oxide paste (ZnOP), twice daily. (d) After 50% ZnOP only, twice daily.

features that acted to protect the skin against aggressive body exudates, friction, and humidity (5). It is more cost-effective and easier to apply than cadexomer iodine powder.

Side-by-side comparison clearly showed that adding tacrolimus to 50% ZnOP delayed improvement, suggesting that tacrolimus in this case was not only ineffective, but it probably hampered the positive effect of 50% ZnOP on skin lesions. On reviewing the literature, we were able to find only one case of HHD being worsened by tacrolimus (6), due either to an irritant dermatitis or to *Staphylococcus aureus* infection.

The mechanism of action of 50% ZnOP in HHD is not known. Zinc oxide has recently been reported to increase *in vitro* levels of resting intracellular calcium (7), perhaps compensating for the failure of calcium-transporting ATPase type 2C member 1 encoded by the *ATP2C1* gene in HHD (8).

ACKNOWLEDGEMENT

Funding/support. This study was financially supported in part by the "Progetto Ricerca Corrente 2011" of the Italian Ministry of Health, Rome.

The authors declare no conflicts of interest

REFERENCES

1. Sand C, Thomsen HK. Topical tacrolimus ointment is an effective therapy for Hailey-Hailey disease. *Arch Dermatol* 2003; 139: 1401–1402.
2. Rabeni EJ, Cunningham NM. Effective treatment of Hailey-Hailey disease with topical tacrolimus. *J Am Acad Dermatol* 2002; 47: 797–798.
3. Torchia D, Schachner LA. Bilateral treatment for alopecia areata. *Pediatr Dermatol* 2010; 27: 415–416.
4. Tang MB, Tan ES. Hailey-Hailey disease: effective treatment with topical cadexomer iodine. *J Dermatolog Treat* 2011; 22: 304–305.
5. Juch RD, Ruffli T, Surber C. Pastes: what do they contain? How do they work? *Dermatology* 1994; 189: 373–377.
6. Laffitte E, Panizzon RG. Is topical tacrolimus really an effective therapy for Hailey-Hailey disease? *Arch Dermatol* 2004; 140: 1282.
7. Wang HJ, Growcock AC, Tang TH, O'Hara J, Huang YW, Aronstam RS. Zinc oxide nanoparticle disruption of store-operated calcium entry in a muscarinic receptor signaling pathway. *Toxicol In Vitro* 2010; 24: 1953–1961.
8. Hu Z, Bonifas JM, Beech J, Bench G, Shigihara T, Ogawa H, et al. Mutations in *ATP2C1*, encoding a calcium pump, cause Hailey-Hailey disease. *Nat Genet* 2000; 24: 61–65.