

INVESTIGATIVE REPORT

Dermal Distribution of Hyaluronan in Psoriatic Arthritis: Coexistence of CD44, MMP3 and MMP9Ulla LINDQVIST¹, Inger PIHL-LUNDIN¹ and Anna ENGSTRÖM-LAURENT²¹Department of Medical Sciences, Uppsala University, Uppsala and ²Department of Public Health and Clinical Medicine, Umeå University, Umeå, Sweden*

Psoriatic arthritis is a chronic systemic disease in which patients develop persistent inflammation of the skin and joints, leading to disability and joint damage. The extracellular component hyaluronan (HA) plays an important role in regulatory processes such as inflammation, wound healing and tumour progression. At any site of inflammation HA can be depolymerized to low-molecular weight fragments, which, in turn, induce an array of inflammatory mediators that can lead to chronic inflammation. This study describes the serum concentration and dermal distribution of HA, its receptor CD44 and the metalloproteinases 3 and 9 in skin biopsies from patients with different types of psoriatic arthritis. Fifty-one patients with psoriatic arthritis were included in the study and classified as oligo- or poly-arthritic PsA with and without treatment. Biopsies were obtained from both involved and non-involved skin and compared with biopsies from healthy individuals. Serum HA was analysed for estimation of the total turnover of HA. The main findings were an overall redistribution of HA in both involved and non-involved psoriatic skin and an epidermal imbalance between HA and CD44. The structurally and functionally important basement membrane zone was found to be disintegrated and devoid of HA irrespective of the type of articular involvement, treatment or skin affection. *Key words: hyaluronan; CD44; MMPs; psoriatic arthritis; basement membrane; inflammation.*

(Accepted September 29, 2011.)

Acta Derm Venereol 2012; 92: 372–377.

Ulla Lindqvist, Department of Medical Sciences, University Hospital, Entrance 40, 5th Floor, SE-751 85 Uppsala, Sweden. E-mail: Ulla.Lindqvist@medsci.uu.se

Hyaluronan (HA) is a non-sulphated glycosaminoglycan distributed in connective tissues throughout the body, which is especially abundant in the skin (at a concentration of approximately 200 mg/kg). HA plays an important

role in regulatory processes such as inflammation, wound healing and tumour progression (1, 2). Increased production of HA has been reported in different skin diseases (3–7), together with an increased expression of its binding adhesion receptor CD44 (8). The receptor is central in the turnover and clearance of HA (9), which is synthesized by one of three synthases (HAS 1–3). The different synthases produce HA of various chain lengths and can be activated by a wide range of molecules, e.g. cytokines and growth factors. In human dermal fibroblasts challenged with platelet-derived growth factor BB (PDGF-BB), expression of HAS 2 was increased (10, 11). High molecular weight (MW) HA, greater than 10⁶ dalton, is present in most tissues. At sites of inflammation HA of low MW appears to accumulate and promote inflammation irrespective of local elimination by CD44 (9). HA has been shown to control the production and activation of matrix metalloproteinases (MMPs) in fibroblast and keratinocyte cell cultures (12).

In healthy skin HA is distributed mainly in the intercellular space of the papillary dermis, with intense staining and uneven distribution seen in the reticular dermis. A prominent staining layer is found below the epidermis in the basement membrane (BM) zone. In epidermis HA is concentrated in the intercellular space around the keratinocytes in stratum spinosum and is also distributed in the granular layer (6, 13).

HA distribution in psoriatic dermis has not been shown to differ from dermis in healthy individuals. In epidermis diffuse HA staining in both the spinous and basal layers has been described, but the picture is not clear-cut (6). The HA staining pattern is independent of different types of skin psoriasis (6). The turnover of HA is increased in psoriasis with elevated serum levels, and the turnover probably takes place in the skin, as suction blisters from patients with active untreated psoriasis contain high concentrations of HA in the fluid (4, 7, 14).

Psoriatic arthritis (PsA) is an inflammatory disease associated with psoriasis that involves enthesal sites and synovial tissue. There are no diagnostic tests for psoriatic arthritis, but identified consistent features are used for the classification criteria according to CASPAR (Classification criteria for Psoriatic ARthritis) (15). There is no direct relationship between the amount of skin affected by psoriasis and joint inflammation, and patients with PsA

*The Editor-in-Chief has not had responsibility for this article (which originates from his own department). The article has been handled fully by one of the Associate Editors, who also made the decision to accept it.

usually exhibit low-grade skin inflammation (16). In an earlier study (14) no significant difference was observed regarding serum levels of HA between patients with PsA and those with psoriasis. In a study by Elkayam et al. (17) the same conclusion was drawn, i.e. increased levels of serum HA seem to correlate with the extent of skin involvement, but not with the severity of joint disease. This is in accordance with the disease being of the enthesal type with limited synovial inflammation. Interestingly, in a study of patients with polyarticular PsA, high levels of serum HA were reported (18).

To date, no studies have been performed showing the occurrence and distribution of HA and its receptor CD44 in relation to inflammatory mediators such as the MMPs, in skin from patients with PsA. Thus, the aim of this study was to examine the occurrence of HA in skin of PsA in relation to the receptor CD44 and to the proteinases MMP3 and MMP9, as well as measuring the HA serum level.

MATERIALS AND METHODS

The study included 51 patients with PsA according to CASPAR (15). The study was approved by the ethics committee at the University Hospital in Uppsala. All patients were examined by a rheumatologist and a dermatologist. Demographic and clinical characteristics of patients with PsA included in the study are shown in Tables I and II. Following examination of the patients, 2 skin biopsies per site (active skin lesion and normal buttock skin) were taken, one for HA staining procedure and one for immunohistochemistry (CD44, MMP3, MMP9). This was performed under local anaesthesia with lidocaine hydrochloride (Xylocaine, Astra Zeneca, Sweden) (10 mg/ml) from psoriatic skin lesions at various locations and non-involved skin from the gluteal region. Serum specimens for HA were collected from 48 patients in the afternoon. At investigation, 17 patients had no systemic or local treatment. Twenty-three patients were treated with non-steroid anti-inflammatory drugs (NSAID), 10 with methotrexate (MTX), 5 with sulphasalazine and 4 with cyclosporine. Eight patients had systemic steroids and 19 were treated with a local steroid, 15 with local calcipotriol and 8 with psoralen plus ultraviolet A (PUVA) or ultraviolet B (UVB) treatment.

Five individuals who reported that they were in good health served as controls.

Fixation, embedding and staining

To evaluate the general histopathological features, staining for HA, CD44, MMP3 and MMP9 was performed. Two separate methods for fixation and localization of the analytes were used. For staining procedures for CD44, MMP3 and MMP9 the biopsies were frozen immediately and stored at -80° until further processing of frozen sections.

Histochemical localization of HA

After the skin punch biopsies for HA were taken, the tissue specimens were transferred to saline and within 30 min fixed in a solution containing 2% formaldehyde and 0.5% glutaraldehyde in 0.1 M phosphate-buffered saline (PBS). Fixation was performed under microwave irradiation according to a modified technique for localization of HA (19). The specimens were ir-

Table I. Demographic and clinical characteristics of patients with psoriatic arthritis (PsA) according to CASPAR (CLASSification criteria for Psoriatic Arthritis) criteria (15)

Characteristics	
Number of patients, <i>n</i> (female/male)	51 (25/26)
Mean age, years ± SD	51 ± 14
Mean disease duration in skin/joints, years	22/12
Present smoker/non-smoker, <i>n</i>	9/41
Radiological erosions, <i>n</i>	36 (17: >5 joints, 12: 1-5 joints, 5 sacroileitis, 2 spondylitis)
Mean S-hyaluronan (<i>n</i> =48), µg/l	70.4
Mean B-ESR ± SD (mm/h)	19.9 ± 20.5
Mean CRP ± SD (mg/l)	17.6 ± 15.8
Mean S-immunoglobulin A ± SD	2.8 ± 1.3
Mean number of tender joints ± SD	5.6 ± 8.2 (68 joints assessed)
Mean number of swollen joints	4.3 ± 5.0 (66 joints assessed)
<i>S-HA in clinical pictures of psoriatic arthritis (n = 48)</i>	
	S-HA µg/l Mean Patients <i>n</i> (range)
Distal joint involvement only	1 15.0
Mono-oligoarticular disease	10 65.9 (10.0-225)
Polyarticular disease	24 82.0 (15.0-584)
Spondylarthropathy	2 48.9 (34.5-62.4)
Enthesis	11 58.0 (10.0-189)

SD: standard deviation; B-ESR: blood erythrocyte sedimentation rate; CRP: c-reactive protein; S-HA: serum hyaluronan.

radiated at 700 W up to 45°C and then transferred to PBS and kept at cold storage temperature until further processed for embedding. The samples were dehydrated in upgraded series of ethanol to xylene and embedded in paraffin wax. Further processing was performed according to standard procedure (19). For controls, sections were incubated with 50 units/ml Streptomyces hyaluronidase (Sigma Co., St Louis, USA) for 4 h at 37°C prior to incubation with biotinylated hyaluronan-binding protein (HABP). This hyaluronidase specifically degrades HA and therefore served as a control to demonstrate the specificity of the method. The sections were examined and documented by use of a Zeiss Axiophot photomicroscope (Germany).

Isolation and biotin-labelling of the HABP

The isolation and biotin-labelling of the HABP has been described in detail elsewhere (20). Briefly, a mixture of proteins, with affinity for the HA-binding region of the chondroitin sulphate proteoglycan and the link proteins was isolated from bovine nasal cartilage and purified by affinity chromatography. The purified HA-binding region was then linked to biotin and stored at -20°C until used.

Immunohistochemistry of CD44

CD44 was visualized in sections 6-µm thick. Sections were fixed in ice-cold 100% acetone for 10 min. Endogenous peroxidase

Table II. Skin disease in psoriatic arthritis (PsA), earlier or clinical picture at investigation

Type of psoriasis	Patients
No present sign of psoriasis skin lesions, <i>n</i>	1
Plaque, <i>n</i>	43
Guttate, <i>n</i>	6
Pustular generalized, <i>n</i>	1
Palmoplantar pustulosis, <i>n</i>	3
With nail involvement, <i>n</i>	30
Mean total body skin involvement, %	6.3

activity was blocked by incubation in Peroxidase 1 (PX968 Biocare Medical, Newport Beach, USA) for 5 min. The sections were then allowed to react with Background Sniper (BS966 Biocare Medical, USA) for 10 min to reduce non-specific staining. Thereafter they were incubated with primary antibody CD44 mouse monoclonal IgG2a diluted 1/2000 (GTX 26124, GeneTex Inc., Irvine, USA) for 90 min. Mach 3 mouse AP polymer Detection (Mouse Probe MP530 and Mouse AP-Polymer MAP532, Biocare Medical, USA) was used as a secondary step. The peroxidase reaction was developed with Vulcan Fast Red Chromagen (FR 804 Biocare Medical, USA). Rinsing between the incubations was carried out in 0.1% Tween20/PBS for 5 min. The sections were counterstained with Mayer's haematoxylin. Mouse IgG2A was used as negative control, diluted 1/2000 (LS19430-8, Dako Cytomation, Glostrup, Denmark).

Immunohistochemistry of anti-hMMP-3

Anti-hMMP-3 was visualized in 6- μ m thick sections. Sections were fixed in ice-cold 4% paraformaldehyde/PBS for 10 min. Endogenous peroxidase activity was blocked by incubation in Peroxidase 1 (PX968 Biocare Medical, USA) for 5 min. The sections were then allowed to react with Background Sniper (BS966 Biocare Medical, Minneapolis, USA) for 10 min to reduce non-specific staining. Thereafter they were incubated with primary antibody anti-hMMP-3 Goat IgG, dilution; 1/50 (AF 513 R&D, USA) for 90 min. Biotinylated anti-goat IgG, dilution; 1/200 (BA 5000, Vector Laboratories, Burlingame, USA) was used as a secondary antibody. Finally, the sections were incubated in a third step with an avidin-biotin complex; dilution 1/50 (AK 5000, Vector Laboratories). The peroxidase reaction was developed with Vulcan Fast Red Chromagen (FR804 Biocare Medical, USA). Rinsing between the incubations was carried out in 0.1% Tween20/PBS for 5 min. The sections were counterstained with Mayer's haematoxylin. Controls, with the primary antibody omitted were negative.

Immunohistochemistry of anti-hMMP-9

Anti-hMMP-3 was visualized in 6- μ m thick sections, fixed in ice-cold 4% paraformaldehyde/PBS for 10 min. Endogenous peroxidase activity was blocked by incubation in Peroxidase 1 (PX968 Biocare Medical, USA) for 5 min. The sections were then allowed to react with Background Sniper (BS966 Biocare Medical, USA) for 10 min to reduce non-specific staining. Thereafter they were incubated with primary antibody anti-hMMP-9 mouse monoclonal IgG1 diluted 1/40 (MAB936, R&D, USA) for 90 min. Mach 3 Mouse AP polymer Detection (MP530 Mouse Probe and MAP532 Mouse AP-Polymer, Biocare Medical, USA) was used as a secondary step. The peroxidase reaction was developed with Vulcan Fast Red Chromagen (FR804 Biocare Medical, USA). Rinsing between the incubations was carried out in 0.1% Tween20/PBS for 5 min. The sections were counterstained with Mayer's haematoxylin. Mouse IgG1 was used as negative control diluted 1/40 (MCA928, Serotec, Oxford, UK).

All evaluations were performed in a descriptive manner on "blinded" slides by the 2 of the authors working separately. On comparing results there was a good correlation between the 2 examiners.

Quantitative analysis of circulating HA

Serum HA measurements were performed with a hyaluronic acid (HA) test kit (Corgenix, Westminster, USA) (21, 22). The principle of this method is a sandwich technique involving the HA-binding region (HABP) of bovine nasal cartilage proteoglycan coated on microwells. Diluted serum was incubated in

the HABP coated microwells. After removal of unbound serum molecules by washing, HABP conjugated with horseradish peroxidase solution was added to form complexes with bound HA. After further washings tetramethylbenzidine and hydrogen peroxidase was added for colour reaction, measured at 450 nm using a spectrophotometer. Handled reference solutions were used for determinations in a reference curve.

RESULTS

Serum hyaluronan

The mean serum HA concentration for the patient material ($n=48$) was 70.4 ± 90.2 μ g/l. Serum HA was significantly correlated with age ($r=0.494$, $p=0.0004$) and with patient's own estimated total disease activity measured with a visual analogue scale (VAS) ($r=-0.593$, $p=0.02$), but not with blood erythrocyte sedimentation rate, c-reactive protein, number of swollen or tender joints, or with patient's estimate of morning stiffness. There was no significant correlation of HA with inflammation or disease activity in the subgroups. Neither was there any correlation between the extent of skin lesions and the serum levels.

The HA distribution in lesional and non-lesional skin of the patients is presented in Table SI (available from: <http://www.medicaljournals.se/acta/content/?doi=10.2340/00015555-1286>). In lesional skin, 64% ($n=33$) of the 51 patients, HA staining intensity was stronger in epidermis compared with dermis and 51% ($n=17$) of these were patients with polyarthritis (PA). The BM zone in patients with PsA was devoid of HA in 43% ($n=22$) and 59% ($n=13$) of these had PA. In non-lesional skin from the same patients, 22% ($n=11$) HA staining intensity was also stronger in epidermis and 63% ($n=7$) had PA. The BM zone of non-lesional skin was devoid of HA in 22% ($n=11$) and 54% ($n=6$) had PA.

In the further analysis of the biopsies with localization of CD44, MMP3 and MMP9, PsA patients were classified into two groups; mono-oligoarticular and polyarticular. The polyarticular group included patients with distal joint arthritis and one patient with arthritis mutilans. The patients with enthesitis were grouped according to number of joint involvement.

Normal skin from a healthy control (Fig. 1 A–D)

The most intense HA-staining was observed in the papillary dermis. In this region HA was present in a dense homogenous layer just beneath the BM zone. In the reticular dermis HA staining was distributed in an irregular mesh-like pattern. HA staining was also seen between the keratinocytes in the granular and spinous layer of the epidermis.

Staining for CD44 was seen in all layers of the epidermis, and in dermis the staining pattern resembled that of HA, but was especially strong around the blood vessels.

Rare staining of the MMPs was seen only in the dermis, with a few patches around blood vessels. No staining was observed in epidermis.

Psoriatic skin from a methotrexate-treated patient with polyarthritic PsA (Fig. 1 E–H)

The histological appearance showed gross pathology, including the HA staining pattern, with the BM zone being totally devoid of HA staining and a redistribution of HA from the dermis to the epidermis.

Strong CD44 staining was observed in the stratum basale and spinosum of the thickened epidermis and in the papillary dermis. In the reticular dermis the staining was found mainly around blood vessels.

Diffuse staining for MMP3 was seen in the epidermis, including patches in the stratum corneum. In the dermis faint MMP3 staining was seen around clusters of inflammatory cells. MMP9 was almost absent in the epidermis. Some strongly stained MMP9 patches were observed in the upper parts of the dermis.

Psoriatic skin from a non-treated patient with polyarthritic PsA (Fig. S1 I–L (available from: <http://www.medicaljournals.se/acta/content/?doi=10.2340/00015555-1286>))

Intense HA staining was observed in all layers of the epidermis. In the dermis almost no staining was seen

beneath the disintegrated BM zone.

Sparse CD44 staining was seen in the lower layers of the epidermis, mainly in the top of the papillae. Diffuse, weak staining was observed around vessels in the dermis.

Diffuse MMP3 staining was seen in the epidermis including the stratum corneum. In contrast to the MTX-treated patients, less staining was seen in the dermis. MMP9 stained in the papillae and around blood vessels in the dermis. A few patches of staining were observed in the stratum spinosum of the epidermis.

Except for CD44 the staining pattern of HA, MMP3 and MMP9 did not show any significant difference between MTX-treated and non-treated patients.

Non-involved skin from an oligo-arthritic patient with PsA without treatment (Fig. 1 M–P)

Despite being macroscopically normal, the skin biopsies showed gross pathology consistent with psoriatic lesions. Strong homogenous HA staining was seen in all layers of the epidermis. The BM zone was devoid of staining; however, there was strong staining in the papillary and reticular layers of the dermis.

CD44 staining followed the HA staining pattern, both in the epidermis and in the dermis, with almost no staining in the BM zone.

Staining for MMP3 and MMP9 showed a patchy staining pattern in some papillae and around the vessels in the der-

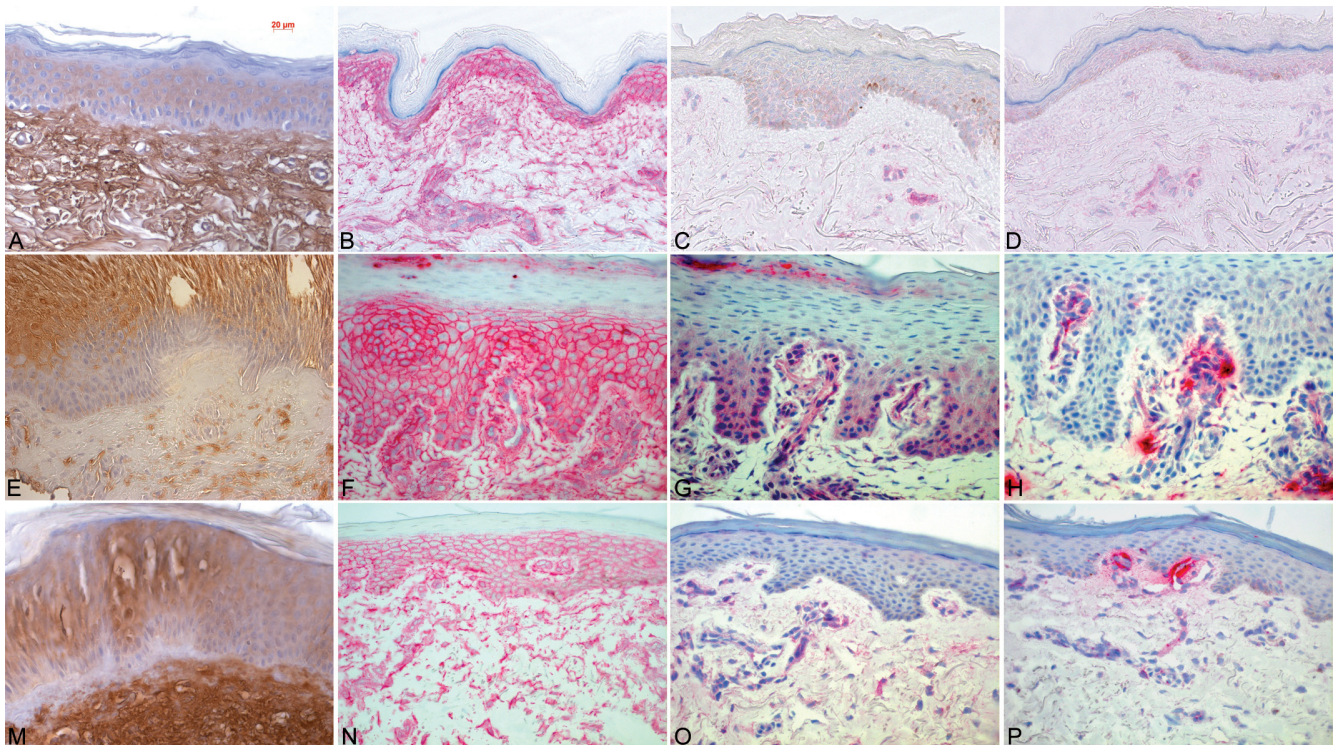


Fig. 1. (A–D) Normal skin from a healthy control: (A) hyaluronan ($\times 40$), (B) CD44 ($\times 40$), (C) metalloproteinase 3 (MMP3) ($\times 40$) and (D) metalloproteinase 9 (MMP9) ($\times 40$). (E–H) Psoriatic skin from a methotrexate-treated patient with polyarthritic psoriatic arthritis (PsA): (E) hyaluronan ($\times 40$), (F) CD44 ($\times 40$), (G) MMP3 ($\times 40$) and (H) MMP9 ($\times 40$). (M–P) Non-involved skin from an oligo-arthritic patient with PsA without treatment: (M) hyaluronan ($\times 40$), (N) CD44 ($\times 40$), (O) MMP3 ($\times 40$) and (P) MMP9 ($\times 40$).

mis. No staining of the MMPs was seen in the epidermis.

Psoriatic-involved skin from an oligo-arthritic patient with PsA without treatment (Fig. S1 Q–T (available from: <http://www.medicaljournals.se/acta/content/?doi=10.2340/00015555-1286>))

No difference was observed in HA staining pattern between non-involved and involved skin. Strong homogenous staining was seen in the epidermal layers, except the stratum corneum. Patchy staining was seen in the dermis, except the BM zone, which was devoid of HA.

Staining for CD44 showed a homogenous pattern in the epidermis, except for the stratum corneum. Patchy irregular staining was observed in the papillary and reticular layers of the dermis, including around blood vessels.

Faint staining for both MMP3 and MMP9 was observed in the epidermis and a few patches were seen in the upper parts of the dermis, mainly around vessels.

DISCUSSION

In the present study, the skin histology in PsA concerning the distribution of the matrix component HA, its main receptor CD44 and the metalloproteinases MMP3 and MMP9 was investigated. In addition, the serum concentration of HA was measured. The main observation was redistribution of HA in both involved and non-involved psoriatic skin. Another observation was an epidermal imbalance between HA and CD44 in untreated patients with polyarticular disease. The structurally and functionally important BM zone was found to be disintegrated and devoid of HA irrespective of type of articular involvement, treatment or skin affection. The pathology of the dermal ground substance in psoriasis was described in 1978, when Del Forno et al. (3) reported changes in the ground substance due to an assumed alteration of HA. Subsequent studies have supported this finding (5, 8).

In this study the mean serum HA level in the patients with PsA confirmed the result of earlier studies and showed an increased mean value in the patient group compared with a healthy reference material (17, 18). Our results also confirmed that the serum HA levels correlate with age (23), but not with inflammatory activity in joints. Earlier reports indicating that serum HA levels relate to morning stiffness (17) and to skin inflammation given as Psoriasis Area and Severity Index (PASI) score (18), could not be confirmed in this report. As HA is rapidly eliminated from the circulation via the liver, only heavily increased endogenous production of the glycosaminoglycan caused by inflammatory activity in skin or joints can be mirrored by high levels in serum (24).

An important observation was the pathological appearance

of the macroscopically normal, non-involved skin. A deranged BM zone was found in both lesional and non-lesional skin biopsies, an important structure for the maintenance of normal healthy skin. The degrading enzymes MMP3 and MMP9 were present, but unevenly distributed in all groups of PsA. Interestingly, in highly inflammatory biopsies (Fig. 1 E–H) the proteases were found mainly in the lower part of the epidermis and in the papillae associated with the BM zone. The balance between synthesis and degradation of extracellular matrix components is of great importance for the formation and maintenance of the BM. HA in sites of inflammation can be depolymerized to low-molecular weight (LMW) fragments via oxygen radicals, enzymatic degradation and cytokine activity (25). A limitation of this study is the lack of MW analysis of HA in the skin specimens. In spite of this the increased staining of the MMPs in the PsA biopsies makes it plausible to assume that HA is degraded at the site of inflammation. These breakdown products of HA have the ability to induce a diverse array of inflammatory mediators, e.g. MMPs (26), which have cell biological effects and drive the inflammatory process. The relatively high cell biological activity of MMPs, such as MMP3 and MMP9 compared with tissue inhibitors of metalloproteinases (TIMPs) is a reason for defect non-functional reconstruction of the BM (25). In an *in vitro* study of a skin-equivalent model MMPs were involved in the degradation of the epidermal BM and MMP inhibitors exerted a protective effect against BM damage (27, 28). Moreover, in fibroblast cultures HA seems to increase both the expression and the activation of latent MMPs (29).

In the non-treated patients with polyarticular PsA the CD44 staining was faint in spite of strong HA staining. This was not apparent in the MTX-treated patients. We can only speculate about the significance of this finding, but an earlier study by Teder et al. (9) has shown the importance of a balance between HA and CD44 in restoring inflammation in the lungs.

In conclusion, our findings in PsA indicate a pathological distribution and possible disturbed interplay between HA and its binding protein CD44, and an obvious increase and displacement of the MMPs. It is possible that a low molecular weight HA may be driving the inflammatory process in epidermis in both PsA and psoriasis. Further studies are needed to analyse the molecular weight of HA in diseased skin and the distribution of the protective TIMPs.

REFERENCES

1. Reed RK, Lilja K, Laurent TC. Hyaluronan in the rat with special reference to the skin. *Acta Physiol Scand* 1988; 134: 405–411.
2. Fraser JR, Laurent TC, Laurent UB. Hyaluronan in nature, distribution, function and turnover. *J Intern Med* 1997; 242: 27–33.

3. Del Forno C, Cerimele D, Serri F. Histochemistry of the dermal ground substance of initial psoriatic lesions. *Arch Dermatol Res* 1978; 262: 311–321.
4. Lundin Å, Engström-Laurent A, Michaëlsson G, Tengblad A. High levels of hyaluronate in suction blister fluid from active psoriatic lesions. *Br J Dermatol* 1987; 116: 335–340.
5. Tammi R, Ripellino JA, Margolis RU, Tammi M. Localization of epidermal hyaluronic acid using the hyaluronate binding region of cartilage proteoglycan as a specific probe. *J Invest Dermatol* 1988; 90: 412–414.
6. Wells A, Lundin Å, Michaëlsson G. Histochemical localization of hyaluronan in psoriasis, allergic contact dermatitis and normal skin. *Acta Derm Venerol* 1991; 71: 232–238.
7. Juhlin L. Hyaluronan in skin. *J Intern Med* 1997; 242: 61–66.
8. Tammi R, Paukkonen K, Wang C, Horsmanheimo M, Tammi M. Hyaluronan and CD44 in psoriatic skin. Intense staining for hyaluronan on dermal capillary loops and reduced expression of CD44 and hyaluronan in keratinocyte-leukocyte interface. *Arch Dermatol Res* 1994; 286: 21–29.
9. Teder P, Vandivier RW, Jiang D, Liang J, Cohn L, Puré E, Henson PM, Noble PW. Resolution of lung inflammation by CD44. *Science* 2002; 296: 155–158.
10. Itano N, Sawai T, Yoshida M, Lenas P, Yamada Y, Imagawa M, et al. Three isoforms of mammalian hyaluronan synthases have distinct enzymatic properties. *J Biol Chem* 1999; 274: 25085–25092.
11. Li L, Asteriou T, Bernert B, Heldin C-H, Heldin E. Growth factor regulation of hyaluronan synthesis and degradation in human dermal fibroblasts; importance for hyaluronan for the mitogenic response of PDGF-BB. *Biochem J* 2007; 404: 327–336.
12. Isnard N, Legeais J-M, Renard G, Robert L. Effect of hyaluronan on MMP expression and activation. *Cell Biol Int* 2001; 25: 735–739.
13. Bertheim U, Hofer PA, Engström-Laurent A, Hellström S. The stromal reaction in basal cell carcinomas. A prerequisite for tumor progression and treatment. *Br J Plast Surg* 2004; 57: 429–439.
14. Lundin Å, Engström-Laurent A, Hällgren R, Michaëlsson G. Circulating hyaluronate in psoriasis. *Br J Dermatol* 1985; 112: 663–671.
15. Taylor W, Gladman D, Helliwell P, Marchesoni A, Mease P, Mielants H, and the CASPAR Study Group. Classification criteria for psoriatic arthritis: development of new criteria for a large international study. *Arthritis Rheum* 2006; 54: 2665–2673.
16. Elkayam O, Ophir J, Yaron M, Caspi D. Psoriatic arthritis: interrelationships between skin and joint manifestations related to onset and distribution. *Clin Rheumatol* 2000; 19: 301–305.
17. Elkayam O, Yaron I, Shirazi I, Yaron M, Caspi D. Serum levels of hyaluronic acid in patients with psoriatic arthritis. *Clin Rheumatol* 2000; 19: 455–457.
18. Partsch G, Leeb B, Stancikova M, Raffayova H, Eberl G, Hitzelhammer H. Low serum hyaluronan in psoriatic arthritis patients in comparison to rheumatoid arthritis patients. *Clin Exp Rheumatol* 1996; 14: 381–386.
19. Hellström S, Tengblad A, Hedlund U, Johansson C, Axelsson E. An improved technique for hyaluronan histochemistry using microwave irradiation. *Histochem J* 1990; 22: 677–682.
20. Tengblad A. Affinity chromatography on immobilized hyaluronate binding protein from cartilage. *Biochem Biophys Acta* 1979; 578: 281–289.
21. Chichibu K, Matsuura T, Shichijo S, Yokoyama MM. Assay of serum hyaluronic acid in clinical application. *Clin Chim Acta* 1989; 181: 317–324.
22. Lindqvist U, Chichibu K, Delpech B, Goldberg RL, Knudson W, Poole AR, et al. Seven different assays of hyaluronan compared for clinical utility. *Clin Chem* 1992; 38: 127–132.
23. Lindqvist U, Laurent TC. Serum hyaluronan and amino-terminal propeptide of type III procollagen. Variation with age. *Scand J Clin Lab Invest* 1992; 52: 613–621.
24. Torsteinsdottir I, Groth T, Lindqvist U. Production and elimination of hyaluronan in rheumatoid arthritis patients: estimation with a loading test. *Semin Arthritis Rheum* 1999; 28: 268–279.
25. Powell J, Horton M. Threat matrix: low-molecular-weight hyaluronan (HA) as a danger signal. *Immunol Res* 2005; 31: 207–218.
26. Fieber C, Baumann P, Vallon R, Termeer C, Simon JC, Hofmann M, et al. Hyaluronan-oligosaccharides-induced transcription of metalloproteases. *J Cell Sci* 2004; 117: 359–367.
27. Amano S, Akutsu N, Matsunaga Y, Kadoya K, Nishiyama T, Champlaud M-F, et al. Importance of balance between extracellular matrix synthesis and degradation in basement membrane formation. *Exp Cell Res* 2001; 271: 249–262.
28. Amano S, Ogura Y, Akutsu N, Matsunaga Y, Kadoya K, Adachi E, et al. Protective effect of matrix metalloproteinase inhibitors against epidermal basement membrane damage: skin equivalents partially mimic photoageing process. *Br J Dermatol* 2005; 153: 37–46.
29. Maytin EV, Chung HH, Seetharaman VM. Hyaluronan participates in the epidermal response to disruption of the permeability barrier in vivo. *Am J Pathol* 2004; 165: 1331–1341.