

Disseminated Cutaneous Glomangiomas in an Adolescent Boy

Alena Borovaya^{1,2}, Christian Kunte¹, Michael J. Flaig¹, Kerstin Albrecht¹, Ilana Goldscheider¹, Hans Christian Korting¹, Thomas Ruzicka¹ and Miklós Sárdy^{1*}

¹Department of Dermatology and Allergology, Ludwig-Maximilian University, Frauenlobstr. 9–11, DE-80337 Munich, Germany, ²Department of Dermatology and Venerology, I.M. Sechenov First Moscow State Medical University, Moscow, Russia. *E-mail: miklos.sardy@med.uni-muenchen.de
Accepted September 28, 2011.

Glomus tumours are distinctive neoplasms composed of cells resembling the modified smooth muscle cells of the normal glomus body (a specialized form of arteriovenous anastomosis involved in thermal and baroregulation) (1, 2). Vascular tumours with glomus cell morphology occur in two unrelated forms, the glomus tumour *per se* and the glomuvenous malformation (GVM, OMIM 138000) or glomangioma (3, 4). Clinically, glomangiomas tend to resemble haemangiomas. Differentiation of these entities is important due to their divergent treatment modalities. We report here a case in which multiple glomangiomas were clinically diagnosed as haemangiomas, but histological examination rendered the diagnosis more precisely. The clinical characteristics, differential diagnosis and treatment options of this rare entity are reviewed.

CASE REPORT

A 15-year-old boy presented for evaluation and second opinion with multiple bluish cutaneous congenital tumours. The nodules had been present at birth and had increased in size since then in proportion to the body. No other family members had similar lesions. The patient was otherwise healthy. He reported localized pain upon pressure, hence laser treatment of the “haemangiomas” had been planned elsewhere.

On physical examination, a total of 31 moveable, barely compressible, bluish dermal tumours were found on the back, buttocks, right thigh and left arm (Fig. 1). Histopathological examination showed a glomus tumour rich in enlarged vessels (Fig. 2). These findings were consistent with multiple glomangiomas. The largest and

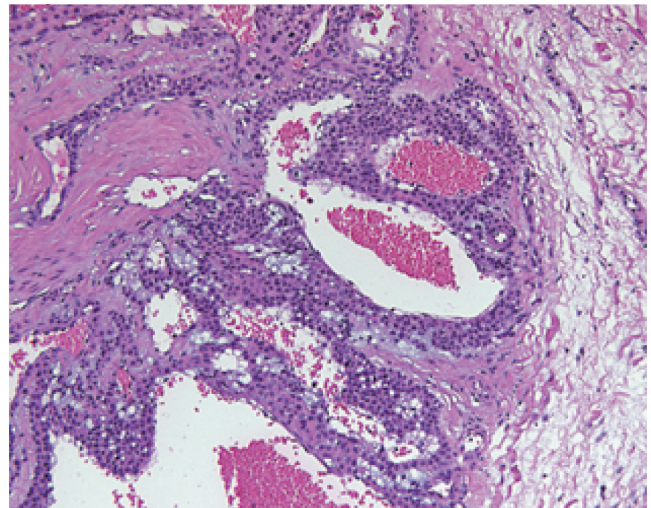


Fig. 2. Histological appearance. Irregular, large, ectatic vascular channels formed by several layers of inconspicuous glomus cells, interspersed with mucinous material. H&E staining, original magnification $\times 200$.

most painful nodules on the upper back, the lumbar area, and the right thigh were removed by excision (Fig. 3).

DISCUSSION

Tumours with glomus cell morphology are usually benign, very rarely malignant, either solitary or multiple, congenital or acquired (1, 2). Two unrelated forms can be distinguished; the glomus tumour *per se* and the GVM or glomangioma (3, 4). GVMs are of genetic origin (loss-of-function mutations in glomulin were reported to be causative (3)) and present as disseminated cutaneous glomangiomas commonly in childhood,

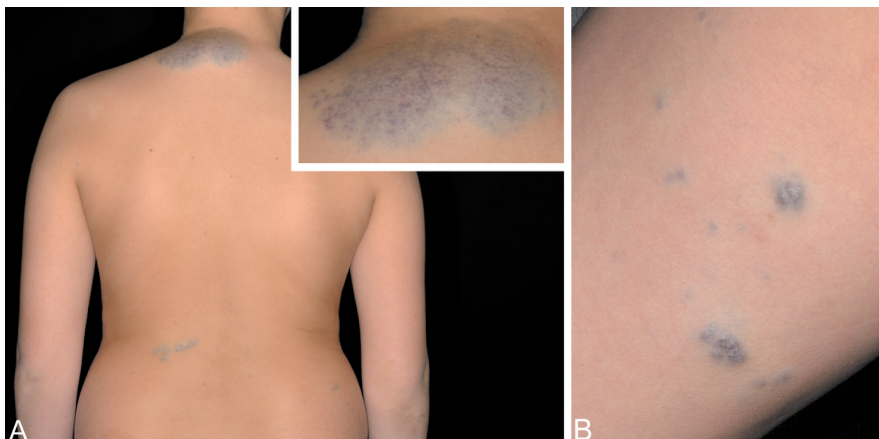

Fig. 1. Glomangioma. Blue-hued, multiple, irregularly shaped, in part confluent, elevated subcutaneous tumours of 0.5–9.5 cm diameter on (A) the back and (B) the right thigh. Inset: large tumour on the upper back.

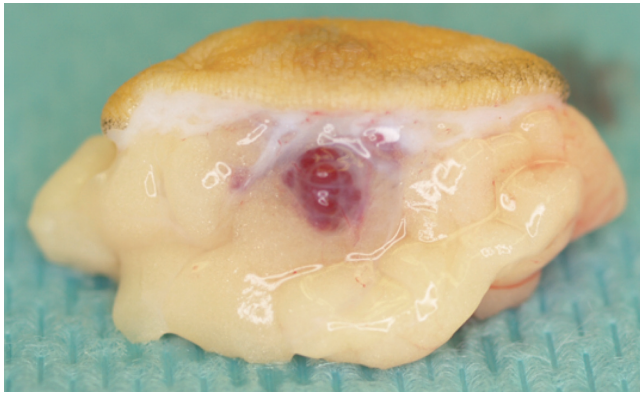


Fig. 3. Glomus tumour in the excised tissue.

thus much earlier than their histological simulants, the glomus tumours (1, 4). GVM can occur sporadically, but the majority of cases are familial with autosomal dominant inheritance, in which case genetic counselling is essential. Despite a good understanding of the pathology of glomus tumours and the consistency of clinical presentation of glomus tumours in the skin, only 18.2% of referring physicians could make the correct diagnosis according to a study by Anakwenze et al. (1).

The differential diagnosis of glomus tumour includes haemangioma, blue rubber bleb naevus syndrome, pyogenic granuloma, spiradenoma, angioliipoma, leiomyoma, hemangiopericytoma, and cutaneomucosal venous malformation (5). Unlike GVM, blue rubber bleb naevus syndrome is usually associated with anaemia and/or occult rectal bleeding. Clinical criteria favouring GVMs (glomangiomas) over venous malformations are: raised, cobblestone-like appearance, incompressibility, tenderness on palpation, lack of pain with hormonal changes (menstruation, pregnancy, and puberty), and the absence of phleboliths (4, 6). Pyogenic granuloma grows rapidly, tends to bleed, and usually presents as a fungus-like structure with round, hyperkeratotic margins. Other benign tumours similar to glomangiomas are usually acquired later in life.

A variety of treatment modalities have been employed for multiple glomangiomas, including excision, sclerotherapy with sodium tetradecyl sulphate or hypertonic

NaCl solution, carbon dioxide, argon, pulsed dye or Nd:YAG laser application; others prefer only watchful follow-up of asymptomatic lesions (7, 8). GVM does not usually involute over time, and patients request treatment for symptomatic relief and/or for cosmetic reasons. Local recurrence following inadequate (incomplete) excision is very common, especially in those cases with deep, infiltrative expansion (9). Excision of multiple glomangiomas is not always feasible and most authors recommend only excision of symptomatic lesions.

In conclusion, in order to avoid improper treatment, an early diagnostic biopsy is mandatory in patients who present with multiple, non-involuting, subcutaneous, bluish-purple or flesh-coloured tumours involving one or multiple areas of the body.

REFERENCES

1. Anakwenze OA, Parker WL, Schiefer TK, Inwards CY, Spinner RJ, Amadio PC. Clinical features of multiple glomus tumors. *Dermatol Surg* 2008; 34: 884–890.
2. Hayashi M, Kitagawa Y, Kim Y, Tanaka Y, Fujii N, Ito H, et al. Malignant glomus tumors arising among multiple glomus tumors. *J Orthop Sci* 2008; 13: 472–475.
3. Brouillard P, Boon LM, Mulliken JB, Enjolras O, Ghassibé M, Warman ML, et al. Mutations in a novel factor, glomulin, are responsible for glomuvenous malformations (“glomangiomas”). *Am J Hum Genet* 2002; 70: 866–874.
4. Boon LM, Mulliken JB, Enjolras O, Vakkula M. Glomuvenous malformation (glomangioma) and venous malformation. *Arch Dermatol* 2004; 140: 971–976.
5. Wolff HH, Korting HC, Vigl E. Multiple Glomustumoren. *Hautarzt* 1981; 32: 354–358.
6. Mounayer C, Wassef M, Enjolras O, Boukobza M, Mulliken JB. Facial “glomangiomas”: large facial venous malformations with glomus cells. *J Am Acad Dermatol* 2001; 45: 239–245.
7. D’Acri AM, Ramos-e-Silva M, Basilio-de-Oliveira C, Cerqueira A, Monteiro D, Pretti G, et al. Multiple glomus tumors: recognition and diagnosis. *SkinMed* 2002; 1: 94–98.
8. Parsons ME, Russo G, Fucich L, Millikan LE, Kim R. Multiple glomus tumors. *Int J Dermatol* 1997; 36: 894–900.
9. Skelton HG, Smith KJ. Infiltrative glomus tumor arising from a benign glomus tumor: a distinctive immunohistochemical pattern in the infiltrative component. *Am J Dermatopathol* 1999; 21: 562–566.