

CLINICAL REPORT

Eccrine Poromatosis Associated with Polychemotherapy

Kazuyasu FUJII*, Seiko AOCHI*, Chinatsu TAKESHIMA, Masaki OHTSUKA, Toshihisa HAMADA, Kenji ASAGOE, Yumi AOYAMA, Shin MORIZANE and Keiji IWATSUKI

Department of Dermatology, Okayama University Graduate School of Medicine, Dentistry and Pharmaceutical Sciences, Okayama, Japan

*Both authors contributed equally to this work.

Eccrine poroma frequently occurs as a solitary tumour, and only a few reports have described the occurrence of multiple lesions. Multiple eccrine poromas, or eccrine poromatosis, may occur in patients who have undergone radiotherapy and/or polychemotherapy. We report here four cases of multiple eccrine poromas in patients who were either undergoing, or had undergone, intensive chemotherapy (from 6 months to 16 years prior to onset). Three patients had non-Hodgkin's lymphoma and one had malignant fibrous histiocytosis. The number of lesions varied from 3 to >20 in each patient, and all the lesions occurred on non-irradiated skin. The histopathological features were consistent with those of eccrine poroma, Pinkus type. In addition to radiation therapy, intensive chemotherapy may play a role in the pathogenesis of multiple eccrine poromas even many years after treatment. Key words: multiple; eccrine poroma; poromatosis; chemotherapy.

(Accepted September 28, 2011.)

Acta Derm Venereol 2012; 92: 687–690.

Keiji Iwatsuki, Department of Dermatology, Okayama University Graduate School of Medicine, Dentistry and Pharmaceutical Sciences, 2-5-1 Shikata-cho, Kita-ku, Okayama 700-8558, Japan. E-mail: keijiwa@cc.okayama-u.ac.jp

Eccrine poroma, first described by Pinkus et al. (1) in 1956, preferentially occurs as a solitary tumour in areas rich with eccrine sweat glands, including the soles, sides of the feet, hands and fingers. They may also develop on the neck, chest, nose and eyelids. Poromas have widely been considered to arise from eccrine sweat ducts, but apocrine origin has also been discussed (2). Previous reports have described the association of eccrine poroma with trauma (3, 4), pregnancy (5), radiation therapy (6–8) and chemotherapy (9), although its pathogenesis remains unclear. Unusual types of multiple eccrine poromas have been reported in a patient with hidrotic ectodermal dysplasia (10) and a patient with linear eccrine poromas (11). Apart from the unusual types, multiple lesions, clinically and histologically indistinguishable from common types of poromas, have been reported in patients who have undergone radiotherapy or chemotherapy (6–9). We report here multiple eccrine poromas, or eccrine poromatosis,

arising in four patients who were either undergoing or had undergone intensive chemotherapy 6 months to 16 years prior to onset.

CASE REPORTS

Case 1. A 66-year-old Japanese woman presented at our clinic in 2007 with skin papules and nodules of 5 years' duration. She had a history of chronic lymphocytic leukaemia (CLL) treated with cyclophosphamide and other chemotherapeutic regimens in 1986. In 1990, follicular lymphoma of B-cell type occurred in the left parotid gland, mediastinum and para-aortic lymph nodes, which was treated with various chemotherapeutic regimens, including: (i) epirubicin and vincristine, (ii) mitoxantrone, cyclophosphamide, vincristine, methotrexate, and prednisolone, at least 18 times, (iii) etoposide, cisplatin, and prednisolone, and (iv) unidentified regimens. In 1996, surgical resection, followed by radiation therapy of 30 Gy, was performed for a relapse on the right eyelid. In 2002, 16 years after the onset of the primary CLL, the patient noticed multiple skin-coloured or reddish papules and nodules on the extremities and trunk. Her family history was not contributory.

On examination, slightly reddish papules and nodules were observed on both thighs, the left forearm, hip and lower abdomen, excluding the soles and palms (Fig. 1a). The lesions varied in size from 1 to 7 mm, and some were slightly pedunculated. At least 19 lesions were identified on examination. Dermoscopic findings showed a cobblestone pattern with comma-like or hairpin vessels (Fig. 1b). Biopsy specimens of nodules from the left thigh, forearm, and lower abdomen revealed essentially the same histological findings: polypoid proliferation of epithelial strands composed of uniform basaloid cells that radiate from the basal layer of the epidermis into the dermis. On the deep aspect of the tumours, poroid cells proliferated, surrounding the pre-existing eccrine sweat duct (Fig. 1c). The patient was diagnosed as having multiple eccrine poromas, or eccrine poromatosis. Neither internal tumours nor other hamartomas were present.

Case 2. A 62-year-old man visited our orthopaedic department in April 2000 because of a tumour on the posterior surface of his right thigh. The lesion was diagnosed by histopathological examination as malignant fibrous histiocytoma. The patient underwent a wide resection of the right thigh including the tumour, and a replacement operation of the right femoral head. Before and after surgery, he was treated with four courses of combination chemotherapy using doxorubicin hydrochloride (135 mg 4 times) and ifosfamide (20 g three times and 17.5 g once). Radiotherapy (total dose 63 Gy) was administered to the right leg in July 2000. No adverse skin reactions, such as generalized dermatitis or anhidrotic conditions, were noted during the treatments.

Forty-one months later, the patient was referred to our clinic because of a reddish nodule, 4 mm in diameter, on the right heel. Excisional biopsy revealed an exophytic nodule compo-

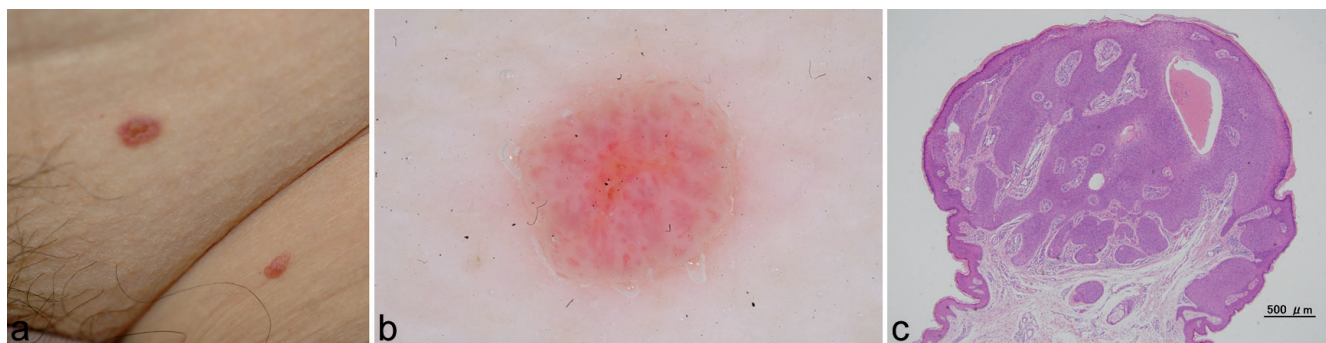


Fig. 1. Clinical appearance of case 1. (a) Slightly reddish papules in the left inguinal region. (b) Dermoscopic findings of the tumour of the left inguinal lesion. (c) Histological findings of the tumour of the left thigh. Tumour cells form broad columns extending downward from the normal epidermis. Hematoxylin & eosin $\times 20$.

sed of irregularly proliferating, mesh-like epithelial structures made up of poroid cells, which was histologically consistent with eccrine poroma, Pinkus type. Seven years after excision of this lesion and chemotherapy, the patient noticed two new reddish nodules, 7 and 5 mm in diameter on the lateral surface of left lower leg (Fig. 2a, b) and the lateral border of the right sole, respectively. These tumours gradually increased in size and occasionally bled. Both nodules were surgically removed. With histopathological features similar to the previous lesion, these resected lesions showed proliferation of epithelial, cord-like strands and broad anastomosing bands composed of poroid cells, which extended downward into the dermis (Fig. 2c). As of December 2010, the patient has had three eccrine poromas on non-irradiated skin in the 7 years following chemotherapy.

Case 3. A 59-year-old Japanese man with hypertension and hyperthyroidism presented with a verrucous nodule on the right palm. The patient had undergone surgical removal of a malignant B-cell lymphoma in the brain 6 months earlier, followed by 5 courses of combination chemotherapy using methotrexate (5,800 mg), cyclophosphamide (1,200 mg), adriacin (80 mg),

vincristine sulphate (2.2 mg), and prednisolone (360 mg) (M-CHOP), and two courses of rituximab once a week for 4 weeks. Because of the recurrence of lymphoma, two additional courses of M-CHOP and rituximab treatments were administered. During the last course of chemotherapy, the patient visited our clinic because he developed a pedunculated nodule, 7 mm in diameter, on the right palm (Fig. 3a). The lesion was surgically removed and diagnosed histologically as eccrine poroma.

Eighteen months later, the patient visited our clinic again because of new verrucous nodules on the hand and soles. On examination, 3 verrucous or pedunculated nodules, range 3–15 mm in diameter, were observed on the side of his left hand (Fig. 3b), and the sole and heel of the left foot. The verrucous nodule on the left heel was removed surgically and histology revealed a keratotic nodule composed of cord-like epithelial structures containing poroid cells adjacent to the overlying epidermis. The nodule was diagnosed histologically as eccrine poroma. Because the remaining two lesions gradually increased in size, both were resected and found to be histologically consistent with eccrine poroma (Fig. 3c).

Case 4. A 72-year-old Japanese man visited us in 2010 because of a 3-year history of enlarging nodules on the back and right thigh. In 1996, abdominal ultrasound and computed tomography showed a mass and multiple enlarged lymph nodes. Biopsy of a left inguinal lymph node revealed diffuse large B-cell lymphoma. The patient underwent 7 courses of combination chemotherapy with cyclophosphamide (1,400 mg), adriacin (90 mg), vincristine sulphate (2 mg) and prednisolone (110 mg) (CHOP), and 12 courses of oral etoposide (75 mg daily for 2 weeks) once a month. In 1998, at the completion of this chemotherapy, the disease was in complete clinical remission. No adverse skin reactions were noted during the course of chemotherapy.

Ten years later, in 2006, the patient noticed 3 reddish nodules on his back and right thigh and subsequently small multiple reddish papules on the trunk and extremities. In 2010, the patient visited our clinic because of 3 pedunculated nodules on the back and right thigh. On examination, verrucous nodules, ranging from 10 to 15 mm, were observed on the back, right thigh, and right knee (Fig. 4a, b). In addition, numerous papules, ranging from 2 to 10 mm in diameter, were observed on the trunk and extremities. The pedunculated nodules were removed surgically and diagnosed histopathologically as eccrine poroma (Fig. 4c, d).

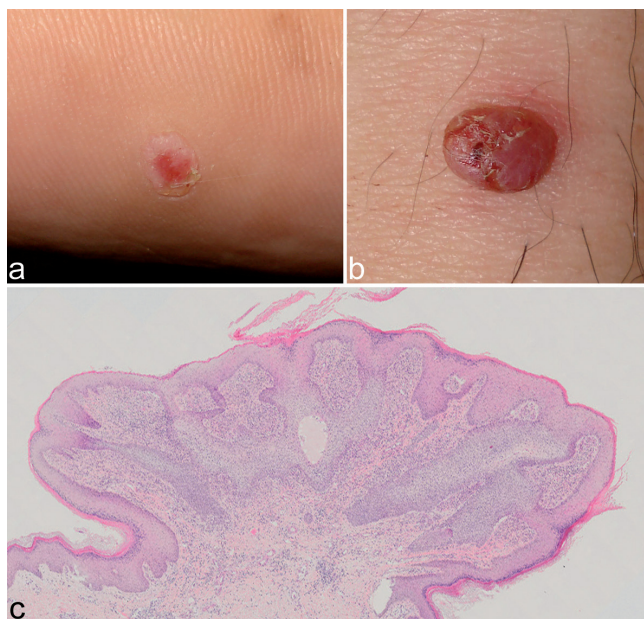


Fig. 2. Clinical appearance of case 2. (a) Verrucous papules on the right sole and (b) a pedunculated nodule on the left lower leg. (c) Biopsy of the nodule of the left lower leg shows broad nests of pale cells extending downward from the epidermis. Hematoxylin & eosin $\times 20$.

DISCUSSION

The original case report of eccrine poromatosis (12) described a 65-year-old Caucasian man who presented

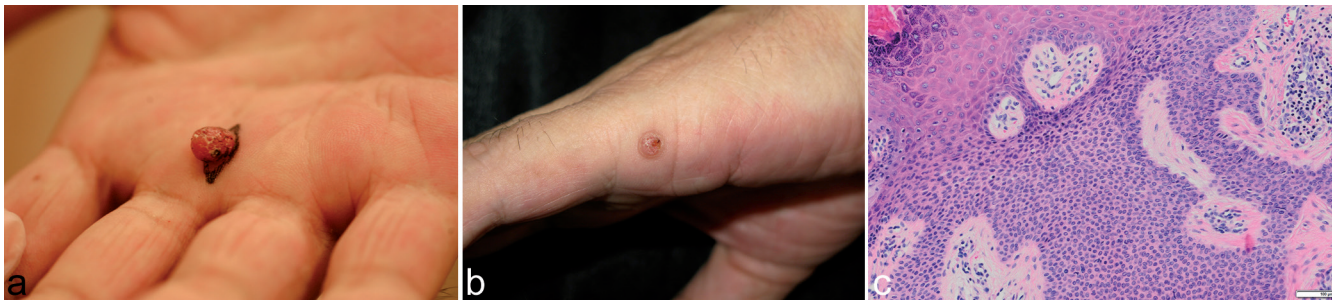

Fig. 3. Clinical appearance of case 3. (a) A pedunculated nodule on the right palm and (b) verrucous papules on the left hand. (c) Histological findings of the papule, showing monotonous small cells with a sharp margin from the adjacent epidermis. Hematoxylin & eosin $\times 200$.

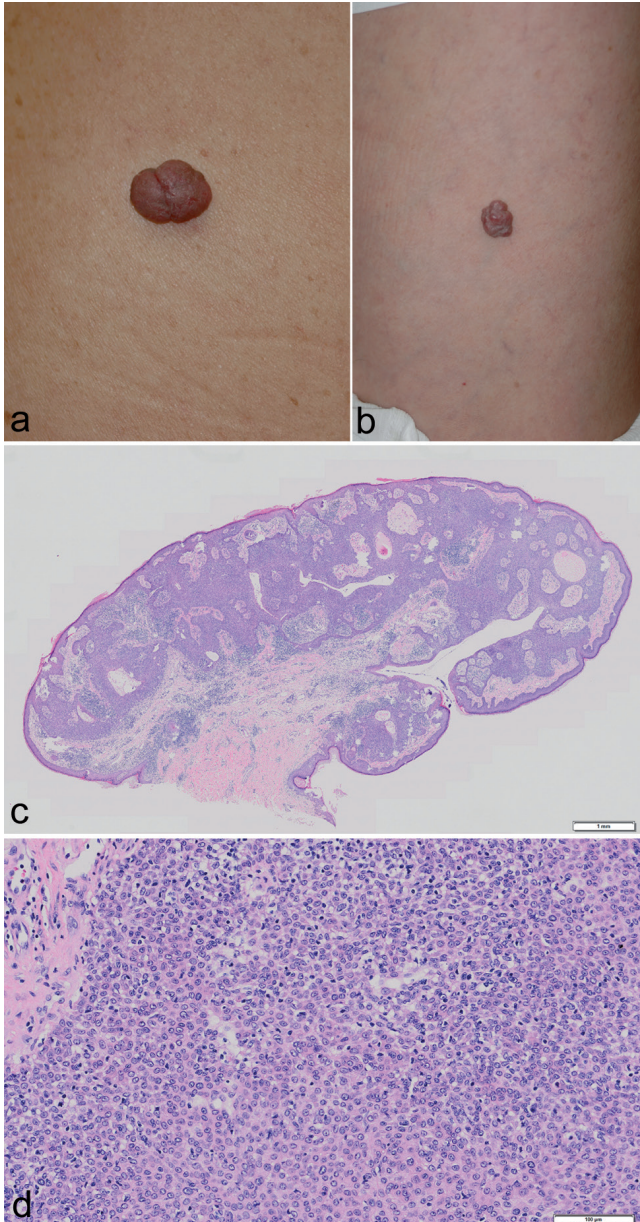


Fig. 4. Clinical appearance of case 4. (a) Pedunculated nodules on the left buttock and (b) left thigh. Histological features of the tumour. (c) Low-power view shows large masses of basaloid cells proliferating downwards from the epidermis. (d) The tumour consists of uniformly small cells with pale eosinophilic cytoplasm. Hematoxylin & eosin, $c \times 20$, $d \times 200$.

with multiple lesions on the palms and soles, with a total of 12 lesions histologically consistent with eccrine poroma. Unfortunately, the patient's medical history was not described. Wilkinson et al. (10) described a patient with hidrotic ectodermal dysplasia who presented with diffuse eccrine poromatosis showing globose papules on the toes and lateral aspects of feet, and generalized solitary papules on the thighs, trunk, and extremities. In that case, the histopathological features were consistent with those typical of poroma, although the clinical features were not.

Apart from these two reported cases, four cases of eccrine poromatosis have been reported in association with radiation therapy or chemotherapy. Ullah et al. (6) described a patient with 7 eccrine poromas arising in an area of chronic radiation dermatitis that was due to radiation therapy administered for osteomyelitis 34 years prior to the onset of the poromas. Kurokawa et al. (7) described a patient with 14 eccrine poromas on irradiated skin 10 years after electron-beam treatment for mycosis fungoides. Mahlberg et al. (8) also reported 14 eccrine poromas on the distal aspects of the extremities, palms and soles of a patient who had previously undergone total body irradiation and allogeneic bone marrow transplantation for acute lymphocytic leukaemia, followed by immunosuppressive therapy for chronic graft-versus-host disease. A recent report (9) described a 64-year-old man with 8 eccrine poromas who had a history of non-Hodgkin's lymphoma treated with combination chemotherapy. Our 4 patients had undergone intensive chemotherapy 6 months to 16 years prior to the onset of poromatosis.

Previous reports (6–8) have described the pathogenic association of radiation therapy with multiple eccrine poromas. In our four patients, however, all eccrine poromas occurred on non-irradiated skin and all the patients had undergone intensive treatment with polychemotherapy for various types of neoplasms. These facts suggest that the chemotherapeutic reagents may be responsible for the occurrence of the multiple eccrine poromas. Thus, past medical history, especially related to chemotherapy or radiotherapy, is important in identifying the probable causes of multiple poromas.

Chemotherapy is a well-documented cause of various cutaneous disorders, such as neutrophilic eccrine hidradenitis (NEH) and syringosquamous metaplasia (13, 14), probably due to the concentration of chemotherapeutic agents or their metabolites in the sweat glands and ducts. Although our patients had no history of such disorders or other cutaneous complications during or after chemotherapy, tissue damage may occur subclinically in the sweat apparatus. Three of our 4 cases, and one previously reported case (9), had a history of chemotherapy-sensitive malignant lymphoma. We believe, therefore, that eccrine poromatosis may occur in long-term survivors, without apparent association with types of malignancies or chemotherapeutic regimens. Long latency periods were observed between the end of chemotherapy or radiotherapy and the diagnosis of eccrine poroma. These observations suggest the possibility that the development of eccrine poroma is associated with remodelling of the sweat apparatus or the regeneration of damaged skin appendages.

ACKNOWLEDGEMENTS

The authors would like to thank medical students Shuhei Murakami, Mao Yoshikawa, Shohei Yoshimura, Sei Manabe, and Masaki Matsumoto, who assisted in the acquisition of clinical data. This work was supported by Grant-in-Aid from The Ministry of Education, Culture, Sports, Science and Technology, Japan (#22791076 and #22659205).

REFERENCES

1. Pinkus H, Rogin JR, Goldman P. Eccrine poromas: tumors exhibiting features of the epidermal sweat duct unit. *Arch Dermatol* 1956; 74: 511–521.
2. Kamiya H, Oyama Z, Kitajima Y. "Apocrine" poroma: review of the literature and case report. *J Cutan Pathol* 2001; 28: 101–104.
3. Hyman AB, Brownstein MH. Eccrine poroma: an analysis of forty-five new cases. *Dermatologica* 1969; 138: 29–38.
4. Johnson RC, Rosenmeier G, Keeling JH III. A painful step: eccrine poroma. *Arch Dermatol* 1992; 128: 1530–1533.
5. Ban M, Kitajima Y. A case of rapidly-growing eccrine poroma during pregnancy. *J Dermatol* 1997; 24: 554–555.
6. Ullah K, Pichler E, Fritsch P. Multiple eccrine poromas arising in chronic radiation dermatitis. *Acta Derm Venereol* 1989; 69: 70–73.
7. Kurokawa M, Amano M, Miyaguni H, Tateyama S, Ogata K, Idemori M, Setayama M. Eccrine poromas in a patient with mycosis fungoides treated with electron beam therapy. *Br J Dermatol* 2001; 145: 830–833.
8. Mahlberg MJ, McGinnis KS, Draft KS, Fakharzadeh SS. Multiple eccrine poromas in the setting of total body irradiation and immunosuppression. *J Am Acad Dermatol* 2006; 55: S46–49.
9. Navi D, Fung M, Lynch PJ. Poromatosis: the occurrence of multiple eccrine poromas. *Dermatol Online J* 2008; 14: 3. Available from: http://dermatology.cdlib.org/141/case_reports/poromatosis/navi.html.
10. Wilkinson RD, Schopflicher P, Rozenfeld M. Hidrotic ectodermal dysplasia with diffuse eccrine poromatosis. *Arch Dermatol* 1977; 113: 472–476.
11. Ogino A. Linear eccrine poroma. *Arch Dermatol* 1976; 112: 841–844.
12. Goldner R. Eccrine poromatosis. *Arch Dermatol* 1970; 101: 606–609.
13. Hurt MA, Halvorson RD, Petr FC Jr, Cooper JT Jr, Friedman DJ. Eccrine squamous syringometaplasia. A cutaneous sweat gland reaction in the histologic spectrum of 'chemotherapy-associated eccrine hidradenitis' and 'neutrophilic eccrine hidradenitis'. *Arch Dermatol* 1990; 126: 73–77.
14. Bachmeyer C, Aractingi S. Neutrophilic eccrine hidradenitis. *Clin Dermatol* 2000; 18: 319–330.