

Serum Levels of CC Chemokine Receptor 4 and CXC Chemokine Receptor 3 Ligands in CD8⁺ Sézary Syndrome

Hiroshi Uchi, Sayaka Hayashida, Masakazu Takahara, Yoichi Moroi and Masutaka Furue

Department of Dermatology, Graduate School of Medical Sciences, Kyushu University, 3-1-1, Maidashi, Fukuoka 812-8582, Japan. E-mail: uchihir@dermatol.med.kyushu-u.ac.jp
Accepted September 10, 2011.

Sézary syndrome is an erythrodermic cutaneous T-cell lymphoma with haematological evidence of leukemic involvement, which is typically characterized by a monoclonal proliferation of atypical CD4⁺CD45RO⁺ lymphocytes (Sézary cells). We report here a case of CD8⁺ Sézary syndrome that was treated successfully with methotrexate. Sézary cells were CD3⁺, CD4⁻, CD8⁺, CD45RO⁺. They also expressed CC chemokine receptor 4 and 10, but not CXC chemokine receptor 3. The number of Sézary cells and serum levels of soluble IL-2 receptor were positively correlated with serum levels of CC chemokine ligand 17, 22 and 27, whereas they were negatively correlated with serum levels of CXC chemokine ligand 10.

CASE REPORT

A 55-year-old man was referred in February 2007 for the investigation of erythroderma and lymphadenopathy. He had been treated with topical corticosteroids with no notable improvement. Clinical examination revealed generalized infiltrated erythema, palmoplantar hyperkeratosis, and bilateral axillary and inguinal lymphadenopathy (Fig 1A). Histological examination of the skin showed acanthosis and dermal perivascular

infiltrate of atypical lymphocytes with little epidermotropism (Fig 1B). Immunohistochemically, these atypical lymphocytes were CD3⁺, CD4⁻, CD8⁺, CD45RO⁺, CCR4⁺, CCR10⁺, and CD56⁻ (Fig 1C–E). Laboratory tests showed a leukocyte count of 19,260/mm³ with 53.5% atypical lymphocytes (10,300/mm³). Lactate dehydrogenase was 599 IU/ml (normal 119–229 IU/ml), and soluble IL-2 receptor (sIL-2R) was 1,632.4 U/ml (206–713 U/ml). Blood flow cytometry showed that 90.6% of lymphocytes were CD8⁺ (CD4/CD8 ratio: 0.06), and 78.3% of CD8⁺ cells expressed CC chemokine receptor 4 (CCR4), but not CXC chemokine receptor 3 (CXCR3). Serum levels of CC chemokine ligand 17 (CCL17), CCL22, CCL27, and CXC chemokine ligand 10 (CXCL10) were 25,400 pg/ml, 7,810 pg/ml, 873 pg/ml, 304 pg/ml, respectively. Infiltration of atypical lymphocytes was also found in the inguinal lymph nodes and bone marrow by histological analyses. Molecular analysis of clonality using a V γ -J γ PCR revealed the presence of an identical predominant clonal rearrangement in the blood and in a skin biopsy sample. Collectively, the patient was diagnosed with CD8⁺ Sézary syndrome.

Since narrowband ultraviolet B (NB-UVB) and psoralen plus ultraviolet A (PUVA) therapies were not

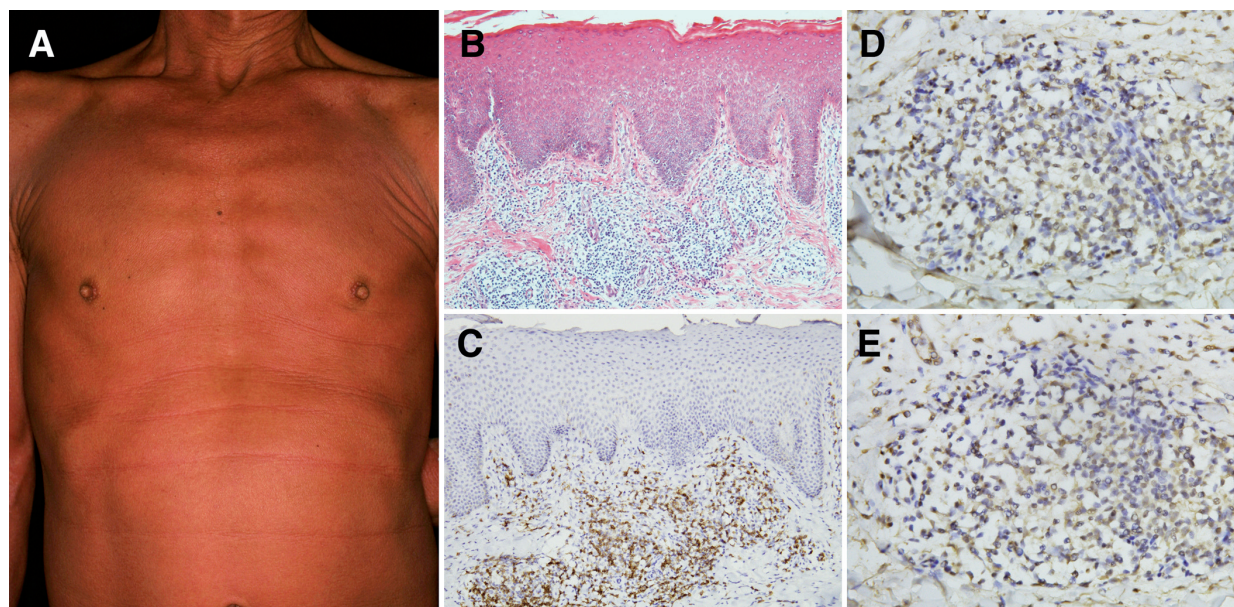


Fig. 1. (A) Generalized erythema on the trunk. (B) Perivascular infiltration of atypical lymphocytes in the dermis (haematoxylin and eosin; original magnification $\times 100$). Immunohistological staining for (C) CD8 (original magnification $\times 100$), (D) CCR4 (original magnification $\times 400$), and (E) CCR10 (original magnification $\times 400$).

effective, we began treatment with methotrexate (5 mg/day, twice a week) in September 2007, and the patient's symptoms gradually improved with a decrease in the number of Sézary cells in the blood to 200/mm³ in 14 months. In keeping with the reduction of the number of Sézary cells and serum levels of sIL-2R, serum levels of CCL17, CCL22, and CCL27 were decreased, whereas those of CXCL10 were increased (Fig. 2). Correlation coefficients between serum levels of chemokines, Sézary cell number in the blood, and serum levels of sIL-2R were 0.93 (CCL17 and Sézary cells; $p < 0.001$), 0.97 (CCL22 and Sézary cells; $p < 0.001$), 0.83 (CCL27 and Sézary cells; $p = 0.007$), -0.85 (CXCL10 and Sézary cells; $p = 0.004$), 0.94 (CCL17 and sIL-2R; $p < 0.001$), 0.78 (CCL22 and sIL-2R; $p = 0.013$), 0.69 (CCL27 and sIL-2R; $p = 0.051$), and -0.64 (CXCL10 and sIL-2R; $p = 0.065$).

DISCUSSION

Sézary cells usually show a mature helper T-cell phenotype (CD3⁺, CD4⁺ and CD45RO⁺). Only a few cases of CD8⁺ Sézary syndrome have been reported, and no report was available concerning chemokine release in the blood and the expression pattern of chemokine receptors in this particular disease (1, 2). We showed for the first time that CD8⁺ Sézary cells express CCR4 and CCR10, but not CXCR3, as previously shown in typical CD4⁺ Sézary cells (3–7), and that the number of Sézary cells and serum levels of sIL-2R were positively correlated with serum levels of CCR4 ligands (CCL17 and CCL22) and CCR10 ligand (CCL27), whereas they were negatively correlated with serum levels of CXCR3 ligand (CXCL10) in CD8⁺ Sézary syndrome. Atypical T cells in cutaneous T-cell lymphomas are known to express several chemokine receptors, such as CCR4, CCR10, and CXCR3. Interactions between

CCR4, CCR10 and their respective ligands have been linked to the recruitment of atypical T cells to the skin (6–8), whereas CXCR3 may play a role in their further infiltration into the epidermis, and CXCR3 is frequently expressed in cutaneous T-cell lymphomas, which show prominent epidermotropism, such as early stages of mycosis fungoides and pagetoid reticulosis (3, 4, 6). Serum levels of CCL17, CCL22, and CCL27 in typical CD4⁺ Sézary syndrome are known to be higher than those of normal subjects (4, 9), and a decrease in serum CCL17 and CCL27 in a case of Sézary syndrome was reported after successful treatment with NB-UVB (10). On the other hand, no report is available concerning serum levels of CXCL10 in Sézary syndrome. Although further studies are needed, we conclude that serum levels of those chemokines could be markers of disease activity in CD8⁺ Sézary syndrome.

ACKNOWLEDGEMENTS

This study was supported by a grant from the Ministry of Health, Labour and Welfare, Japan and the Environmental Technology Development Fund of the Ministry of the Environment, Japan.

REFERENCES

- Lu D, Patel KA, Duvic M, Jones D. Clinical and pathological spectrum of CD8-positive cutaneous T-cell lymphomas. *J Cutan Pathol* 2002; 29: 465–472.
- Pirruccello SJ, Lang MS. Differential expression of CD24-related epitopes in mycosis fungoides/Sézary syndrome: a potential marker for circulating Sézary cells. *Blood* 1990; 76: 2343–2347.
- Yagi H, Seo N, Ohshima A, Itoh T, Itoh N, Horibe T, et al. Chemokine receptor expression in cutaneous T cell and NK/T-cell lymphomas: immunohistochemical staining and in vitro chemotactic assay. *Am J Surg Pathol* 2006; 30: 1111–1119.
- Fierl MT, Comessatti A, Quaglino P, Ortoncelli M, Abate SO, Ponti R. Expression pattern of chemokine receptors and chemokine release in inflammatory erythroderma and Sézary syndrome. *Dermatology* 2006; 213: 284–292.
- Wu X, Lonsdorf AS, Hwang ST. Cutaneous T cell lymphoma: roles for chemokines and chemokine receptors. *J Invest Dermatol* 2009; 129: 1115–1119.
- Ferenczi K, Fuhlbrigge RC, Pinkus JL, Pinkus GS, Kupper TS. Increased CCR4 expression in cutaneous T cell lymphoma. *J Invest Dermatol* 2002; 119: 1405–1410.
- Notohamiprodjo M, Segerer S, Huss R, Hildebrandt B, Soler D, Djafarzadeh R, et al. CCR10 is expressed in cutaneous T-cell lymphoma. *Int J Cancer* 2005; 115: 641–647.
- Hoeller C, Richardson SK, Ng LG, Calero T, Wysocka M, Rook AH, et al. In vivo imaging of cutaneous T-cell lymphoma migration to the skin. *Cancer Res* 2009; 69: 2704–2708.
- Kagami S, Sugaya M, Minatani Y, Ohmatsu H, Kakinuma T, Fujita H, et al. Elevated serum CTACK/CCL27 levels in CTCL. *J Invest Dermatol* 2006; 126: 1189–1191.
- Masui Y, Sugaya M, Kagami S, Fujita H, Yano M, Nagao M, et al. Sézary syndrome treated with narrowband ultraviolet B: time-course measurement of serum levels of CCL17/CCL27. *Clin Exp Dermatol* 2006; 32: 57–59.

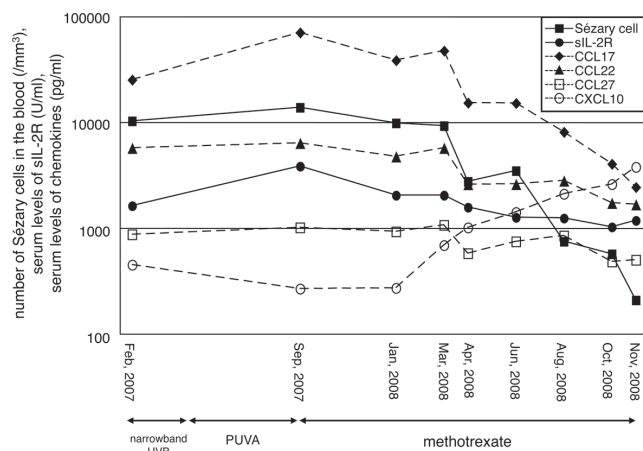


Fig. 2. Time course of the number of Sézary cells in the blood, serum levels of soluble IL-2 receptor (sIL-2R) and serum levels of CCL17, CCL22, CCL27 and CXCL10. PUVA: psoralen plus ultraviolet A; UVB: ultraviolet B.