

Orofacial Granulomatosis as First Manifestation of Crohn's Disease: Successful Treatment of Both Conditions with a Combination of Infliximab and Dapsone

Nicole Kemmler¹, Norbert Pfannschmidt² and Robert Strohal^{1*}

¹Department of Dermatology, Feldkirch, Academic Teaching Hospital, Carinagasse 47, AT-6800 Feldkirch, and ²Dermatology Consultant Office, Feldkirch, Austria. *E-mail: robert.strohal@lkhf.at

Accepted August 31, 2011.

Non-tender labial swelling and oedema of the perioral areas, termed orofacial granulomatosis (OFG), can occur as an isolated symptom or in combination with tuberculosis, Crohn's disease and sarcoidosis. Though genetic predisposition, allergies, infections and immunological mechanisms have been suggested as causative agents, the precise aetiopathology of OFG is unknown and therapeutic options often remain unsatisfactory.

We report here a case of a 14-year-old boy with permanent painless swelling of the lips, oral aphthosis and gingival hyperplasia, representing OFG as a first manifestation of Crohn's disease. Initially resistant to minocycline and high dosages of intravenous methylprednisone, we decided to treat the patient with a combination of the monoclonal, anti-tumour necrosis factor alpha (TNF- α) antibody infliximab and orally administered dapsone, which resulted in complete long-term remission of both clinical conditions.

CASE REPORT

A 14-year-old Caucasian male presented with a 5-month history of permanent painless swelling of the lower lip and, to a lesser extent, the upper lip (Fig. 1a), accompanied by considerable gingival hyperplasia and superficial aphthous ulcers of the oral mucosa. The patient was negative for fever, lymphadenopathy, genital ulcers, arthralgia, ocular symptoms and diarrhoea. His familial history was unremarkable, especially with regard to

angioedema or chronic inflammatory bowel diseases. Laboratory analyses, including serum chemistry profile, differential blood count, C-reactive protein, angiotensin-converting enzyme, C1 esterase inhibitor, complement C3 and C4, autoimmune chemistry and QuantiFERON TB[®] gold test, revealed only a substantial iron-deficiency anaemia. Microbiological tests, including bacterial and fungal cultures from the oral cavity as well as PCR for herpes simplex virus, did not reveal any pathological results. Broad allergological testing did not show any sensitization against relevant external material, such as toothpaste, food or food additives. A chest X-ray was normal, with no signs of sarcoidosis or tuberculosis. A biopsy from the lower lip was performed. Histopathological examination showed multiple non-necrotizing epithelioid granulomas with multinucleate giant cells, together with a dense inflammatory infiltrate composed mainly of lymphocytes and plasma cells (Fig. 1b). Taken together, the diagnosis of OFG could be made.

Based on the iron-deficiency anaemia, a colonoscopy was performed, and showed inflammation in the area of the terminal ileum with erosions, next to epithelialized fields (Fig. 1c). Magnetic resonance tomography of the same area revealed discontinuous swelling of the intestinal wall, particularly in the ileum area. Gastroscopy was without pathology. The histopathological picture of sequential biopsies of the terminal ileum and the colon was essentially the same as that of the lips, with multiple non-necrotizing epithelioid granulomas and a dense pericryptal inflammatory infiltrate (Fig. 1d). All in all, the diagnostic results were typical for Crohn's disease. Consequently, our patient presented with OFG as the first manifestation of an otherwise clinically symptom-free Crohn's disease.

Six weeks of oral minocycline, 50 mg per day, had no effect. Next, 2 weeks of intravenous methylprednisone, initially 250 mg

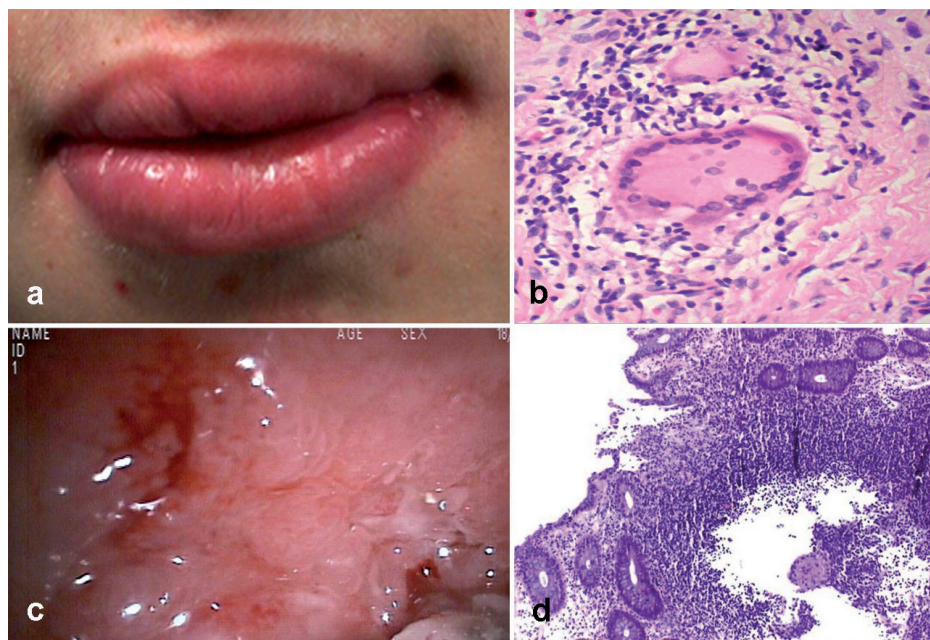


Fig. 1. (a) Permanent painless swelling of the lower lip and, to a lesser extent, the upper lip. (b) A non-necrotized granuloma consisting of multinucleate giant cells and surrounded by a dense inflammatory infiltrate (haematoxylin and eosin (H&E), $\times 400$). (c) Signs of inflammation at the terminal ileum with diffuse erosions, next to newly epithelialized fields. (d) Histopathology of a biopsy from the terminal ileum presents with multiple non-necrotizing epithelioid granulomas and a dense pericryptal inflammatory infiltrate (H&E, $\times 100$).

per day tapered down to 100 mg per day, also had no relevant effect on the OFG. Thus, we decided to start treatment with the chimeric anti-TNF- α monoclonal antibody infliximab (Remicade[®], Centcor B.V., Leiden, The Netherlands) intravenously at a dose of 5 mg per kg body weight; additional courses were administered at weeks 2, 6, 10 and 16. Because of a quite slow initial OFG response, we added dapsone 50 mg orally once per day, starting from infliximab week 2. This resulted in a prompt and complete remission of the orofacial swelling, the oral aphthae and all signs of Crohn's disease. At 13 weeks of continuous dapsone therapy, the gingival hyperplasia also showed full healing. Dapsone was discontinued after 9 months of therapy. With no signs of relapse by 32 months, Crohn's disease was treated with a maintenance therapy of infliximab at 8-week intervals for a total of 12 cycles (up to the end of March 2010).

DISCUSSION

Although the association between OFG and Crohn's disease is well established in the literature (1, 2), the picture of our patient with OFG as the only clinical symptom of Crohn's disease is unusual. Without OFG the substantial iron-deficiency anaemia caused by the Crohn's disease might have become a risk for this young patient. Consequently, in addition to the literature, our case suggests that clinical and laboratory investigations for Crohn's disease should always be part of the routine management in patients with OFG.

There is no specific guideline for the treatment of OFG. Although multiple treatment options have been reported, the results are often disappointing (1). Next to the approval of infliximab for the use in rheumatoid arthritis, Bechterew's disease, psoriasis, psoriasis arthritis, and Crohn's disease (3), cases from the literature harbour some evidence for infliximab as a therapeutic option in patients with OFG (4–7). As OFG can also occur in the context of tuberculosis, it is important to emphasize that TNF- α plays a central role in the formation of granulomas to control mycobacterial infection (8). Thus, in depth screening to exclude tuberculosis (9) is mandatory prior to the use of TNF- α blocking agents,

such as infliximab. The off-label use of dapsone, initially approved for leprosy, is quite common in dermatology, especially with regard to skin conditions defined by multiple granulomas or neutrophilic infiltration. Taking into account that sulphapyridine or sulfasalazine, cognate substances of dapsone, are also effective against mild Crohn's disease (10), we considered the additional use of dapsone in our patient a promising combination.

REFERENCES

1. Grave B, McCullough M, Wiesenfeld D. Orofacial granulomatosis – a 20-year review. *Oral Diseases* 2009; 15: 46–51.
2. Kano Y, Shiohara T, Yagita A, Nagashima M. Association between cheilitis granulomatosa and Crohn's disease. *J Am Acad Dermatol* 1993; 28: 801.
3. Chang JT, Lichtenstein GR. Drug insight: antagonists of tumor necrosis factor- α in the treatment of inflammatory bowel disease. *Nat Clin Pract Gastroenterol Hepatol* 2006; 3: 220–228.
4. Peitsch WK, Kemmler N, Goerdts S, Goebeler M. Infliximab: A novel treatment option for refractory orofacial granulomatosis. *Acta Derm Venereol* 2007; 87: 265–266.
5. Shams MG, Motamedi MH, Azizi T. Orofacial granulomatosis of the lower lip and cheek: report of a case. *Oral Surg Oral Med Oral Pathol Oral Radiol Endod* 2007; 104: e42–44.
6. Mahadevan U, Sandborn WJ. Infliximab for the treatment of orofacial Crohn's disease. *Inflamm Bowel Dis* 2001; 7: 38–42.
7. Barry O, Barry J, Langan S, Murphy M, Fitzgibbon J, Lyons JF. Treatment of granulomatous cheilitis with infliximab. *Arch Dermatol* 2005; 141: 1080–1082.
8. Ehlers S. Why does tumor necrosis factor targeted therapy reactivate tuberculosis? *J Rheumatol Suppl* 2005; 74: 35–39.
9. British Thoracic Society Standards of Care Committee. BTS recommendations for assessing risk and for managing mycobacterium tuberculosis infection and disease in patients due to start anti-TNF- α treatment. *Thorax* 2005; 60: 800–805.
10. van der Kooij K, Davis MD, McCloskey G. Chronic edema of the lips – a rare but real problem: a report of 3 cases and their response to therapy *J Am Acad Dermatol* 2005; 53: 875–877.