

INVESTIGATIVE REPORT

Photodynamic Therapy with Methyl-aminolaevulinic Acid for Mycosis Fungoides

Sang Tae KIM, Dong Young KANG, Jin Seuk KANG, Jae Woo BAEK, Young Seung JEON and Kee Suck SUH
Department of Dermatology, Kosin University College of Medicine, Busan, South Korea

Mycosis fungoides is the most common type of cutaneous T-cell lymphoma. There are a wide range of treatments for early-stage and advanced-stage mycosis fungoides. Photodynamic therapy (PDT) has emerged as a new treatment modality due to its safety and efficacy. The aim of this study was to investigate the safety and efficacy of PDT with methyl-aminolaevulinic acid (MAL) for the treatment of mycosis fungoides. Ten patients with mycosis fungoides were enrolled in this study. A 16.8% MAL cream was applied under occlusive dressing for 3 h. The lesion was irradiated at 37.5 J/cm² with red light. The patients underwent two sessions of PDT at one-week intervals. Follow-up biopsy was performed 3 months after the last treatment. In case of partial response, treatment was repeated once a week until complete response. Seven patients had a good therapeutic response. Complete and partial responses were seen in 5 and 2 patients, respectively. During the follow-up period (8–31 months), 6 of the 7 patients remained in stable remission. The treatment was well-tolerated overall, and no patients discontinued the PDT due to pain. In conclusion, PDT with MAL is a fast, effective and well-tolerated treatment for unilesional mycosis fungoides. Key words: mycosis fungoides; photodynamic therapy; methyl-aminolaevulinic acid.

(Accepted August 22, 2011.)

Acta Derm Venereol 2012; 92: 264–268.

Kee Suck Suh, Department of Dermatology, Kosin University College of Medicine, 34 Amnam-dong, Seo-gu, 602-702 Busan, South Korea. E-mail: ksderm98@unitel.co.kr

Mycosis fungoides (MF) is the most common form of cutaneous T-cell lymphoma. The course of MF is unpredictable. It often progresses through three clinical stages: patch, plaque and tumour or it slowly progresses over years or even decades while remaining confined to the skin. The majority of cases of MF present with localized skin lesions, which progress to lymph node and systemic disease in approximately 10% of cases. Patients with a localized patch (T1 <10% of body surface area) have similar survival rates to the general population, and often experience a normal life-span without progression to the plaque or tumour stages (1). Unilesional MF is a rare variant that is characterized by a single patch or plaque

involving <5% of the body surface area (2–4). This type of MF has a benign course and does not tend to progress into more widespread lesions or tumours or to disseminate to internal organs. In a cohort study, however, the 10-year survival rates for those with generalized patches or plaques (T2), tumours (T3) and erythroderma (T4) were 67.4%, 39.2% and 41%, respectively (1). Current treatment methods for MF with localized lesion are topical steroids, topical chemotherapy, phototherapy and spot radiation therapy (5). These treatments produce acute side-effects or long-term toxicity, such as immunosuppression, due to psoralen and ultraviolet A phototherapy (PUVA).

Recently, photodynamic therapy (PDT) has been used in the treatment of MF. The advantages of topical PDT include minimal systemic toxicity and good cosmetic results. However, PDT is disadvantageous because it is a time-consuming procedure and often requires re-treatment. The most common photosensitizer used for PDT in dermatology is ALA (5-aminolaevulinic acid). Methyl-aminolaevulinic acid (MAL) (Metvix[®] cream) was introduced recently as a dermatological photosensitizer. MAL is a methyl-ester derivative of ALA, but MAL is more lipophilic and selective toward tumour cells and therefore penetrates better through the epidermis and deeper into tumours than does ALA (6, 7). Additionally, MAL-PDT is less painful compared with ALA-PDT because of its selectivity for tumour cells.

Only a few studies of PDT in MF have been published, and their results are controversial because no standardized treatment exists. There is no study of PDT in Asian patients with MF. We performed MAL-PDT in 10 Korean patients with localized MF and investigated its safety and efficacy.

MATERIALS AND METHODS

Patients

Ten Korean patients with localized MF were enrolled in this study (5 males, 5 females; age range 26–68 years (mean 44.1 years)). Any patients with a history of photosensitivity disease or who were using photosensitizing medications were excluded. Nine patients had stage IA (90%) MF and one patient had stage IB (10%). All 10 patients had Fitzpatrick skin types III–V. Seven patients had a single lesion and the other three had multiple lesions. The diagnosis of MF was confirmed via routine histopathology and immunophenotyping, and the duration of disease ranged from 4 months to 14 years (mean 5.1 years).

Seven patients had received previous treatment, such as topical steroids, PUVA, ultraviolet A1 (UVA1), and oral retinoids, prior to PDT, but all previous treatments were ended at least 6 months prior to starting PDT. Patients received no other treatments for MF during the course of the study.

Therapeutic procedure

A 16.8% MAL cream (Metvix® cream, Galderma, Paris, France) was applied topically to the lesion in a 1-mm-thick layer with a 5-mm border extending to the normal skin. The lesion was then covered with an occlusive, light-shielding dressing. After 3 h, the dressings were removed, and the cream was washed off with a 0.9% saline solution. The red fluorescence of porphyrins was visualized with Wood's light before treatment. The lesions were irradiated with red light from a light-emitting diode (LED) (Aktelite CL128, PhotoCure ASA, Oslo, Norway) at a mean wavelength of 630 nm, a total light dosage of 37.5 J/cm² and an irradiation intensity of 75 mW/cm² at skin level for 8 min 20 s. The irradiance was measured with an IL-1700 photometer (International Light, Newburyport, MA, USA).

The patients received 2 MAL-PDT sessions at a 1-week intervals. Follow-up biopsy was performed 3 months after the final treatment. In case of partial response, PDT was repeated weekly until complete clearing. Any adverse effects, such as pain, erythema, hyperpigmentation, hypopigmentation, blistering, ulceration and necrosis and scarring, were recorded after PDT. The intensity of pain during the procedure was measured using a visual analogue scale (VAS). Pain was evaluated by VAS ranging from 0 to 10, where 0=no pain and 10=worst unendurable pain.

Assessment of therapeutic effectiveness

Therapeutic effectiveness was assessed according to the clinical and histological responses. Clinical response was evaluated by two dermatologists who were blinded to the study, at baseline, 1 month and 3 months after treatment. The clinical response was graded as either a complete response (95–100%), a partial response (50–95%) or no response (<50%). Complete and partial responses were regarded as good therapeutic responses. Photographs were taken with a digital camera (Sony, Tokyo, Japan, alpha 350, 10.0 megapixels) with the patient in the same position under controlled lighting conditions before each treatment session and 3 months after the last treatment. Histological response was evaluated 3 months after the last treatment.

RESULTS

Seven of 10 patients with MF achieved a good therapeutic response, and 3 patients had no response. Seven patients with therapeutic responses had unilesional MF, and the other 3 patients with no response had multiple lesions. Complete and partial responses were observed in 5 and 2 patients, respectively (Table I). Four of the 5 patients with a complete response received two sessions of PDT (Fig. 1 A–D). However, the one remaining patient showed a partial response after two PDT sessions and finally achieved a complete response after three additional PDT sessions (Fig. 1 E, F). Two patients who achieved a partial response did not receive a histological evaluation. On histological evaluation, 5 of 8 patients showed a complete response (Fig. 2).

During the course of treatment, none of the patients reported any adverse effects except for variable de-

Table I. Clinical data and clinical responses of 10 patients with mycosis fungoides (MF) treated with photodynamic therapy (PDT)

Patient	Age, years/ sex	Stage	Skin type	MF lesion	Location	Size, cm	Duration, months	Previous treatment	PDT treatments, n	Pain score Mean	Clinical response	Histological response	Follow-up, months	Relapse, months
1	47/M	IA	V	Patch	Face	6 × 3	36	UVA1 acitretin	2	3.0	CR	CR	31	–
2	49/F	IA	V	Patch	Face	1 × 1	4	–	2	2.5	CR	CR	11	–
3	37/F	IA	IV	Plaque	Scalp	2 × 1.5	24	Topical steroid	2	0.5	CR	CR	8	–
4	68/M	IA	IV	Plaque	Abdomen	4 × 3	60	–	5	1.8	CR	CR	19	–
5	37/F	IA	III	Patch	Face	4 × 2.5	48	Topical steroid	2	1.0	PR	–	22	–
6	52/M	IA	IV	Plaque	Palm	7 × 4	9	Topical steroid	6	4.5	PR	–	15	9
7	60/M	IA	III	Plaque	Buttock	8.5 × 3.5	168	Topical steroid	2	1.5	CR	CR	28	–
8	36/M	IB	III	Plaque	Buttock	11 × 9	120	Acitretin	2	1.0	NR	NR	22	–
9	29/F	IA	V	Plaque	Leg	8 × 6 6 × 5 1 × 1	120	Topical steroid PUVA Topical steroid	2	2.5	NR	NR	15	–
10	26/F	IA	IV	Patch	Leg	0.5 × 0.5 3 × 1.5 2 × 1 4 × 3 1 × 1	24	–	2	2.0	NR	NR	23	–

UVA1: ultraviolet A1; CR: complete response; PR: partial response; NR: no response.

grees of pain and erythema. The main problem was the variable degree of pain. The reported pain scores using a 10-cm VAS ranged from 1 to 7. However, no patients discontinued PDT due to pain or received local anaesthesia during the course of the study. Serious adverse effects, such as blistering, ulceration and necrosis, were not observed.

One of the patients with a partial response relapsed 9 months after the last treatment. The relapsed patient achieved a partial response after two sessions of PDT. The patient underwent an additional 4 sessions of PDT, but did not obtain a complete response. The other 6 patients who achieved a good therapeutic response did not relapse within a mean follow-up period of 19.1 months after the last treatment.

DISCUSSION

A good therapeutic response to PDT with MAL was achieved in 7 of 10 patients with localized MF lesions in this study. Seven patients with a good therapeutic response had unilesional MF, and the other 3 patients with no response had multiple lesions. Complete and partial responses were observed in 5 and 2 patients after 2 ses-

sions of PDT, respectively. One of patients with a partial response achieved a complete response after 3 additional treatments. One of the patients who had a partial response relapsed after 9 months. This patient received four additional PDT treatments, but only a partial response was achieved. This patient had lesions of the palms, which may have played a role in the treatment response. The stratum corneum of the palms is thicker than that of other body surface areas, so the patient might not have achieved a complete response despite receiving a total of 6 treatments, due to the thickness of the affected area. Our patients with unilesional MF beneficially responded to two sessions of PDT during the follow-up period. Edstrom et al. (8) reported that larger plaques, with a diameter of 7.5 cm or more, showed less successful responses after PDT. However, in another study, two patients with larger plaques with diameters of at least 10 cm showed complete remission after four to five treatments (9). We observed that response to the PDT was not influenced by the lesion size, but may be related to the number of lesions, the thickness of the stratum corneum, the degree of tumour-cell infiltration, and the invasion depth.

The mechanism of PDT in MF is not yet completely understood. In addition to the direct destruction of

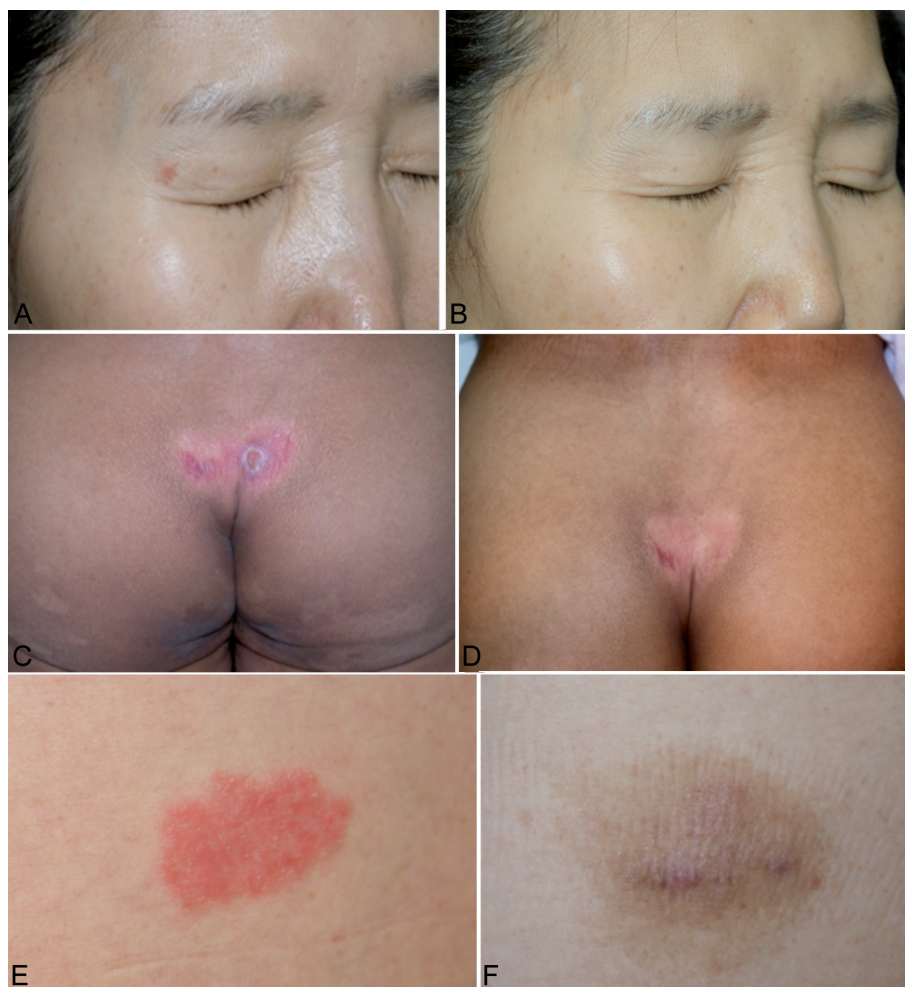

Fig. 1. (A) Clinical features of patient with unilesional mycosis fungoides (MF) before treatment. (B) Complete response was achieved after two sessions of photodynamic therapy (PDT) (case 2). (C) Clinical features of patient with unilesional MF before treatment. (D) Complete response was achieved after two sessions of PDT (case 7). (E) Clinical features of patient with unilesional MF before treatment. (F) Complete response was achieved after five sessions of PDT (case 4).

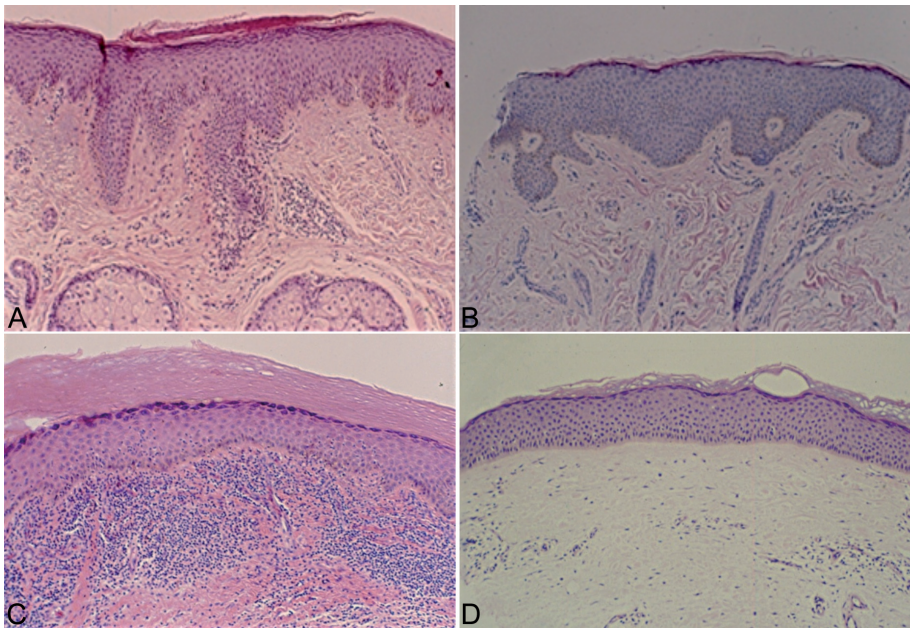


Fig. 2. (A) Histopathological features of patient with unilesional mycosis fungoides (MF) before treatment (haematoxylin and eosin (H&E)×100). (B) Complete response was observed at 3 months after two sessions of photodynamic therapy (PDT) (H&E×100) (case 1). (C) Histopathological features of patient with unilesional MF before treatment (H&E×100). (D) Complete response was observed at 3 months after two sessions of PDT (H&E×100) (case 7).

malignant lymphocytes by the generation of reactive oxygen species, there may be a contribution from the PDT-induced inflammatory reaction, although this possibility requires further confirmation. The maximal efficacy of PDT is achieved through the use of a highly selective accumulation of photosensitizers and light. MAL is a methyl-ester of ALA that has increased lipophilicity, a shorter incubation time and a higher selectivity for malignant lymphocytes compared with those of ALA (20–22).

Patients with patch- or plaque-stage MF who receive PUVA, UVA1 or narrowband UVB therapy have to receive at least 15–20 treatments to obtain a complete response (23), whereas MF patients treated with PDT require fewer treatment sessions to achieve good results (8, 9, 16, 17, 24). In this study participants showed good therapeutic responses after 2 to 6 sessions of PDT. Also, PDT is simple and convenient without systemic side-effects.

Histological therapeutic response is more important than clinical response with regard to MF disease charac-

teristics. We suggest that a final decision about complete or partial response should depend on histological confirmation. In this study, seven patients with unilesional MF had obvious improvement. With a few exceptions, most previous studies had no histological follow-up (9, 16, 19). In this study, 8 of 10 patients received histological follow-up whereof 5 patients had identical clinical and histological complete response.

Optimal parameters for ALA-PDT or MAL-PDT have not been defined for the treatment of MF. Little is known about the optimum number of treatments, frequency of treatment, optimal dose of irradiation, or application time for ALA-PDT or MAL-PDT. According to previous reports, light dosimetry, application time of photosensitizer and frequency of treatment were not markedly different in the treatment of MF (9, 16–18, 24). However, there was great variation in the number of irradiations for ALA-PDT (1–8). The authors speculate that the variation in number of treatments needed is due to MF being a T-cell disease, unlike actinic keratosis, Bowen’s disease and basal cell carcinoma, which are

Table II. Summary of previous reports of photodynamic therapy (PDT) for mycosis fungoides

Reference	Patients <i>n</i>	Clinical features	Topical photosensitizer	Dose J/cm ²	Mean PDT <i>n</i>	Lesions <i>n</i>	Clinical response <i>n</i>	Histological response <i>n</i>	Follow-up, months <i>n</i>
Wolf et al. (9)	2	Plaque	ALA	40	4.5	3	CR: 3	CR: 3	3–6
Svanberg et al. (24)	2	Not reported	ALA	60	1.5	4	CR: 2	Not done	6–14
Orenstein et al. (16)	2	Patch, Tumour	ALA	170, 720	1	6	CR: 6	CR: 6	24–27
Markham et al. (19)	1	Tumour	ALA	20	5	1	CR: 1	CR: 1	12
Leman et al. (17)	1	Plaque	ALA	100	4	2	CR: 2	CR: 2	12
Coors & von den Driesch (18)	2	Plaque, Tumour	ALA	96, 72–144	5	4	CR: 4	Not done	14–18
Zane et al. (6)	5	Patch	MAL	37.5	3.8	NR	CR	CR: 4, PR: 1	12–34
Recio et al. (11)	2	Plaque	ALA	8	3	2	CR: 2	CR: 2	24
Edström et al. (8)	9	Plaque, Tumour	ALA	90–180	3.9	12	CR: 7	CR: 7	6–9 years

NR: not reported; CR: complete response; PR: partial response; ALA: 5-aminolaevulinic acid; MAL: methyl-aminolaevulinic acid.

keratinocyte diseases. In addition, the difference in the number of treatments may be related to the small size of the studies and inclusion of different types of MF patients. MF has a clinical course that can be ameliorated or that can relapse for a prolonged period of follow-up. Therefore, physicians must verify whether or not a complete response has been achieved according to histological clearance as well as clinical clearance.

In conclusion, good therapeutic results were observed when using MAL-PDT to treat unilesional MF. PDT is well tolerated and provides good cosmetic outcomes. Further large-scale and long-term follow-up studies are needed to establish the optimal treatment protocol for unilesional MF.

REFERENCES

- Zackheim HS, Amin S, Kashani-Sabet M, McMillan A. Prognosis in cutaneous T-cell lymphoma by skin stage: long-term survival in 489 patients. *J Am Acad Dermatol* 1999; 40: 418–425.
- Oliver GF, Winkelmann RK. Unilesional mycosis fungoides: a distinct entity. *J Am Acad Dermatol* 1989; 20: 63–70.
- Heald PW, Glusac EJ. Unilesional cutaneous T-cell lymphoma: clinical features, therapy, and follow-up of 10 patients with a treatment-responsive mycosis fungoides variant. *J Am Acad Dermatol* 2000; 42: 283–285.
- Hodak E, Phenig E, Amichai B, Feinmesser M, Kuten A, Maron L, et al. Unilesional mycosis fungoides: a study of seven cases. *Dermatology* 2000; 201: 300–306.
- Willemze R, Dreyling M. Primary cutaneous lymphoma: ESMO clinical practice guidelines for diagnosis, treatment and follow-up. *Ann Oncol* 2010; 21: 177–180.
- Zane C, Venturini M, Sala R, Calzavara-Pinton P. Photodynamic therapy with methylaminolevulinate as a valuable treatment option for unilesional cutaneous T-cell lymphoma. *Photodermatol Photoimmunol Photomed* 2006; 22: 254–258.
- Rud E, Gederaas O, Hogset A, Berg K. 5-aminolevulinic acid, but not 5-aminolevulinic acid esters, is transported into adenocarcinoma cells by system BETA transporters. *Photochem Photobiol* 2000; 71: 640–647.
- Edström DW, Hedblad MA. Long-term follow-up of photodynamic therapy for mycosis fungoides. *Acta Derm Venereol* 2008; 88: 288–290.
- Wolf P, Fink-Puches R, Cerroni L, Kerl H. Photodynamic therapy for mycosis fungoides after topical photosensitization with 5-aminolevulinic acid. *J Am Acad Dermatol* 1994; 31: 678–680.
- Woringer F, Kolopp P. Lésion erythémato-squaméuse polycyclique de l'avant-bras évoluant depuis 6 ans chez un garçon de 13 ans: histologiquement infiltrat intra-épidermique d'apparence tumorale. *Ann Dermatol Syphiligr* 1940; 10: 945–958 cited from *Dermatology* 1999; 199: 174–176.
- Recio ED, Zambrano B, Alonso ML, de Eusebio E, Martín M, Cuevas J, et al. Topical 5-aminolevulinic acid photodynamic therapy for the treatment of unilesional mycosis fungoides: a report of two cases and review of the literature. *Int J Dermatol* 2008; 47: 410–413.
- Berger CL, Wang N, Christensen I, Longley J, Heald P, Edelson RL. The immune response to class I-associated tumor-specific cutaneous T-cell lymphoma antigens. *J Invest Dermatol* 1996; 107: 392–397.
- Hoppe RT, Medeiros LJ, Warnke RA, Wood GS. CD8-positive tumor-infiltrating lymphocytes influence the long-term survival of patients with mycosis fungoides. *J Am Acad Dermatol* 1995; 32: 448–453.
- Dummer R, Kamarashev J, Kempf W, Häffner AC, Hess-Schmid M, Burg G. Junctional CD8+ cutaneous lymphomas with nonaggressive clinical behaviour. *Arch Dermatol* 2002; 138: 199–203.
- van Doorn R, Van Haselen CW, van Voorst Vader PC. Mycosis fungoides: disease evolution and prognosis of 309 Dutch patients. *Arch Dermatol* 2000; 136: 504–510.
- Orenstein A, Haik J, Tamir J, Winkler E, Trau H, Malik Z, et al. Photodynamic therapy of cutaneous lymphoma using 5-aminolevulinic acid topical application. *Dermatol Surg* 2000; 26: 765–770.
- Leman JA, Dick DC, Morton CA. Topical 5-ALA photodynamic therapy for the treatment of cutaneous T-cell lymphoma. *Clin Exp Dermatol* 2002; 27: 516–518.
- Coors EA, von den Driesch P. Topical photodynamic therapy for patients with therapy-resistant lesions of cutaneous T-cell lymphoma. *J Am Acad Dermatol* 2004; 50: 363–367.
- Markham T, Sheahan K, Collins P. Topical 5-aminolaevulinic acid photodynamic therapy for tumour-stage mycosis fungoides. *Br J Dermatol* 2001; 144: 1262–1263.
- Rhodes LE, de Rie M, Enstrom Y, Groves R, Morken T, Goulden V, et al. Photodynamic therapy using topical methyl aminolevulinate vs surgery for nodular basal cell carcinoma: results of a multicenter randomized prospective trial. *Arch Dermatol* 2004; 140: 17–23.
- Fritsch C, Homey B, Stahl W, Lehmann P, Ruzicka T, Sies H. Preferential relative porphyrin enrichment in solar keratoses upon topical application of delta-aminolevulinic acid methylester. *Photochem Photobiol* 1998; 68: 218–221.
- Freeman M, Vinciullo C, Francis D, Spelman L, Nguyen R, Fergin P, et al. A comparison of photodynamic therapy using topical methyl aminolevulinate (Metvix) with single cycle cryotherapy in patients with actinic keratosis: a prospective, randomized study. *J Dermatolog Treat* 2003; 14: 99–106.
- Plettenberg H, Stege H, Megahed M, Ruzicka T, Hosokawa Y, Tsuji T, et al. Ultraviolet A1 (340–400 nm) phototherapy for cutaneous T-cell lymphoma. *J Am Acad Dermatol* 1999; 41: 47–50.
- Svanberg K, Andersson T, Killander D, Wang I, Stenram U, Andersson-Engels S, et al. Photodynamic therapy of non-melanoma malignant tumours of the skin using topical delta-amino levulinic acid sensitization and laser irradiation. *Br J Dermatol* 1994; 130: 743–751.