

## A Case of IgG/IgA Pemphigus Presenting Malar Rash-like Erythema

Satomi Hosoda<sup>1</sup>, Masayuki Suzuki<sup>1</sup>, Mayumi Komine<sup>1\*</sup>, Satoru Murata<sup>1</sup>, Takashi Hashimoto<sup>2</sup> and Mamitaro Ohtsuki<sup>1</sup>

Departments of Dermatology, <sup>1</sup>Jichi Medical University, 3311-1 Yakushiji, Shimotsuke, Tochigi 329-0498 and <sup>2</sup>Kurume University School of Medicine, and Kurume University Institute of Cutaneous Cell Biology, Fukuoka, Japan. \*E-mail: mkomine12@jichi.ac.jp

Accepted August 17, 2011.

Pemphigus is an autoimmune mucocutaneous bullous disease characterized by auto-antibodies against cell surface antigens of epidermal keratinocytes. Pemphigus vulgaris (PV) and pemphigus foliaceus (PF) are the major subtypes. Several other variants have been proposed, including pemphigus erythematosus, pemphigus vegetans, pemphigus herpetiformis (PH), and paraneoplastic pemphigus. Deposition of IgG on epidermal keratinocyte cell surfaces and circulating anti-cell surface antibodies are characteristic in pemphigus. Cases involving IgA deposition on epidermal keratinocyte cell surfaces have been reported as IgA pemphigus. IgA pemphigus is divided into 4 subgroups based on clinical manifestation: subcorneal pustular dermatosis type, intraepidermal neutrophilic IgA dermatosis type, pemphigus foliaceus type, and pemphigus vulgaris type. Cases involving deposition of both IgG and IgA on keratinocyte cell surfaces have been reported (1–13). Some authors describe them as IgG/IgA pemphigus (1). Seventeen such cases have been reported so far, and heterogeneity of clinical features and target antigen has been detected in this group of pemphigus.

### CASE REPORT

A 62-year-old Japanese woman was referred to our department with a 1-month history of pruritic skin lesions. The patient had no other significant medical problems and took no medications. The skin lesions were initially confined to her back, but gradually spread to the trunk and extremities. Some lesions formed annular erythema with scales or superficial crusts (Fig. 1A). Oral and genital mucosae were not involved. Nikolsky's sign was negative. Five months after the first visit, she presented malar rash-like facial erythema with vesicles on the border (Fig. 1B). The results of laboratory tests, including peripheral blood cell counts, erythrocyte sedimentation rate, and liver and renal function tests, were all within normal range. Antinuclear antibody was 1:40. Anti-double-stranded DNA antibody, anti-Sm antibody, anti-SS-A antibody, and anti-SS-B antibody were negative (<7.0 U/ml). The serum C3 level was 115 mg/dl (normal 86–160 mg/dl) and the C4 level was 29 mg/dl (normal 17–45 mg/dl). Chest and abdominal computed tomography revealed no abnormal findings.

A biopsy specimen obtained from a scaly annular erythema on the abdomen revealed neutrophilic spongiosis in the epidermis and marked oedema in the superficial dermis (Fig. 2).

Direct immunofluorescence (IF) of perilesional skin revealed deposition of IgG and IgA antibodies on the cell surface of keratinocytes throughout the epidermis, being stronger in the upper layers (Fig. 3). Direct IF with anti-IgG subclass antibodies revealed that the deposited IgG comprised IgG<sub>1</sub>, IgG<sub>2</sub>, and IgG<sub>4</sub> subclasses. No deposition of immunoglobulins was observed at the basement membrane zone. Indirect IF using normal human skin sections as a substrate revealed IgG and IgA class anti-cell surface antibodies at titres of 1:1024 and 1:128, respectively.

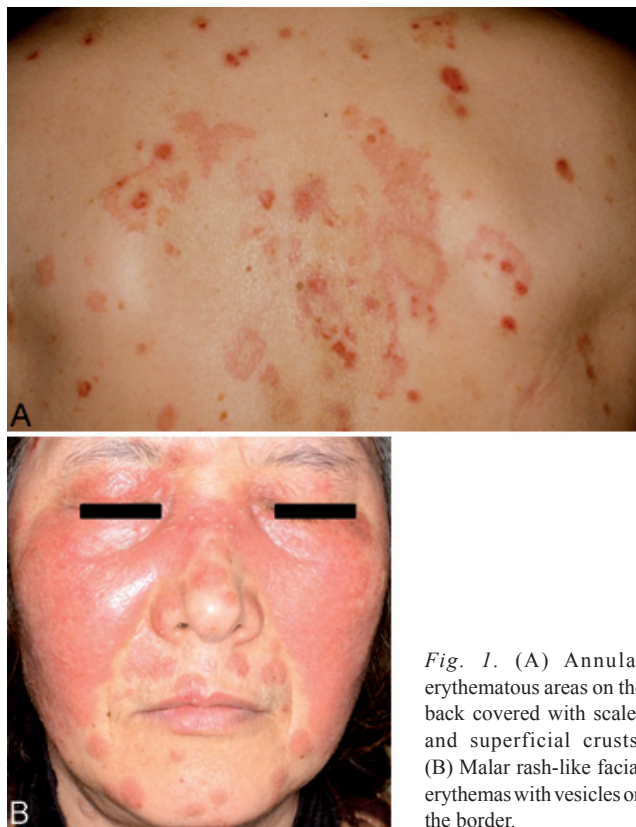

Fig. 1. (A) Annular erythematous areas on the back covered with scales and superficial crusts. (B) Malar rash-like facial erythemas with vesicles on the border.

Specific enzyme-linked immunosorbent assay (ELISA) for IgG and IgA antibodies to desmoglein (Dsg) 1 and Dsg 3 was performed using a commercial ELISA kit (MBL, Nagoya, Japan). This revealed the presence of IgG (index 160, cut-off 5) and IgA (OD 450 0.226, cut-off 0.138) antibodies to Dsg1, but no antibodies to Dsg3. Expression vectors for desmocollins 1, 2 and 3 were generated and transfected to COS7 cells (2). IF revealed the existence of IgG antibodies reacting with desmocollins 1, 2 and 3, while there were no IgA antibodies to any desmocollins. A diagnosis of IgG/IgA pemphigus was made based on these findings. Treatment with topical glucocorticosteroids was initiated, but this was insufficient to suppress the disease activity. Dapsone (50 mg/day) was initiated, which was effective on the trunk lesions, but did not improve the facial lesions. We added prednisolone (20 mg/day), and the malar rash-like erythema gradually improved.

### DISCUSSION

We initially considered the diagnosis of this case to be pemphigus erythematosus because malar rash-like erythemas were observed and anti-Dsg1 IgG antibody was detected. However, the histopathological finding of neutrophilic spongiosis, IgG and IgA deposition on

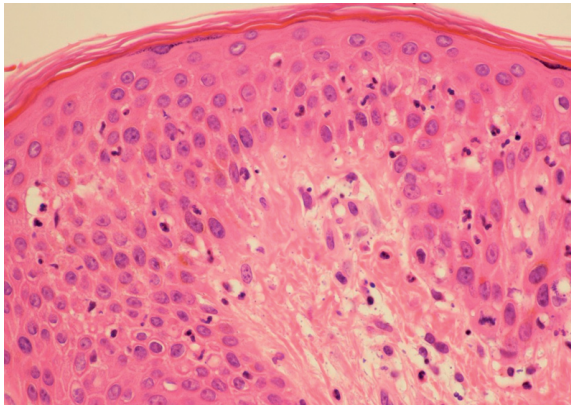


Fig. 2. Histopathological study demonstrating neutrophilic spongiosis. (Haematoxylin-eosin staining  $\times 40$  objective lens).

keratinocyte cell surfaces and the co-existence of anti-Dsg1 IgG and IgA antibodies made us reconsider the diagnosis as IgG/IgA pemphigus.

Nishikawa et al. (3) made the first report of IgG/IgA pemphigus in 1987, when they described an atypical pemphigus foliaceus case. Since then, 17 cases have been reported in the English literature (4–13), but whether IgG/IgA pemphigus exists as a single clinical entity remains controversial. Clinical features of the reported cases demonstrate divergence, including cases that resemble PV, PF, and PH. Annular erythematous regions with small vesicles were observed in 6 cases, while pustules were observed in 5 cases. Involvement of oral mucosa was observed in 2 cases. Histopathological findings revealed neutrophilic infiltration with or without abscess formation in 10 cases. Eosinophilic infiltration was found only in 1 case and acantholysis was observed in 9 cases. Immunoblotting, ELISA, or cDNA transfection study revealed heterogeneity of antigens, and multiple antibodies to different antigens were present in the same patients. IgG antibodies to Dsg1, Dsg3, desmocollins and desmoplakin were detected in 10, 7, 3 and 1 cases, respectively. IgA antibodies to Dsg1, Dsg3, desmocollins and desmoplakin were detected in 10, 5, 3 and 1 cases, respectively. IgG and IgA antibodies to Dsg1 were detected in most of the cases. We detected IgG antibodies to Dsg1, desmocollin 1, 2 and 3, with IgA antibodies to Dsg1 in our case. This heterogeneity of auto-antigens could be one of the characteristics of this entity, which would make its clinical features com-

plex, and the preferential appearance of auto-antibodies against desmocollins may be characteristic (1). The pathological role of auto-antibodies to desmocollin 3 has been shown by *in vitro* study (14). In addition, anti-desmocollin 3 antibodies have been shown to cause acantholytic dermatosis resembling pemphigus vulgaris (15). These results may suggest that IgG/IgA antibodies to desmocollins may play a pathogenic role in the development of IgG/IgA pemphigus.

## REFERENCES

1. Hashimoto T. Recent advances in the study of the pathology of pemphigus. *Arch Dermatol Res* 2003; 295: S2–11.
2. Hashimoto T, Kiyokawa C, Mori O, Miyasato M, Chidgey MA, Garrod DR, et al. Human desmocollin 1 (Dsc1) is an autoantigen for the subcorneal pustular dermatosis type of IgA pemphigus. *J Invest Dermatol* 1997; 109: 127–131.
3. Nishikawa T, Shimizu H, Hashimoto T. Role of IgA intercellular antibodies: report of clinically and immunopathologically atypical cases. *Proceedings of the XVII. World Congress Dermatol* 1987; 383–384.
4. Zaraq I, Kerkeni N, Sellami M, Chelly I, Zitouna M, Maknis Mokni M, et al. IgG/IgA pemphigus with IgG and IgA anti desmoglein 3 antibodies and IgA antidesmoglein antibodies detected enzyme-linked immunosorbent assay: a case report and review of the literature. *Int J Dermatol* 2010; 49: 298–302.
5. Chorzelski TP, Hashimoto T, Nishikawa T, Ebihara T, Dmochowski M, Ismail M, et al. Unusual acantholytic bullous dermatosis associated with neoplasia and IgG and IgA antibodies against bovine desmocollins I and II. *J Am Acad Dermatol* 1994; 31: 351–355.
6. Maruyama H, Kawachi Y, Fujisawa Y, Itoh S, Furuta J, Ishii Y, et al. IgA/IgG pemphigus positive for anti-desmoglein 1 autoantibody. *Eur J Dermatol* 2007; 17: 94–95.
7. Kowalewski C, Hashimoto T, Amagai M, Jablonska S, Mackiewicz W, Wozniak K. IgA/IgG pemphigus: a new atypical subset of pemphigus? *Acta Derm Venereol* 2006; 86: 357–358.
8. Nakajima K, Hashimoto T, Nakajima H, Yokogawa M, Ikeda M, Kodama H. IgG/IgA pemphigus with dyskeratotic acantholysis and intraepidermal neutrophilic microabscesses. *J Dermatol* 2007; 34: 757–760.
9. Gooptu C, Mendelsohn S, Amagai M, Hashimoto T, Nishikawa T, Wojnarowska F. Unique immunobullous disease in a child with a predominantly IgA response to three desmosomal protein. *Br J Dermatol* 1999; 141: 882–886.
10. Oiso N, Yamashita C, Yoshioka K, Amagai M, Komai A, Nagata Y, et al. IgG/IgA pemphigus with IgG and IgA antidesmoglein 1 antibodies detected by enzyme-linked immunosorbent assay. *Br J Dermatol* 2002; 147: 1012–1017.

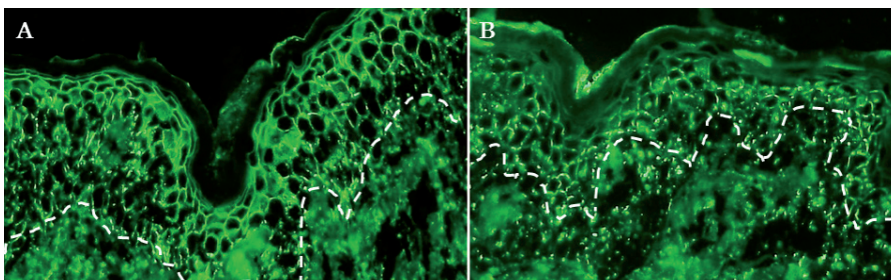


Fig. 3. Direct immunofluorescence study revealed intercellular (A) IgG and (B) IgA deposit in the epidermis ( $\times 40$  objective lens). Basement membrane was indicated in perforated line.

11. Kozłowska A, Hashimoto T, Jarzabek-Chorzelska M, Amaga A, Nagata Y, Strasz Z, Jabłonska S. Pemphigus herpetiformis with IgA and IgG antibodies to desmoglein 1 and IgG antibodies to desmocollin 3. *J Am Acad Dermatol* 2003; 48: 117–122.
12. Bruckner AL, Fitzpatrick JE, Hashimoto T, Weston WL, Morelli JG. Atypical IgA/IgG pemphigus involving the skin, oral mucosa, and colon in a child: a novel variant of IgA pemphigus? *Pediatric Dermatol* 2005; 22: 321–327.
13. Inui S, Amagai M, Tsutsui S, Fukuhara-Yoshida S, Itami S, Katayama I. Atypical pemphigus involving the esophagus with IgG antibodies to desmoglein 3 and IgA antibodies to desmoglein 1. *J Am Acad Dermatol* 2006; 55: 354–355.
14. Rafei D, Müller R, Ishii N, Llamazares M, Hashimoto T, Hertl M, et al. IgG autoantibodies against desmocollin 3 in pemphigus sera induce loss of keratinocyte adhesion. *Am J Pathol* 2011; 178: 718–723.
15. Mao X, Nagler AR, Farber SA, Choi EJ, Jackson LH, Leiferman KM, et al. Autoimmunity to desmocollin 3 in pemphigus vulgaris. *Am J Pathol* 2010; 177: 2724–2730.