

## Reactive Perforating Collagenosis during Erlotinib Therapy

Yasuhiro Suzuki and Toshiyuki Yamamoto

Department of Dermatology, Fukushima Medical University, Hikarigaoka 1, Fukushima 960-1295, Japan. E-mail: toyamade@fmu.ac.jp

Accepted August 15, 2011.

Erlotinib is an epidermal growth factor receptor (EGF-R) tyrosine kinase inhibitor used for chemotherapy-resistant non-small cell lung cancer. Cutaneous toxicity is frequently seen, and the well-known adverse effects are dry skin, folliculitis, paronychia, and periungual granuloma (1). We describe here a case of reactive perforating collagenosis possibly triggered by erlotinib in a patient with well-controlled diabetes mellitus (DM).

### CASE REPORT

A 68-year-old man was referred to our department with pruritic papulopustular lesions on his trunk of 2 months' duration. He had small cell lung carcinoma (stage IV) with multiple metastases to the bone, brain, liver, and suprarenal glands. Also, he had non-insulin-dependent DM, which had been well-controlled through diet for years. He had started erlotinib (Tarceva®) (150 mg/day) for lung carcinoma 3 months previously. He stated that he had no pruritus before starting erlotinib. Two weeks after the initiation of oral erlotinib, he noticed periungual redness on a few digits. Thereafter, reddish acneiform small papules appeared on his scalp and face, and spread to his trunk. In addition, itchy nodules appeared on his back, which gradually worsened.

Physical examination revealed a number of nodules with keratotic plugs on his upper back and shoulders (Fig. 1), along with numerous acneiform red papules and pustules on the trunk. Periungual granuloma was found on the second and fourth finger of the right hand, and the third finger of the left hand. Further vitiligo lesions were seen on the head, back, dorsa of hands and fingers, which appeared over 20 years ago. Labo-

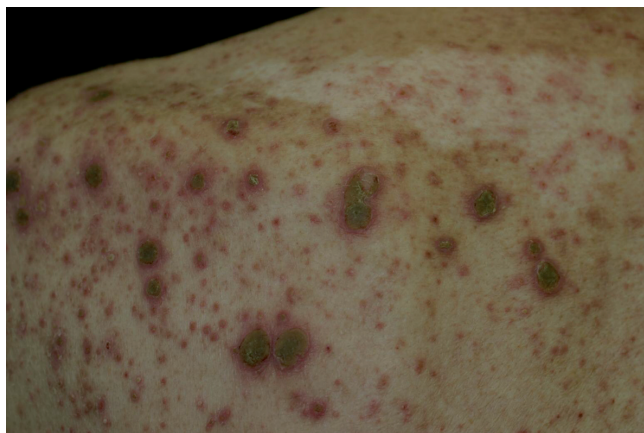

Fig. 1. Hyperkeratotic umbilicated nodules intermingled with acneiform small follicular red papules on the back.

ratory examination showed a slightly increased level of C-reactive protein (0.93 mg/dl, normal <0.3 mg/dl), but blood glucose was 106 mg/dl (normal 70–109 mg/dl) and HbA1C was 4.9% (normal 4.3–5.8%). A skin biopsy of a nodule with keratotic plugs showed a cup-shaped depression in the epidermis, and transepidermal elimination of basophilic collagen bundles, surrounded by a lymphocytic and neutrophilic infiltration (Fig. 2). Elastica van Gieson stain revealed degenerated collagen fibres transversely eliminated through the epidermis. On the basis of clinical and histological findings, he was diagnosed with perforating collagenosis, as well as folliculitis and paronychia. Along with a dose-decrease of erlotinib (100 mg/day), he was treated with topical beta-methasone butylate propionate twice daily. The keratotic nodules started to resolve within 3 weeks, and were flattened with pigmentation 3 months later. Folliculitis was improved by topical clindamycin gel within one month. Blood glucose and HbA1C levels were within normal limits during the course of treatment.

### DISCUSSION

Cutaneous eruptions are frequently observed during erlotinib therapy, such as papulopustular follicular eruption, paronychia, dry skin, hair changes, mucositis, and so on. The cutaneous toxicity is dose-related. Among them, folliculitis is the most common side-effect (occurring in up to 75% of cases) exhibiting acneiform eruptions on the face, chest, back, and pubic region (2). Erlotinib is an EGF-R tyrosine kinase inhibitor, which

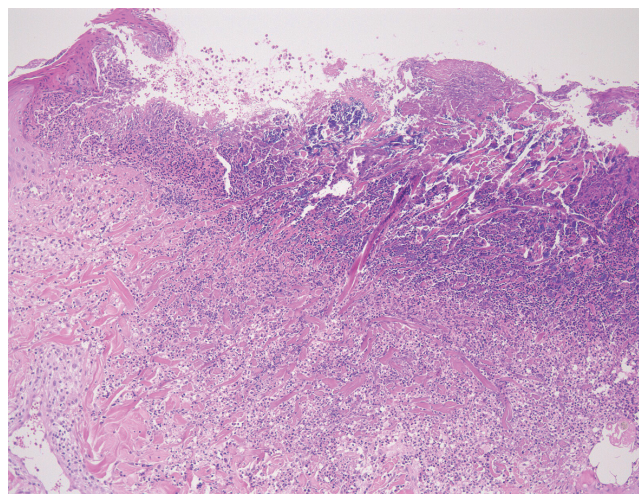


Fig. 2. Histopathology showing dermal collagen perforating through the epidermis (haematoxylin-eosin, magnification  $\times 100$ ).

acts through competitive binding of the adenosine triphosphate-binding domain of the receptor, and inhibits the proliferation of various cancer cells. EGF-R is expressed in the basal layer of the epidermis, outer root sheath of the hair follicles, and sebaceous and sweat gland apparatus. Therefore, inhibition of EGF-R may result in abnormal epidermal differentiation leading to follicular obstruction and subsequent inflammation.

Our patient almost simultaneously developed folliculitis and a number of papulonodular lesions of perforating collagenosis 2 weeks after initiation of erlotinib. Acquired reactive perforating collagenosis (ARPC) is characterized by transepidermal elimination of altered collagen. Clinically, a number of umbilicated papules and nodules with central keratotic plugs develop on the trunk and extremities. Histopathology shows necrobiotic basophilic collagen bundles that run transversely through the epidermis. ARPC is seen in association with various systemic disorders in susceptible persons, and in particular frequently associated with uncontrolled severe DM (3, 4). In addition, chronic renal failure, malignancies, viral infection, lung fibrosis, and thyroid dysfunction have been reported (4). At first, we suspected that ARPC was induced by exacerbation of DM, and not associated with erlotinib therapy. However, the patient's DM was well-controlled and laboratory examination demonstrated normal levels of blood glucose and HbA1c. Other complications, such as renal insufficiency, liver dysfunction, and thyroid disease, were all denied. ARPC is triggered by minor trauma, such as folliculitis, arthropod bites, and scabies infection (5–8). Koebnerization seems to play an important role. Patients with severe DM have pruritus, and scratching may cause microtrauma and necrobiosis of the dermal structure, possibly by diabetic microangiopathy. Insufficient blood supply as a result of diabetic vasculopathy may be an underlying factor in ARPC. In the present case, follicular occlusion caused by altered differentiation of the epithelium due to inhibition of EGF-R may induce ARPC in a diabetic patient in spite of being under good control. It is unusual that ARPC developed in a diabetic patient with fair metabolic control.

Although several cases of ARPC in patients with malignancies have been reported (9–13), our patient developed ARPC, folliculitis, and paronychia almost simultaneously following erlotinib therapy. Both folliculitis and ARPC were induced in a dose-related manner, and the decrease

in erlotinib as well as topical clindamycin for acneiform eruption and steroid for ARPC suppressed new onset of ARPC, and led to improvement. Therefore, we conclude that ARPC may have been induced by erlotinib in this patient. Although the DM was well-controlled, microangiopathy associated with DM may have contributed to a predisposition for ARPC in this case.

*The authors declare no conflict of interest.*

## REFERENCES

1. Robert C, Soria J-C, Spatz A, Le Cesne A, Malka D, Pautier P, et al. Cutaneous side-effects of kinase inhibitors and blocking antibodies. *Lancet Oncol* 2005; 6: 491–500.
2. Roé E, Garcia Muret MP, Marcuello E, Capdevila J, Pallarés C, Alomar A. Description and management of cutaneous side effects during cetuximab or erlotinib treatments: a prospective study of 30 patients. *J Am Acad Dermatol* 2006; 55: 429–437.
3. Faver IR, Daoud MS, Daniel Su WP. Acquired reactive perforating collagenosis: report of six cases and review of the literature. *J Am Acad Dermatol* 1994; 30: 575–580.
4. Karpouzis A, Giatromanolaki A, Sivridis E, Kouskoukis C. Acquired reactive perforating collagenosis: current status. *J Dermatol* 2010; 37: 585–592.
5. Kurschat P, Kröger A, Scharffetter-Kochanek K, Hunzelmann N. Acquired reactive perforating collagenosis triggered by scabies infection. *Acta Derm Venereol* 2000; 80: 384–385.
6. Kim EJ, Kim MY, Kim HO, Park YM. Acquired reactive perforating collagenosis triggered by insect bite. *J Dermatol* 2007; 34: 677–679.
7. Ikezaki E, Sugita K, Kabashima K, Tokura Y. Scabies-induced acquired reactive perforating collagenosis. *J Eur Acad Dermatol Venereol* 2008; 22: 120–121.
8. Ghosh SK, Bandyopadhyay D, Chatterjee G. Acquired reactive perforating collagenosis following insect bite. *Indian J Dermatol Venereol Leprol* 2009; 75: 306–307.
9. Lee YS, Vijayasingam S, Tan YO, Wong ST. Acquired perforating dermatosis associated with recurrent hepatocellular carcinoma. *Int J Dermatol* 1996; 35: 743–745.
10. Boeck K, Mempel M, Hein R, Ring J. Acquired perforating collagenosis in a patient with carcinoma of the prostate. *Acta Derm Venereol* 1997; 77: 486–487.
11. Bong JL, Fleming CJ, Kemmett D. Reactive perforating collagenosis associated with underlying malignancy. *Br J Dermatol* 2000; 142: 390–391.
12. Ruiz-Villaverde R, Martin Sanchez MC, Blasco Melguizo J, Naranjo Sintés R. Reactive perforating collagenosis and colon carcinoma. *Rev Clin Esp* 2002; 202: 298–299.
13. Kilic A, Gönül M, Cakmak SK, Gül U, Demiriz M. Acquired reactive perforating collagenosis as a presenting sign of hepatocellular carcinoma. *Eur J Dermatol* 2006; 16: 447.