

Topical TRPM8 Agonist (Icilin) Relieved Vulva Pruritus Originating From Lichen Sclerosus et Atrophicus

Jung Hyun Han¹, Hoo-Kyun Choi² and Seong J. Kim^{1*}

¹Department of Dermatology, Chonnam National University Medical School, 8 Hak-Dong, Dong-Gu, Gwangju, 501-757 and ²BK21 Project Team, College of Pharmacy, Chosun University, Gwangju, Korea. *E-mail: seongkim@chonnam.ac.kr
Accepted July 27, 2011.

Pruritus vulvae is caused by a variety of skin diseases, as well as by neuropathic/neurological, psychosomatic and psychiatric diseases. It is difficult to determine the pathogenesis of itching symptoms over the vulval area, but ongoing inflammatory reactions, may be responsible for lowering the perception threshold of itching (1, 2).

A variety of topical treatments has been used to reduce genital pruritus, including menthol, camphor, tannin preparations, local anaesthetics, antiseptics, urea preparations, glucocorticosteroids, immunomodulators and N-palmitoyl-ethanolamine-containing cream (3). General advice for relief of pruritic symptoms include avoiding sweating and occlusion of the skin, and reducing potential irritative cleansing habits. Empirical observation supports the use of cold compression over the pruritic skin lesion to relieve unpleasant nociception, such as itch and sensation of heat. Thus, local cooling sense evoked by TRPM8 activation can give a wisdom of controlling pruritus as shown in this case.

CASE REPORT

A 54-year-old woman was referred from the department of gynaecology due to uncontrolled itching over the vulval area, which had persisted for one year. She had a history of total hysterectomy for stage T1aN0Mx endometrial carcinoma 3 months previously, but the ongoing itching sensation had not changed after surgery. Physical examination revealed a genital lesion with excoriated lichenification on whitish atrophic linear patches along the labia major (Fig. 1). The patient had been screened for psychiatric disorders such as depression, anxiety, delusion and obsessive compulsive disorder, but no reliable association was revealed.

We asked her to report the itch intensity in several occasions using a visual analogue scale (VAS) (range: 0 = none to 10 = extreme). Her response was always 9. Laboratory test results, including white blood cell counts, and kidney and liver functions, iron and glucose levels, were all within normal limits. Mycological examination and *Papanicolaou* test results were negative or non-contributory. Skin biopsy was performed and histopathology revealed a thin epidermis with a wide band of hyalinization in the upper dermis mixed with lymphohistiocytic infiltrates suggesting a typical pattern of lichen sclerosus et atrophicus (Fig. 2).

Various topical agents, such as glucocorticoids, antifungal, oestrogen cream, including intralesional triamcinolone injection were all ineffective. The patient reported paroxysmal itching symptoms, sometimes related to sleep disturbance, thus we looked for a new agent that could directly affect the itching afferent sensory perception. Menthol is a well-known TRPM8 receptor agonist, which has been used as an additive in topical formulations to evoke a fresh cooling sensation. However, menthol is somewhat irritating in a high concentration and its action time is very short. Icilin has been recognized to have a higher molecular affinity to the TRPM8

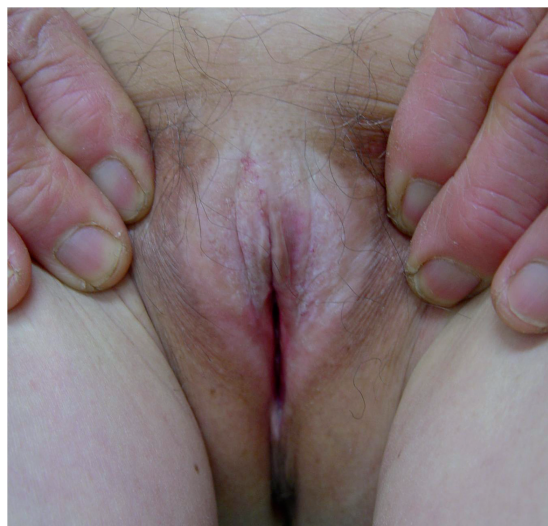

Fig. 1. Excoriated whitish atrophic lichenified patch in the vulval area.

receptor and a longer action time than menthol. Thus we decided to use topical icilin (provided as a gift by Dr Edward Wei, Shasun Pharmaceutical, India) in this case. A range of formulations were studied using penetration kinetics on hairless mouse skin. We chose topical 1% icilin emulsion dissolved in benzyl alcohol, then mixed with gelling agent Lutrol[®] 127, which showed the most favourable penetration profile (Fig. 3).

The itching symptoms were significantly reduced for approximately 10 h after application of 1% icilin over the pruritic vulva area. The application was repeated twice a day and subjective itching VAS was reduced from 9 to 2. The pruritus vulvae was relieved in 7 days with no adverse reactions, such as oedema or erythema. Mild itching symptoms developed 7 days after discontinuation of topical icilin, but this symptom was easily managed by reapplication of the treatment once a day for se-

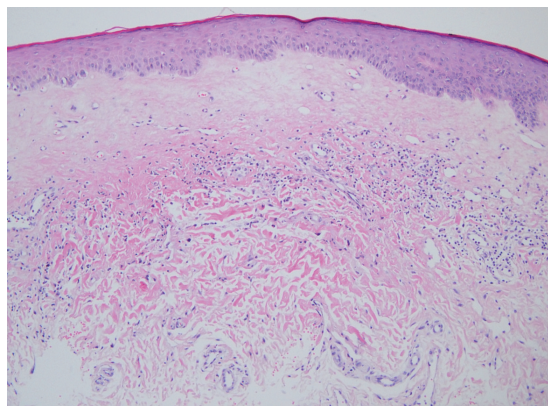


Fig. 2. Histopathological findings, showing thinning epidermal rete ridges and a wide band of upper dermal hyalinization with a scattered lymphohistiocytic infiltration (haematoxylin and eosin staining, original magnification $\times 100$).

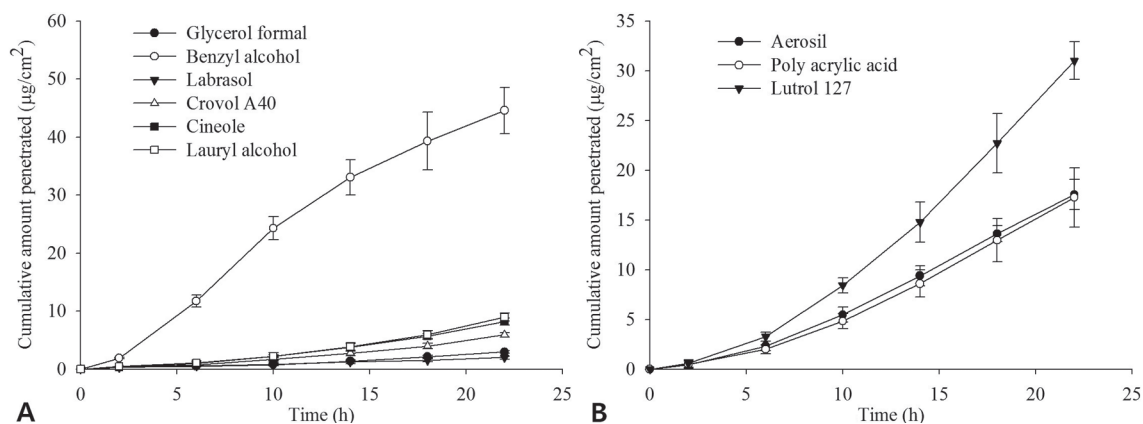


Fig. 3. Pharmacokinetic profile of icilin formulation for transdermal penetration. (A) Benzyl alcohol was a favourable solvent for icilin. (B) Gelling agent Lutrol 127 showed a better pharmacokinetic profile when icilin was emulsified with benzyl alcohol.

veral more days. As the patient was satisfied with the control of vulva pruritus, no further topical icilin was recommended. Intralesional injection of triamcinolone for lichen sclerosus et atrophicus was continued with no itching impulse.

DISCUSSION

Severe itching is a common complication of lichen sclerosus et atrophicus of the vulva. Management of pruritus vulvae can be divided into four stages: (i) identification of the underlying disease; (ii) restoration of the skin barrier function; (iii) reduction of any inflammatory complication; and (iv) elimination of the itch-scratch cycle by psychological affection. Often chronic pruritus cannot easily be alleviated when the itch-scratch cycle has been well established (4). Eliminating the paroxysmal itch perception, as in this case, would be a key factor in treatment of pruritus vulvae of psychological association.

Sedative drugs, such as hydroxyzine, benzodiazepine, zolpidem, tricyclic antidepressants and selective serotonin reuptake inhibitors, can be tried, but care must be taken to observe for adverse reactions involving the central nervous system, such as drowsiness or sedation.

Topical TRPM8 agonist is thought to affect peripheral nociception of afferent sensory neurones by inducing a cooling sensation. However, this has not been proved in a large-scale clinical trial, either by cooling itself or by sensitizing cooling receptors, although it has been suggested that lowering local skin temperature reduced pruritus via a central inhibitory pathway (5). TRPM8 is known to be activated by low temperature (15–20°C), a variety of plant-derived compounds, menthol and icilin. While icilin is not structurally related to menthol, it produces a significant cooling sensation in both

humans and animals, over 200 times more potent than menthol *in vitro* molecular affinity and 2.5 times more efficacious *in vivo* (6, 7).

Until now various topical agents, such as local anaesthetics, glycolcol, oligosaccharides, calamine, capsaicin, doxepin, strontium nitrate, nedocromil sodium, tacrolimus and pimecrolimus, have shown some potential. This case also provides evidence that topical icilin can be an effective adjuvant in managing intractable itch of unknown origin.

ACKNOWLEDGEMENTS

The authors would like to acknowledge and thank Professor Emeritus Edward T. Wei (UC Berkeley, USA) for providing pure icilin and its pre-clinical toxicology safety data for a case trial.

The authors declare no conflicts of interest.

REFERENCES

- Bates SM, Dilke-Wing G. Determination of iron status in woman attending genitourinary clinics with pruritus vulvae. *Sex Transm Infect* 2006; 82: 489–490.
- Weichert GE. An approach to the treatment of anogenital pruritus. *Dermatol Ther* 2004; 17: 129–133.
- Weisshaar E. Successful treatment of genital pruritus using topical immunomodulators as a single therapy in multimorbid patients. *Acta Derm Venereol* 2008; 88: 195–196.
- Lynch PJ. Lichen simplex chronicus (atopic/neurodermatitis) of the anogenital region. *Dermatol Ther* 2004; 17: 8–19.
- Carstens E, Jinks SL. Skin cooling attenuates rat dorsal horn neuronal responses to intracutaneous histamine. *Neuroreport* 1998; 9: 4145–4149.
- McKemy DD, Neuhauser WM, Julius D. Identification of a cold receptor reveals a general role for TRP channels in thermosensation. *Nature* 2002; 416: 52–58.
- Wei ET, Seid DA. AG-3-5: a chemical producing sensations of cold. *J Pharm Pharmacol* 1983; 35: 110–112.