

## LETTERS TO THE EDITOR

### Management of Recalcitrant Hidradenitis Suppurativa with Ustekinumab

Victoria R. Sharon<sup>1</sup>, Miki Shirakawa Garcia<sup>1</sup>, Sepideh Bagheri<sup>1</sup>, Heidi Goodarzi<sup>1</sup>, Clara Yang<sup>1</sup>, Yoko Ono<sup>1</sup> and Emanuel Maverakis<sup>1,2\*</sup>

<sup>1</sup>Department of Dermatology, University of California Davis, Sacramento, 3301 "C" Street, Suite 1400, CA 95816, and <sup>2</sup>Department of Veteran Affairs Northern California Health Care System, Sacramento, USA. \*E mail: emaverakis@ucdavis.edu  
Accepted June 30, 2011.

Hidradenitis suppurativa (HS) is a chronic inflammatory disease resulting from occlusion of the pilosebaceous units within the intertriginous regions of the body. It is characterized by very tender papules, nodules, and neutrophilic abscesses. Sinus tracts with malodorous drainage and scarring can develop. Long-term complications include lymphoedema and fistulae formation. We present here a difficult case of HS that responded well to ustekinumab.

#### CASE REPORT

A 55-year-old male smoker presented to our Veteran Affairs dermatology clinic in September 2008 for continued management of his HS and psoriasis. He was diagnosed with HS at the age of 19 years after presenting with recurrent groin and axillary abscesses and cysts. His HS remained refractory to a variety of treatment modalities, including incision and drainage, oral and topical antibiotics, and oral isotretinoin. At the age of 22 years, he began to develop erythematous scaly lesions, often superimposed on his cutaneous abscesses and cysts. The new lesions were diagnosed as psoriasis and he was started on topical corticosteroids. Over the next several decades, both his psoriasis and HS remained recalcitrant to medical therapy.

On examination, he was an obese male (109.4 kg) with large erythematous fissured plaques in his inguinal folds and well-defined plaques with scale on his trunk and gluteal cleft. The skin of his face and scalp was diffusely erythematous with light scale. There was marked fissuring within a large scaly plaque on his posterior scalp. He had symmetric tenderness of his first interphalangeal joints, and small pits were present on his fingernails. X-rays of his hands and feet and a computed tomography (CT) scan of his pelvis failed to reveal evidence of an autoimmune arthritis. Rheumatoid factor was not elevated. Cutaneous abscesses were also noted in his axillae and groin. There were numerous dilated occluded follicles with underlying erythema on his trunk. Sinus tracks and scarring were noted on his cheeks and axillae. Histological evaluation revealed perifollicular neutrophilic inflammation and multiple epidermal cysts. He was started on, but failed, standard treatment regimens of methotrexate, adalimumab, and mycophenolate.

In the setting of these prior treatment failures, he was started on ustekinumab, 45 mg administered subcutaneously on weeks 0, 4 and 12. A modest response was noted and the dose was then increased to 90 mg administered every 8 weeks. He has now been maintained on this regimen for over one year. Although the patient still has significant residual disease that flares approximately 2 weeks prior to each ustekinumab injection, his psoriasis and HS have improved on ustekinumab therapy (Fig. 1). Prior to the start of ustekinumab therapy his overall

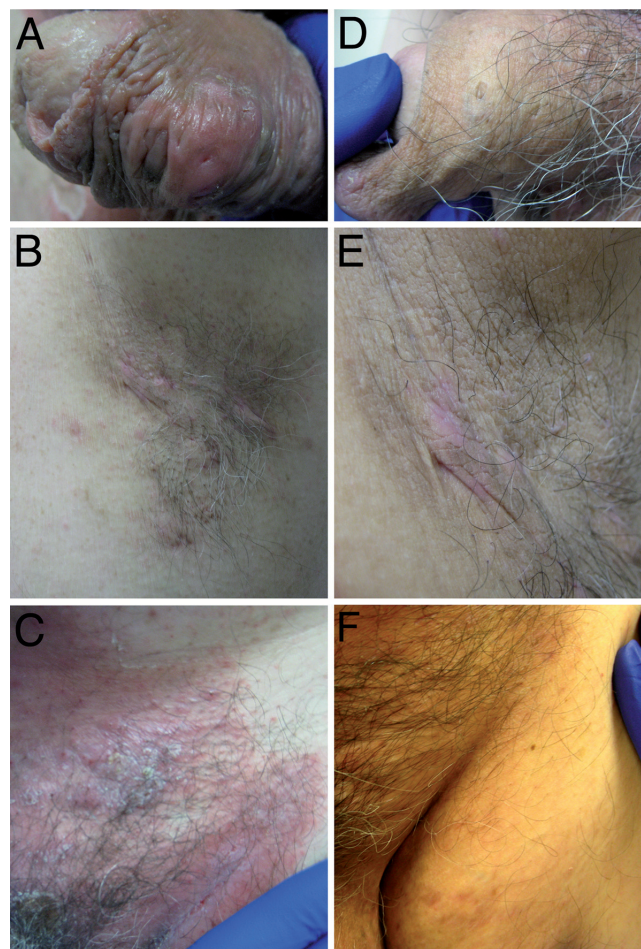


Fig. 1. Clinical response to ustekinumab. (A) An inflammatory penile cyst before, and (B) 6 months after starting ustekinumab therapy. Inflammatory nodules and scarring in his axillae (C) before and (D) after starting ustekinumab therapy. (E) Small abscesses in his groin with overlying inverse psoriasis before ustekinumab therapy. (F) Representative picture of the patient's groin after he started ustekinumab therapy.

HS Sartorius score (1) was 120, and it is now 40 with therapy. The patient also notes subjective improvement in his quality of life and, although a Psoriasis Area and Severity Index (PASI) score was not obtained, his psoriasis is also markedly better.

## DISCUSSION

For patients with HS who have failed to respond to oral and topical antibiotics, adalimumab and infliximab may be of benefit (2). These medications are monoclonal antibodies that decrease inflammation by binding to and neutralizing tumour necrosis factor- $\alpha$  (TNF- $\alpha$ ), a major Th1 cytokine. Of note, patients who have failed one TNF- $\alpha$  antagonist will often respond to a second; an observation that has also been reported in the treatment of HS (3). Unfortunately, our patient failed to respond to adalimumab and did not wish to be started on infliximab. Given his coexisting severe psoriasis, we searched for another intervention able to treat both psoriasis and HS.

In HS, TNF- $\alpha$  is produced by a variety of cells in response to toll-like receptor activation from bacterial overgrowth (4). TNF- $\alpha$  is also produced by Th1 cells, which are dependent on interleukin (IL)-12 for development. Thus, in addition to blocking TNF- $\alpha$  directly, another approach would be to block IL-12 activity.

Ustekinumab is a human anti-p40 monoclonal antibody used to treat patients with psoriasis (5). P40 is a shared subunit of human IL-12 and IL-23, which are important for Th1 and Th17 immune responses respectively. In the presence of IL-12, activated T cells will secrete the classic Th1 cytokines, IFN- $\gamma$  and TNF- $\alpha$ . In contrast, IL-23 promotes the survival of Th17 cells, which are characterized by the production of IL-17A and other cytokines (6), including TNF- $\alpha$  in some cases. Of importance to this current case presentation, IL-17 is also known to be critical for neutrophil recruitment (7), which might explain the observed therapeutic effect of ustekinumab in HS. In theory, infliximab and other TNF- $\alpha$  inhibitors would not block IL-17-dependent neutrophil recruitment. In addition to TNF- $\alpha$  (8), patients with HS have elevated levels of IL-26, IFN- $\gamma$ , IL-24 and IL-1 $\beta$  (9). It is likely that ustekinumab will alter the expression of some of these cytokines as well. For example, injection of IL-23, but not IL-12, induces macrophages to express IL-1 $\beta$  and TNF- $\alpha$  (10). Our case demonstrates a desirable response of HS to IL-12/IL-23 blockade using ustekinumab. Typical of both psoriasis and HS our patient is obese and has a history of tobacco use (11, 12); however, to our knowledge patients with both HS and psoriasis have not been reported. Thus, further studies will be needed to

determine the efficacy of ustekinumab in treating patients with HS unrelated to psoriasis.

## ACKNOWLEDGEMENT

This study was supported in part by career awards from the Burroughs Wellcome Fund and the Howard Hughes Medical Institute.

*The authors declare no conflicts of interest.*

## REFERENCES

1. Sartorius K, Lapins J, Emtestam L, Jemec GB. Suggestions for uniform outcome variables when reporting treatment effects in hidradenitis suppurativa. *Br J Dermatol* 2003; 149: 211–213.
2. Grant A, Gonzalez T, Montgomery MO, Cardenas V, Kerdel FA. Infliximab therapy for patients with moderate to severe hidradenitis suppurativa: a randomized, double-blind, placebo-controlled crossover trial. *J Am Acad Dermatol* 2010; 62: 205–217.
3. Poulin Y. Successful treatment of hidradenitis suppurativa with infliximab in a patient who failed to respond to etanercept. *J Cutan Med Surg* 2009; 13: 221–225.
4. Hunger RE, Surovy AM, Hassan AS, Braathen LR, Yawalkar N. Toll-like receptor 2 is highly expressed in lesions of acne inversa and colocalizes with C-type lectin receptor. *Br J Dermatol* 2008; 158: 691–697.
5. Griffiths CE, Strober BE, van de Kerkhof P, Ho V, Fidelus-Gort R, Yeilding N, et al. Comparison of ustekinumab and etanercept for moderate-to-severe psoriasis. *N Engl J Med* 2010; 362: 118–128.
6. Korn T, Bettelli E, Oukka M, Kuchroo VK. IL-17 and Th17 cells. *Ann Rev Immunol* 2009; 27: 485–517.
7. Ye P, Rodriguez FH, Kanaly S, Stocking KL, Schurr J, Schwarzenberger P, et al. Requirement of interleukin 17 receptor signaling for lung CXCL chemokine and granulocyte colony-stimulating factor expression, neutrophil recruitment, and host defense. *J Exp Med* 2001; 194: 519–527.
8. Matusiak L, Bieniek A, Szepietowski JC. Increased serum tumour necrosis factor- $\alpha$  in hidradenitis suppurativa patients: is there a basis for treatment with anti-tumour necrosis factor- $\alpha$  agents? *Acta Derm Venereol* 2009; 89: 601–603.
9. Wolk K, Warszawska K, Hoefflich C, Witte E, Schneider-Burrus S, Witte K, et al. Deficiency of IL-22 contributes to a chronic inflammatory disease: pathogenetic mechanisms in acne inversa. *J Immunol* 2011; 186: 1228–1239.
10. Cua DJ, Sherlock J, Chen Y, Murphy CA, Joyce B, Seymour B, et al. Interleukin-23 rather than interleukin-12 is the critical cytokine for autoimmune inflammation of the brain. *Nature* 2003; 421: 744–748.
11. Alikhan A, Lynch PJ, Eisen DB. Hidradenitis suppurativa: a comprehensive review. *J Am Acad Dermatol* 2009; 60: 539–561; quiz 562–533.
12. Matusiak L, Bieniek A, Szepietowski JC. Hidradenitis suppurativa and associated factors: still unsolved problems. *J Am Acad Dermatol* 2009; 61: 362–365.