

## LETTERS TO THE EDITOR

### Cutaneous Hyphomycosis Due to *Paecilomyces lilacinus*

Khaled Ezzedine<sup>1</sup>, Emilie Belin<sup>1</sup>, Stéphanie Guillet<sup>1</sup>, Mahussi D'Almeida<sup>2</sup>, Catherine Droitcourt<sup>1</sup>, Isabelle Accocebery<sup>2</sup>, Brigitte Milpied<sup>1</sup>, Thomas Jouary<sup>1</sup>, Denis Malvy<sup>3</sup> and Alain Taieb<sup>1</sup>

<sup>1</sup>Department of Dermatology, <sup>2</sup>Service de Parasitologie, and <sup>3</sup>Service de Médecine interne et maladies tropicales, Hôpital Saint André, CHU Bordeaux, France. E-mail: khaled.ezzedine@chu-bordeaux.fr

Accepted April 28, 2011.

Skin infection with *Paecilomyces lilacinus* is a rare event, but one that is increasingly reported. The fungus may affect various organs, including the skin, eyes, sinuses, and lungs, with variable outcomes. There are no established guidelines for the management of *P. lilacinus* infection (1). We report here a new case of hyphomycosis related to *P. lilacinus* in a patient who had undergone uncontrolled courses of corticosteroid therapy.

#### CASE REPORT

A 60-year-old man was first seen at our department with multiple nodular lesions involving the nose and the right cheek, which had developed over a period of more than 4 months with gradual aggravation. In addition, a new lesion had developed on his left hand 2 months later. The patient had been treated unsuccessfully with oral antibiotics by his referent physician. His medical history was remarkable for rheumatoid arthritis, for which he had frequently undergone uncontrolled courses of oral corticosteroids (40 mg prednisone daily) over the last 10 years. Of note, the patient acknowledged having fallen when working in his garden 5 months previously, with multiple excoriations on the skin on his face. Physical examination revealed multiple tender subcutaneous nodules of varying size, involving half of his right face, including his nose, cheek and sub-palpebral skin, with a pseudo-verrucous aspect and small necrosis at the edge of the nose (Fig. 1a). Another erythematous lesion with an infiltrated pattern was also present on his left

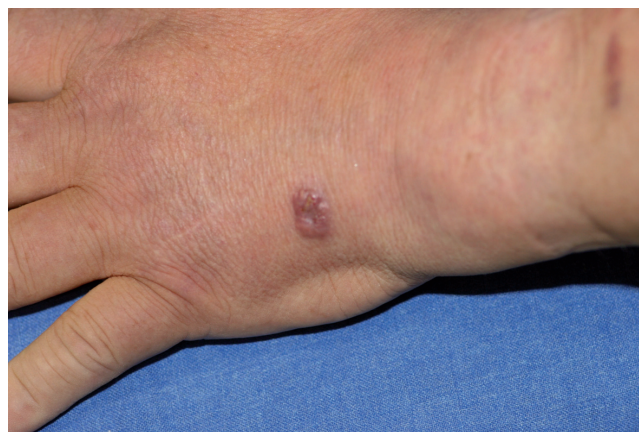

Fig. 2. Erythematous lesion with an infiltrated sporotrichoid pattern.

hand (Fig. 2). No palpable lymph nodes were noted. Blood laboratory examinations, including HIV serology, were normal. Histopathology of a biopsy sample from his cheek revealed the presence of a microgranulomatous infiltrate containing eosinophils and plasmacytes with a tendency to form micro-abscesses (Fig. 3). Periodic acid-Schiff (PAS) and Grocott-Gomori methenamine-silver staining revealed scanty hyphal elements with conidiophores into the deep dermis. In addition, direct examination and culture were performed twice on skin specimens taken from different lesions, and revealed hyaline, septate hyphae with a mould that grew rapidly within 4 days on Sabouraud-dextrose-agar medium containing chloramph-

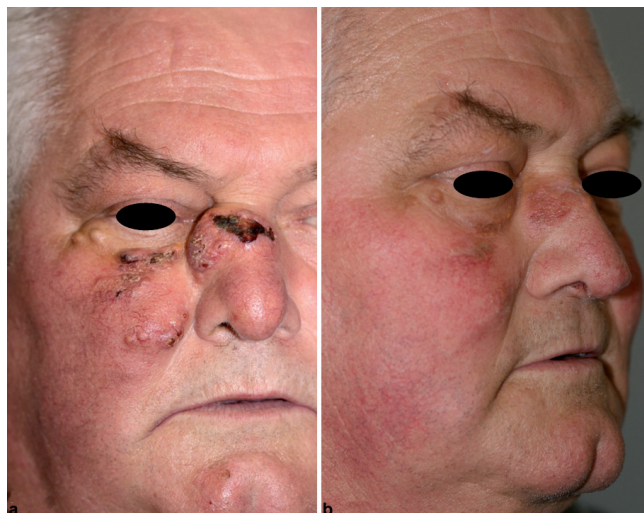

Fig. 1. (a) A 60-year-old patient with multiple tender subcutaneous nodules of varying size involving half of the right side of the face. (b) Remarkable improvement after one month treatment with posaconazole.

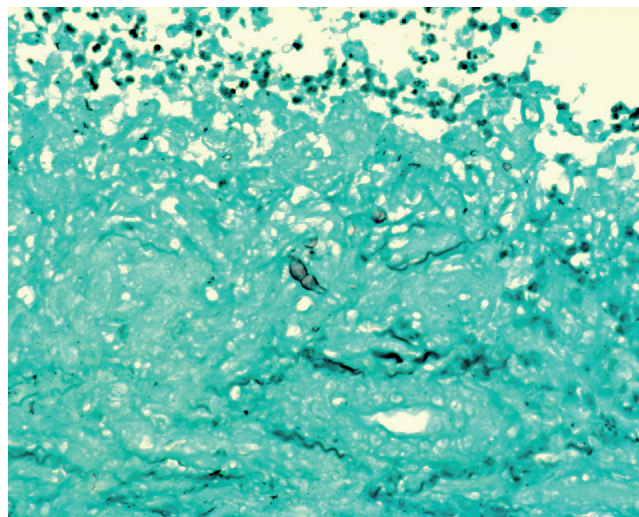


Fig. 3. Grocott-Gomori methenamine-silver staining of a skin specimen biopsy showing fungal elements with septate hyphae ( $\times 200$ ).

nicol without cycloheximide, forming floccose, pinkish mauve colonies. Microscopic examination of slide cultures identified the mould as *P. lilacinus*, and this was further confirmed by PCR amplification. Antifungal susceptibility to various drugs showed the mould to be resistant to various antimycotic drugs, except for voriconazole and posaconazole. With regard to the localization of the infection, magnetic resonance imaging of the patient's head was performed, and revealed right nasal sinusitis with an involvement of the ethmoidal cells. The patient turned down any additional surgical procedure and voriconazole was therefore introduced at a dosage of 200 mg twice daily. This medication was stopped after 10 days due to visual hallucinations. At that time, posaconazole was introduced at a dosage of 400 mg twice daily. The patient stopped taking the drug after 4 weeks because of anorexia associated with an involuntary weight loss of 5 kg. At week 4, clinical improvement was remarkable (Fig. 1b). The patient declined any other treatment and was lost to follow-up.

## DISCUSSION

*P. lilacinus* is a hyaline hyphomycete that is found in soil and air, and has worldwide geographical distribution. Although considered to be rare and of moderate virulence, it may affect both immunocompromised and immunocompetent individuals (1). Moreover, the fungus is frequently resistant to conventional antifungal agents and may be resistant to sterilizing methods and be a recurrent contaminant of lotion. The fungus may therefore be responsible for the colonization of clinical material, such as catheters and plastic implants (2, 3). Thus, *P. lilacinus* has mainly been reported to cause eye infection following surgical procedures for cataract or intraocular lens implantation (4). Cases of cutaneous and subcutaneous *P. lilacinus* infections have rarely been described, although recent reports highlight the role of this fungus as an emerging pathogen for severe skin infection (5). It is probable that our patient was contaminated by direct inoculation following minimal skin abrasion (6). Clinical features of skin infections related to *P. lilacinus* may vary greatly. Hence, in our patient, two distinct clinical features depending on the involved site were noted, i.e. infiltrated lesions of the hand and subcutaneous nodules of the face. Moreover, sinusitis related to *P. lilacinus* has been very sparsely reported and usually follows surgical procedures (4). Most fungal sinusitis usually occurs in deeply immunocompromised patients and is linked to *Aspergillus* species. Fungal infection with *P. lilacinus* was first reported in an adult

female in 1982 (7). Since then other cases of such infections have been reported in immuno-compromised individuals. However, to the best of our knowledge this is the first reported case of both cutaneous and sinus infection in a patient who had never undergone facial surgery. In our patient, sinusitis is probably related to the proximity of the initial lesion with paranasal sinuses, which may have been further contaminated. There is no standard therapy regimen for *P. lilacinus* infection. However, because of its high resistance to conventional azoles, novel antifungal drugs, such as voriconazole and posaconazole, which have shown *in vitro* activity against the mould, are usually preferred.

In conclusion, *P. lilacinus* infection is increasingly reported as a pathogen. The diagnosis of this rare cutaneous infection should be considered not only in transplant recipients receiving immunosuppressive drugs, but also in patients undergoing long-term therapy with oral corticosteroids. Antifungal susceptibility testing should be performed when possible due to the frequent resistance of the mould to conventional azoles.

*The authors declare no conflict of interest.*

## REFERENCES

1. Pastor FJ, Guarro J. Clinical manifestations, treatment and outcome of Paecilomyces lilacinus infections. *Clin Microbiol Infect* 2006; 12: 948–960.
2. Clark NM. Paecilomyces lilacinus infection in a heart transplant recipient and successful treatment with terbinafine. *Clin Infect Dis* 1999; 28: 1169–1170.
3. Gutierrez-Rodero F, Morganon M, Ortiz de la Tabla V, Mayoll MJ, Martin C. Cutaneous hyalohyphomycosis caused by Paecilomyces lilacinus in an immunocompetent host successfully treated with itraconazole: case report and review. *Eur J Clin Microbiol Infect Dis* 1999; 18: 814–818.
4. Gucalp R, Carlisle P, Gialanella P, Mitsudo S, McKittrick J, Dutcher J. Paecilomyces sinusitis in an immunocompromised adult patient: case report and review. *Clin Infect Dis* 1996; 23: 391–393.
5. Carey J, D'Amico R, Sutton DA, Rinaldi MG. Paecilomyces lilacinus vaginitis in an immuno-competent patient. *Emerg Infect Dis* 2003; 9: 1155–1158.
6. Itin PH, Frei R, Lautenschlager S, Buechner SA, Surber C, Gratwohl A, et al. Cutaneous manifestations of Paecilomyces lilacinus infection induced by a contaminated skin lotion in patients who are severely immunosuppressed. *J Am Acad Dermatol* 1998; 39: 401–409.
7. Rowley SD, Strom CG. Paecilomyces fungus infection of the maxillary sinus. *Laryngoscope* 1982; 92: 332–334.