

Narrow-band Ultraviolet B Treatment for Diphenylcyclopropanone-induced Vitiliginous Lesions

Yu-Jin Oh, Min-Kyung Shin and Mu-Hyoung Lee

Department of Dermatology, College of Medicine, Kyung Hee University, #1 Hoegi-dong, Dongdaemun-gu, Seoul 130-702, Korea. E-mail: mhlee@khmc.or.kr
Accepted April 7, 2011.

Topical immunotherapy, defined as the induction and periodic elicitation of an allergic contact dermatitis by topical application of potent contact allergens, has been used to treat conditions such as alopecia areata (AA) and recalcitrant warts since the 1970s (1). Topical immunotherapy with diphenylcyclopropanone (DPCP) is a safe and sometimes effective treatment for chronic extensive AA and viral warts (2).

Pan et al. (3) have reported four patients with AA who developed vitiligo as a side-effect of DPCP immunotherapy. Pires et al. (1) also reported a case of vitiligo following DPCP therapy.

We report here two cases, one patient with viral warts and one with AA, who developed vitiliginous lesions secondary to topical therapy with DPCP. The vitiliginous lesions were subsequently treated with narrow-band ultraviolet B (NB-UVB), and both patients showed excellent responses.

CASE REPORT

Patient 1

A 13-year-old girl presented with a 1-year history of multiple verruca plana on both cheeks. DPCP was applied topically to the upper arm every week for 2 months. However, the treatment had to be discontinued due to a severe hypersensitivity reaction. Four months later, a vitiliginous lesion appeared on her upper arm, corresponding to the area of previous DPCP application (Fig. 1a). The patient had no personal or family history of vitiligo, atopy, or other autoimmune disorders. The results of laboratory studies, which included thyroid auto-antibodies, antinuclear antibody (ANA), complete blood count (CBC), and biochemical panel, were all

normal. The vitiliginous lesion was treated with NB-UVB twice a week on non-consecutive days. The initial irradiation dose was 0.25 J/cm², and this was halted after 21 exposures with a total cumulative dose of 12.15 J/cm². After 3 months of treatment, the lesion showed 80% improvement (Fig. 1b).

Patient 2

A 42-year-old man presented with a hairless patch that had been present for 7 months on the scalp. The scalp revealed scattered, rounded patches of alopecia varying from 1 to 4 cm. After 2 weeks of sensitization with 2% DPCP on scalp, the patient started on a regimen of 0.0001% DPCP, and the concentration was gradually increased to 0.001% by his final weekly session. Gradual hair re-growth was observed. Five months post-treatment, vitiliginous lesions appeared where DPCP had been applied (Fig. 2a). There was no personal or family history of vitiligo, and laboratory studies, which included thyroid auto-antibodies, ANA, CBC, and biochemical panel, were all normal. The vitiliginous lesions were accentuated on Wood's lamp examination (Fig. 2b). These patches were subsequently treated with NB-UVB twice a week. The initial irradiation dose was 0.25 J/cm², and this was halted after 29 exposures with a total cumulative dose of 18.29 J/cm². The vitiliginous lesions disappeared almost completely after 4 months of treatment (Fig. 2c).

DISCUSSION

Topical DPCP immunotherapy is currently considered to be the most effective treatment for conditions that involve immunomodulation. It is usually safe and well-

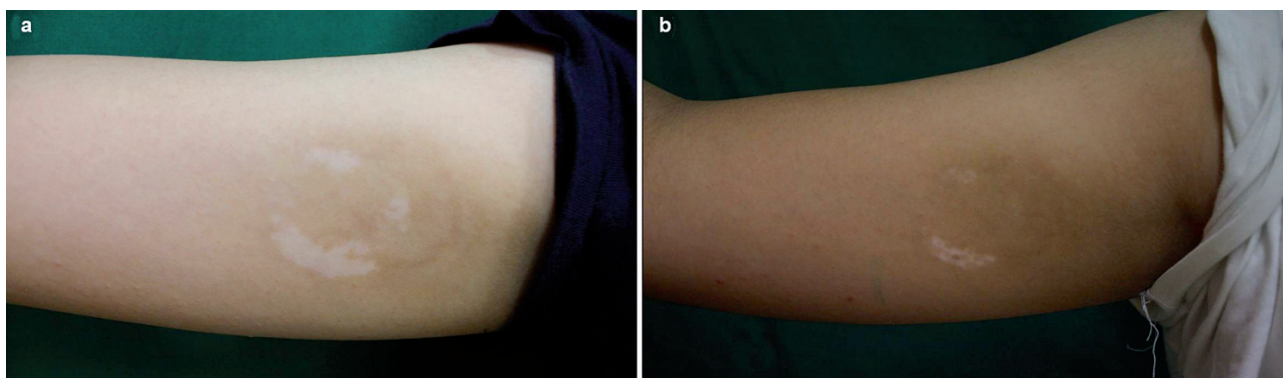


Fig. 1. (a) A vitiliginous lesion appeared on the right arm after application of diphenylcyclopropanone. (b) After 3 months narrow-band ultraviolet B treatment, the lesion showed 80% improvement.

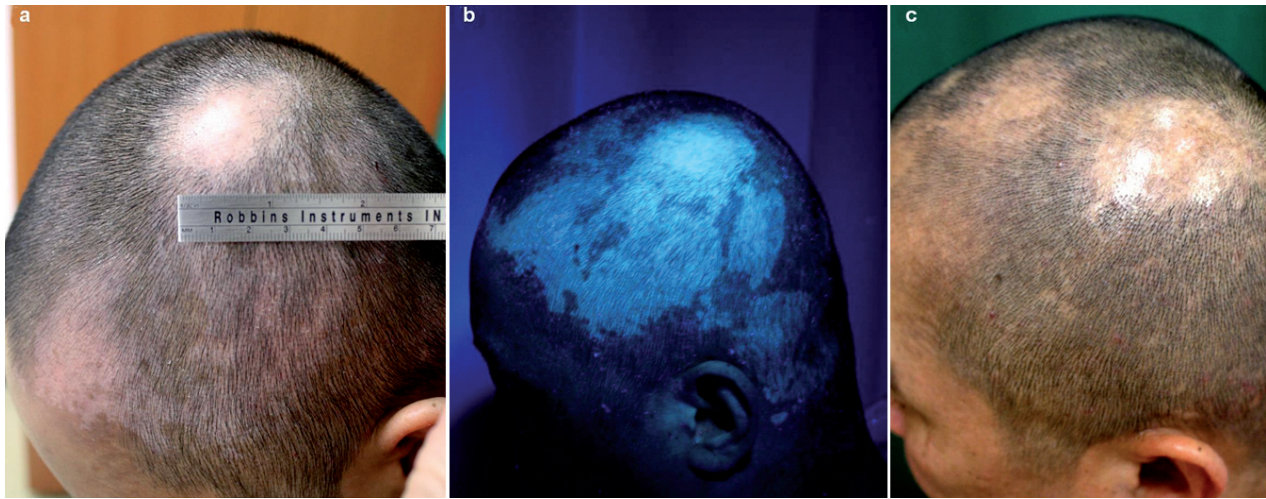

Fig. 2. (a) Vitiliginous lesions appeared on the scalp after application of diphenylcyclopropenone. (b) The lesions were accentuated on Wood's lamp examination. (c) After 4 months narrow-band ultraviolet B treatment, the vitiliginous lesions had disappeared almost completely.

tolerated, but does have side-effects. The most frequent side-effects of DPCP described in the literature are local eczema with blistering, regional lymphadenopathy, and contact urticaria. Rare and more serious effects include an erythema multiforme-like reaction, hyperpigmentation, hypopigmentation, and vitiligo (3).

DPCP-induced vitiligo is a rare phenomenon, and its mechanism of development is not clearly understood. Some authors believe that it may represent a Koebner phenomenon in predisposed individuals (4). Correlations between vitiligo and AA have been reported, ranging from 4% to 9% (4, 5). Latent vitiligo may be unmasked as a result of the Koebner phenomenon from repeated incidences of contact dermatitis (6). Vitiligo may also appear as a result of a direct cytotoxic effect on the melanocyte-associated phenol ring structure (7). Treatment for this form of vitiligo includes discontinuation of DPCP, application of topical glucocorticoids, or phototherapy (5). In most cases, repigmentation may occur with treatment, but complete recovery is uncommon (1). Recently, Ganzetti et al. (8) reported a case of DPCP-induced vitiligo in a patient with AA, which was treated successfully with phototherapy. In this case, NB-UVB therapy was effective treatment for patient's vitiligo and AA. However, in our case, according to patient's disease course, DPCP therapy appeared to induce hair re-growth, and NB-UVB therapy induced repigmentation.

In conclusion, because the development of vitiligo by DPCP is currently unpredictable, and depigmentation

may be permanent, it is important to inform all patients of this potential side-effect before starting treatment. This report presents two cases of DPCP-induced vitiligo, both of which showed excellent responses to NB-UVB treatment.

REFERENCES

1. Pires MC, Martins JM, Montealegre F, Gatti FR. Vitiligo after diphenylcyclopropenone for alopecia areata. *Dermatol Res Pract* 2010; 2010: 171265.
2. Sotiriadis D, Patsatsi A, Lazaridou E, Kastanis A, Vakirlis E, Chrysomallis F. Topical immunotherapy with diphenylcyclopropenone in the treatment of chronic extensive alopecia areata. *Clin Exp Dermatol* 2007; 32: 48–51.
3. Pan JY, Theng C, Lee J, Goh BK. Vitiligo as an adverse reaction to topical diphenylcyclopropenone. *Ann Acad Med Singapore* 2009; 38: 276–277.
4. Hatzis J, Gourgoutou K, Tosca A, Varelzidis A, Stratigos J. Vitiligo as a reaction to topical treatment with diphenylcyclopropenone. *Dermatologica* 1988; 177: 146–148.
5. Henderson CA, Ilchyshyn A. Vitiligo complicating diphenylcyclopropenone sensitization therapy for alopecia universalis. *Br J Dermatol* 1995; 133: 496–497.
6. Duhra P, Foulds IS. Persistent vitiligo induced by diphenylcyclopropenone. *Br J Dermatol* 1990; 123: 415–416.
7. Orecchia G, Stock J. Diphenylcyclopropenone: an important agent known to cause depigmentation. *Dermatology* 1999; 199: 198.
8. Ganzetti G, Simonetti O, Campanati A, Giuliadori K, Offidani A. Phototherapy as a useful therapeutic option in the treatment of diphenylcyclopropenone-induced vitiligo. *Acta Derm Venereol* 2010; 90: 642–643.