

QUIZ SECTION

A Brownish-grey Plaque with Ulceration on the Nasolabial Area: A Quiz

Yuichi Yoshida¹, Tatsushi Shiomi^{1,2}, Masahisa Shindo¹, Yoshiko Suyama³, Bin Nakayama³ and Osamu Yamamoto¹

¹Division of Dermatology, Department of Medicine of Sensory and Motor Organs, ²Department of Organ Pathology, and ³Division of Plastic Surgery, Faculty of Medicine, Tottori University, 86 Nishi-cho, Yonago-shi, Tottori 683-8503, Japan. E-mail: yxy@grape.med.tottori-u.ac.jp

A 57-year-old Japanese man presented with a 10-year history of a plaque on his face. The lesion had gradually increased in volume. Physical examination revealed a brownish-grey plaque, approximately 5 × 5 cm in size, with ulceration on the right nasolabial area (Fig. 1a). Dermoscopy showed a milky-red area with some milia-like cysts and dilated vessels on the surface (not shown). Histopathological examination revealed a poorly circumscribed tumour invading deeply into the dermis

and subcutis. Tumour nests composed of atypical basaloid cells were embedded in a desmoplastic stroma. Some keratinous cysts and cystic glands were seen in the mid-dermis. Small ductal or glandular structures were also seen in the deep dermis (Fig. 1 b, c). Immunohistochemically, most of tumour cells were positive for carcinoembryonic antigen (CEA).

What is your diagnosis? See next page for answer.

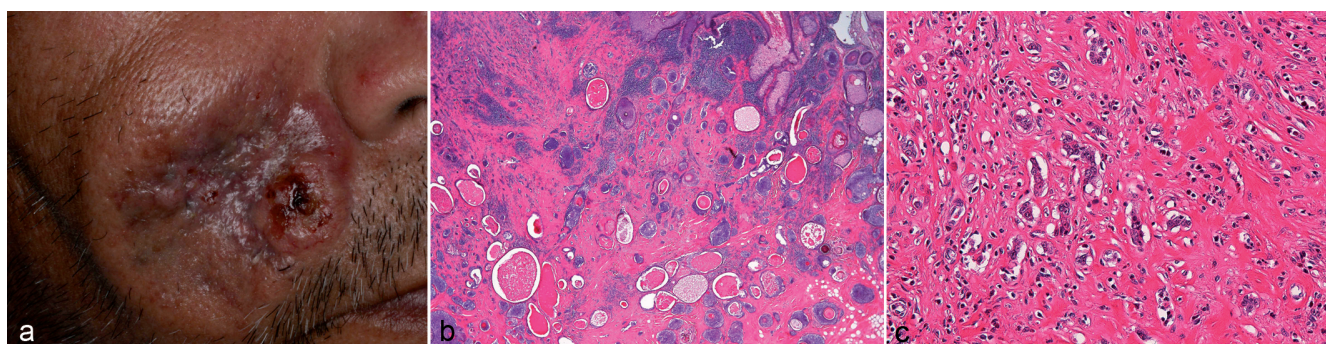


Fig. 1. (a) A brownish-grey plaque with ulceration located on the right upper cutaneous lip/cheek junction. (b) Tumour nests of atypical basaloid cells were embedded in a desmoplastic stroma. Some keratinous cysts and cystic glands were seen in the mid-dermis. (c) Small ductal or glandular structures were seen in the deep dermis.

doi: 10.2340/00015555-1172

ANSWERS TO QUIZ

A Brownish-grey Plaque with Ulceration on the Naso-labial Area: Comment

Acta Derm Venereol 2012; 92: 109–112 (contd).

Diagnosis: **Microcystic adnexal carcinoma**

Microcystic adnexal carcinoma (MAC) is a rare cutaneous neoplasm, first described by Goldstein et al. in 1982 (1). Clinically, the tumour presents as a flesh-coloured indurated nodule or plaque that is most commonly seen on the skin around the lip (2). Although metastasis is extremely rare, the local recurrence rate is relatively high (3). Therefore, a long-term careful follow-up is necessary after excision. It has been reported that Mohs micrographic surgery is useful for treatment (4). Histopathologically, MAC is characterized by a superficial component of keratinous cysts as well as by a component of small strands of cells in the deep dermis within a hyalinized stroma.

Differential diagnosis mainly includes sclerosing/infiltrative basal cell carcinoma and desmoplastic trichoepithelioma. However, it is sometimes difficult to make a correct diagnosis (4). Although there is no specific tumour marker for MAC, a combination of immunohistochemical stains, such as CEA, epithelial membrane antigen, some cytokeratins and Ki-67, may be helpful for diagnosis (5). In most cases of MAC, tumour cells with ductal structures are positive for CEA and the

level of Ki-67 expression is usually low. In the present case, many tumour cells were positive for CEA and some tumour cells were positive for epithelial membrane antigen. In addition, less than 5% of the tumour cells were Ki-67-positive.

It is important for dermatologists to include MAC in the differential diagnosis of skin tumours on the face.

REFERENCES

1. Goldstein DJ, Barr RJ, Santa Cruz DJ. Microcystic adnexal carcinoma: a distinct clinicopathologic entity. *Cancer* 1982; 50: 566–572.
2. Chiller K, Passaro D, Scheuller M, Singer M, McCalmont T, Grekin RC. Microcystic adnexal carcinoma: forty-eight cases, their treatment, and their outcome. *Arch Dermatol* 2000; 136: 1355–1359.
3. Ohtsuka H, Nagamatsu S. Microcystic adnexal carcinoma: a review of 51 Japanese patients. *Dermatology* 2002; 204: 190–193.
4. Leibovitch I, Huilgol SC, Selva D, Lun K, Richards S, Paver R. Microcystic adnexal carcinoma: treatment with Mohs micrographic surgery. *J Am Acad Dermatol* 2005; 52: 295–300.
5. Smith KJ, Williams J, Corbett D, Skelton H. Microcystic adnexal carcinoma: an immunohistochemical study including markers of proliferation and apoptosis. *Am J Surg Pathol* 2001; 25: 464–471.