

## Bullous Dermolysis of the Newborn and Dystrophic Epidermolysis Bullosa Pruriginosa within the Same Family: Two Phenotypes Associated with a *COL7A1* Mutation

Kana Murase<sup>1</sup>, Hiroyuki Kanoh<sup>1</sup>, Norito Ishii<sup>2</sup>, Takashi Hashimoto<sup>2</sup>, Hajime Nakano<sup>3</sup>, Daisuke Sawamura<sup>3</sup> and Mariko Seishima<sup>1\*</sup>

Departments of Dermatology, <sup>1</sup>Gifu University Graduate School of Medicine, 1-1 Yanagido, Gifu City 501-1194, <sup>2</sup>Kurume University School of Medicine and Kurume University Institute of Cutaneous Cell Biology, Kurume, and <sup>3</sup>Hirosaki University School of Medicine, Hirosaki, Japan. \*E-mail: marikoseishima@yahoo.co.jp

Accepted March 16, 2011.

Bullous dermolysis of the newborn (BDN), first described by Hashimoto et al. (1), is a rare variant of dystrophic epidermolysis bullosa (DEB), the latter being caused by mutations in the *COL7A1* gene encoding collagen VII. BDN is characterized by blister formation soon after birth, followed by rapid healing with or without scars. According to the third international consensus meeting on diagnosis and classification of epidermolysis bullosa in 2008 (2), BDN is characterized using electron microscopy (EM) by a separation of the dermal–epidermal junction below the lamina densa, and on immunofluorescence, by a granular pattern of type VII collagen within the epidermis. Other ultrastructural findings include electron-dense stellate bodies within the basal epidermis and reduced anchoring fibrils. Intracytoplasmic deposits of type VII collagen suggest a functional defect in keratinocyte transport of type VII collagen to the extracellular space (3).

The p.G2242E mutation of *COL7A1* is known to be associated with dominant DEB pruriginosa (4), with the p.G2242R (substitution of glycine with arginine at the same amino acid position) also reported in some cases (5). We report here an infant and his mother, both carrying the p.G2242E mutation, but presenting with different symptoms.

### CASE REPORT

A 3-week-old male Japanese infant, who had no known family history of blistering disorders, developed recurrent erosions and blisters on the lower legs and dorsal aspects of the hands and feet, which were noticed soon after delivery (Fig. 1a). No oral lesions or nail changes were observed. The infant was born at 40 weeks and 6 days gestation and weighed 3,158 g at birth. The lesions healed without scarring, while milia were present on the extremities. No further bullae developed after 6 months of age, at least for 11 months from birth.

The 29-year-old mother, however, presented differently. She had an absence of bullae during her infancy. From the age of 12 years, prurigo-like nodules with severe itching were observed on the extremities and dorsal aspects of her hands and feet (Fig. 1b and c), accompanied by dystrophy of several nails. As in her infant, no lesions were observed in the oral cavity. Laboratory examination revealed no antibodies to desmogleins 1 and 3, or bullous pemphigoid antigen 180 in either patient. The mother had a normal serum IgE level. Biopsies were obtained from perilesional skin of the dorsal surface of the foot of the infant and lesional skin from the lower leg of the mother. Histopathological examination revealed subepidermal bullae in both cases, and marked acanthosis in the biopsy specimen from the mother (Fig. 1d and e). On immunofluorescence using monoclonal antibody to type VII collagen (LH7.2), type VII

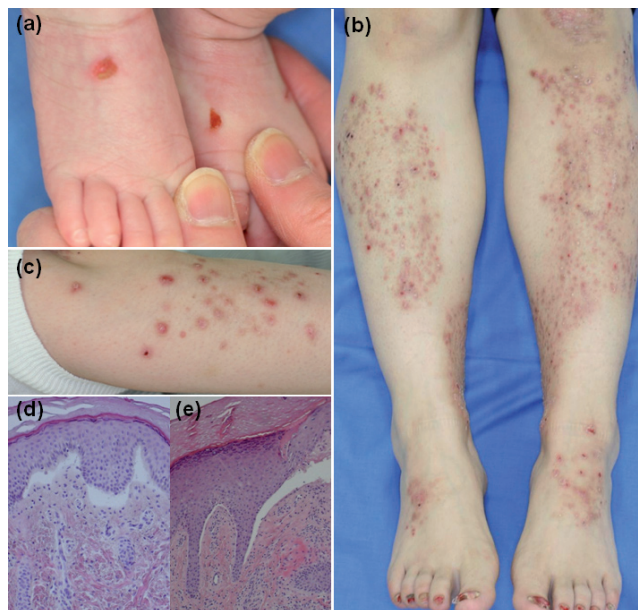


Fig. 1. Clinical features and histopathology in the infant and his mother. (a) Blisters and erosions on the infant's extremities. (b, c) Multiple itchy nodules on the extremities of the mother. (d, e) Subepidermal bullae visible by haematoxylin and eosin staining in biopsies from (d) the infant and (e) his mother (original magnification,  $\times 200$ ).

collagen expression was found to be slightly reduced in the basement membrane zone in both specimens, with granular deposition within the epidermis of the infant (Fig. 2a), but not in that of the mother. EM revealed reduced anchoring fibrils and electron-dense stellate bodies in basal and suprabasal keratinocytes in the infant (Fig. 2c). In contrast, although blister formation below the lamina densa and reduced anchoring fibrils were observed in the mother, electron-dense stellate bodies were not detected. Mutation analysis by polymerase chain reaction (PCR) amplification using primer pairs spanning all 118 exons of *COL7A1* revealed a heterozygous G-to-A substitution at position 6725 of exon 85 in the triple helical domain of type VII collagen. This mutation causes a replacement of glycine by glutamine (p.G2242E). The p.G2242E mutation was detected in the genomic DNAs from both the infant and his mother, but was absent in 100 ethnically matched healthy controls. Based on the above findings, a diagnosis of BDN was made in the infant, and dominant DEB pruriginosa in his mother.

### DISCUSSION

To date, 12 different *COL7A1* mutations, with either autosomal dominant or autosomal recessive inheritance (6, 7), have been reported in seven BDN families, including the cases reported here. Of these, p.G1522E

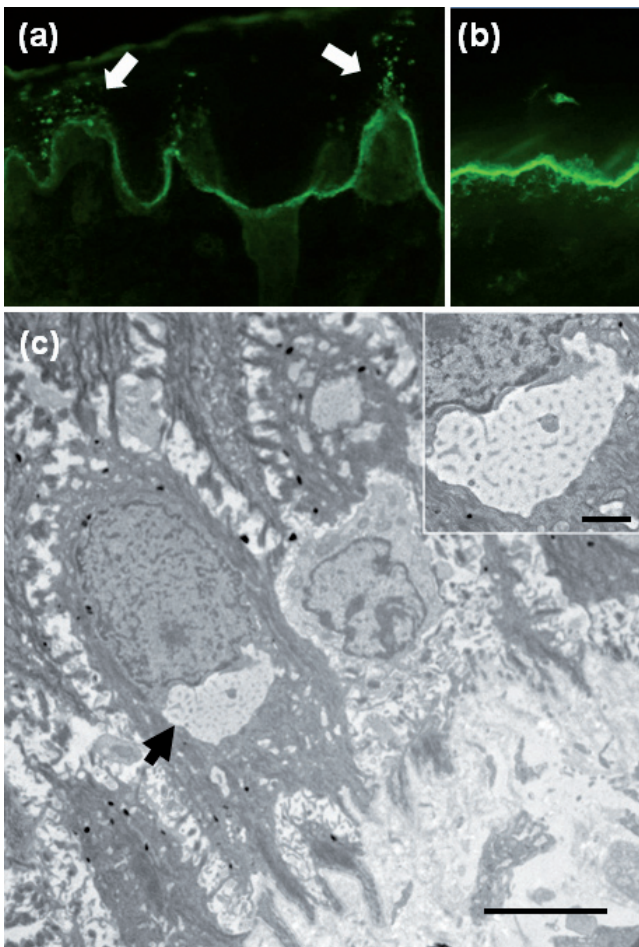


Fig. 2. Immunofluorescence with anti-type VII collagen antibody (LH7.2) (a, b: original magnification,  $\times 200$ ) and transmission electron microscopic findings in (a) the infant's perilesional skin. Reduced type VII collagen in the basement membrane zone with granular deposition within the epidermis (arrow). (b) Healthy control. (c) Transmission electron micrograph revealing a perinuclear stellate body (also shown in the inset) in a basal keratinocyte (bar = 5  $\mu\text{m}$ ; inset, bar = 1  $\mu\text{m}$ ).

and p.G2242E have also been reported in patients with DEB pruriginosa (4, 8, 9). The latter has been identified in a case of dominant DEB pruriginosa (4), a subtype of DEB associated with itchy papules, but not reported previously in BDN. In this study, we characterized a mother and child who shared a p.G2242E mutation, but presented with different clinical features: the infant with BDN and the mother with dominant DEB pruriginosa. In the mother, bullae during infancy could not be proven from her parents' recollection and photographs taken in infancy. The aetiology and underlying molecular mechanisms of these two different clinical features are unclear. Considering the mild nature and limited extent of bulla formation observed in the infant,

the possibility that the mother had symptoms of BDN in infancy cannot be excluded. Moreover, it is also possible that the child with BDN may develop some further clinical manifestations, such as nail dystrophy or DEB pruriginosa, in future. We believe that the skin lesions in dominant DEB pruriginosa may be induced by scratching in a sub-set of individuals with underlying *COL7A1* mutations, although the precise trigger(s) for this phenotype is/are not known and intra-familial variability in several cases of DEB is well-established. Long-term follow-up of more patients with BDN will provide further insight into the natural history of this disorder, the spectrum of persistent abnormalities and the implications for genotype-phenotype correlation.

## REFERENCES

1. Hashimoto K, Matsumoto M, Iacobelli D. Transient bullous dermolysis of the newborn. *Arch Dermatol* 1985; 121: 1429–1438.
2. Fine JD, Eady RA, Bauer EA, Bauer JW, Bruckner-Tuderman L, Heagerty A, et al. The classification of inherited epidermolysis bullosa (EB): report of the third international consensus meeting on diagnosis and classification of EB. *J Am Acad Dermatol* 2008; 58: 931–950.
3. Fine JD, Horiguchi Y, Stein DH, Esterly NB, Leigh IM. Intraepidermal type VII collagen. Evidence for abnormal intracytoplasmic processing of a major basement membrane protein in rare patients with dominant and possibly localized recessive forms of dystrophic epidermolysis bullosa. *J Am Acad Dermatol* 1990; 22: 188–195.
4. Tamai K, Murai T, Mayama M, Nomura K, Sawamura D, Hanada K, et al. Epidermolysis bullosa (EB) pruriginosa: electron microscopic study and specific mutations in the type VII collagen gene. *J Dermatol* 1998; 25: 488.
5. Lee JY, Pulkkinen L, Liu HS, Chen YF, Uitto J. A glycine-to-arginine substitution in the triple-helical domain of type VII collagen in a family with dominant dystrophic epidermolysis bullosa pruriginosa. *J Invest Dermatol* 1997; 108: 947–949.
6. Oh SW, Lee JS, Kim MY, Kim SC. *COL7A1* mutational analysis in Korean patients with dystrophic epidermolysis bullosa. *Br J Dermatol* 2007; 157: 1260–1264.
7. Hashikawa K, Hamada T, Ishii N, Fukuda S, Kuroki R, Nakama T, et al. The compound heterozygote for new/recurrent *COL7A1* mutations in a Japanese patient with bullous dermolysis of the newborn. *J Dermatol Sci* 2009; 56: 66–68.
8. McGrath JA, Schofield OM, Eady RA. Epidermolysis bullosa pruriginosa: dystrophic epidermolysis bullosa with distinctive clinicopathological features. *Br J Dermatol* 1994; 130: 617–625.
9. Whittock NV, Ashton GH, Mohammadi R, Mellerio JE, Mathew CG, Abbs SJ, et al. Comparative mutation detection screening of the type VII collagen gene (*COL7A1*) using the protein truncation test, fluorescent chemical cleavage of mismatch, and conformation sensitive gel electrophoresis. *J Invest Dermatol* 1999; 113: 673–686.