

CLINICAL REPORT

Tinea Capitis and Tinea Corporis with a Severe Inflammatory Response due to *Trichophyton tonsurans*

Anita HRYNCEWICZ-GWÓZDŹ¹, Vera BECK-JENDROSCHECK², Jochen BRASCH², Katarzyna KALINOWSKA¹ and Tomasz JAGIELSKI³

¹Department of Dermatology, Venereology and Allergology, Wrocław Medical University, Wrocław, Poland, ²Department of Dermatology, Venereology and Allergy, University Hospitals of Schleswig-Holstein, Campus Kiel, Kiel, Germany, and ³Department of Applied Microbiology, Institute of Microbiology, Faculty of Biology, University of Warsaw, Warsaw, Poland

***Trichophyton tonsurans* is an anthropophilic dermatophyte, with a worldwide distribution, although its prevalence varies considerably between different geographical regions. Whereas in North America infections due to this fungus are exceptionally common, on the European continent they appear relatively seldom. Although *T. tonsurans* is primarily associated with tinea capitis, it can also be the cause of tinea corporis and tinea unguium. The course of infection is usually only mildly symptomatic. We describe here two cases of urease-positive *T. tonsurans* infections with atypically extensive cutaneous lesions and severe inflammatory responses. Key words: *Trichophyton tonsurans*; dermatophyte; tinea capitis; tinea corporis.**

(Accepted February 18, 2011.)

Acta Derm Venereol 2011; 91: 708–710.

Anita Hryniewicz-Gwóźdź, Department of Dermatology, Venereology and Allergology, Wrocław Medical University, Wrocław. 1, Chałubińskiego Str., PL-50-368 Wrocław, Poland. E-mail: anhryn@derm.am.wroc.pl

Trichophyton tonsurans is an important anthropophilic dermatophyte that causes an endothrix type of hair invasion. The fungus is currently the leading aetiological agent of tinea capitis in North America (1, 2). In Europe, the frequency of infections due to *T. tonsurans* is considerably lower, albeit increasing (3–5). In Poland, the species accounts for less than 10% of all dermatophytoses reported each year (6). Although *T. tonsurans* is primarily associated with tinea capitis, it can also be the cause of tinea corporis and tinea unguium. Several cases of epidemic infection with *T. tonsurans*, presenting as tinea capitis and/or tinea corporis, have been reported recently in different countries among wrestling and judo participants (7–10). Tinea capitis caused by *T. tonsurans* may present with a variety of clinical findings, including seborrhoeic dermatitis-like scaling, “black-dot” alopecia (with fracture of the hair at the skin surface), and, very rarely, a kerion type of inflammatory tinea capitis (11). Cases of tinea corporis have been observed mainly among members of sporting clubs. Such cases presented with

exfoliating erythematous lesions, resembling nummular eczema (7).

We describe here two cases of tinea capitis and tinea corporis, both caused by *T. tonsurans*, and both with unusual clinical presentations.

CASE REPORTS

Case 1

A 5-year-old girl was admitted to the Wrocław outpatient dermatology department because of exacerbated cutaneous lesions. She had no prior history of any dermatological disease or condition. There was no history of fungal infections in other family members or children being in contact with the girl. Within a short time a severe kerion had developed in the temporoparietal area of the child’s scalp. The condition was characterized by an intense oedema of the skin, erythema, hair loss, and superficial pustules. After approximately one month, acute infiltrative inflammatory lesions could be observed on both cheeks, involving scaling and pustule formation (Fig. 1). In the following month the lesions spread to the chest, abdomen, and extremities, leading to disseminated erythematous papular eruptions. The cutaneous lesions were not associated with any general symptoms. The body temperature remained normal, as did the results of the laboratory examinations of blood and urine samples. A bacteriological culture from pustule content was negative. Skin scrapings collected from the borderline of all lesions (located on the scalp, cheeks, chest, abdomen, and extremities) and a hair plucked at the periphery of the hair loss area were processed for mycological study. Direct

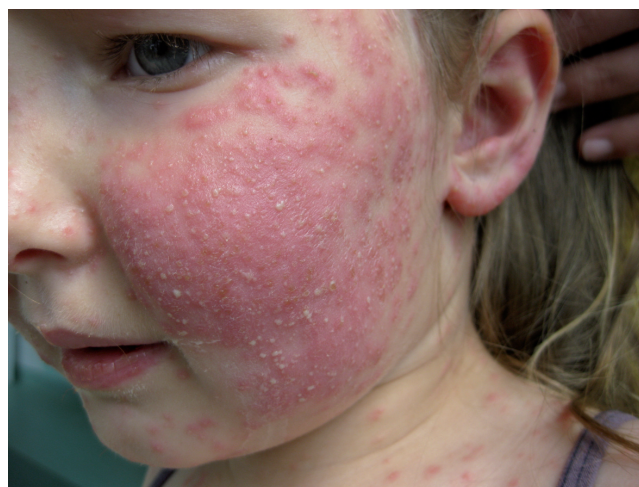

Fig. 1. Case 1. Acute inflammation with pustules on the face.

microscopic examination of the scales from the scalp and cheek lesions revealed the presence of hyphae, while in the hair an endothrix invasion was evidenced. Cultures on Sabouraud's agar yielded white and powdery colonies. Microscopy evidenced the presence of micro- and macro-conidia corresponding to *T. tonsurans*; however, spiral hyphae unusual for this species were also observed (Fig. 2). Furthermore, an enhanced growth on thiamine-containing agar, a positive urease activity test, and a negative hair perforation test matched the diagnostic criteria for *T. tonsurans*. The identification of the species performed by conventional mycological examination was confirmed by means of genotypic analysis. PCR analysis for dermatophytes was performed with a HotStarTaq Plus Master Kit (Quiagen, Quiagen GmbH, Hilden, Germany) according to the manufacturer's instructions. The following primers were used: forward "panDerm1" 5' GAA GAA GAT TGT CGT TTG CAT CGT CTC 3', reversed "panDerm2" 5' CTC GAG GTC AAAAGC ACG CCA GAG 3' (12). The weight of amplified product was 366 bp. Positive controls (*T. tonsurans* (366 bp), *T. mentagrophytes* (366 bp)) and a negative control were included (Fig. 3). Furthermore, an additional PCR was performed with primers specific for *T. tonsurans*: forward "tonsF1" 5' CGG AGG CCG GCC CCCCAG 3', reversed "tonsR1" 5' CTC GAG GTC AAA AGC ACG CCA GAG 3' (13). Its amplified product weight was identical to that of a positive control with *T. tonsurans* (173 bp) (Fig. 4).

Samples collected from lesions located on the trunk and extremities were negative for fungal infection.

Treatment with oral terbinafine (125 mg/day) for 8 weeks resulted in complete resolution of the lesions.

Case 2

The second case was a 23-year-old male with no history of chronic illness or medication. The patient had been a member of a wrestling club for 2 years, but had not exercised during the last 3 years. The initial skin lesions (two discrete erythematous patches) were localized in the right temporal area of the scalp. Without any mycological diagnostics, topical antifungal treatment had been given to the patient, resulting in a substantial improvement in the condition. One month later, however, the patient relapsed with several skin eruptions that first occurred in the temporal region as well as on the forearms, and then spread to the trunk and extremities. The patient was misdiagnosed as having an allergic reaction and was treated with corticosteroids administered topically and systemically. After 7 months from the onset of the disease he presented with numerous extensive erythematous and slightly scaling lesions located on the trunk and limbs. The lesions consisted of concentric erythematous rings forming a grain-like pattern. Scaling of the scalp and a black-dot alopecia were also observed. Apart from the skin lesions, the

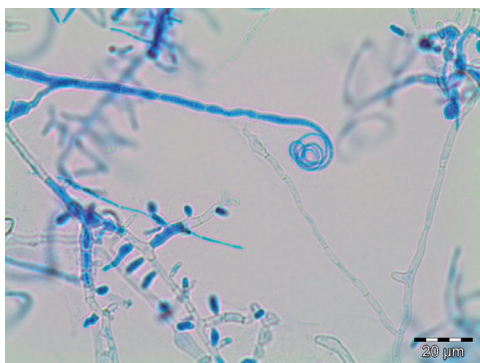


Fig. 2. Case 1. *T. tonsurans*. Microscopic view with typical globose and elongated microconidia arising at right angles to hyphae and helical structure (spiral).

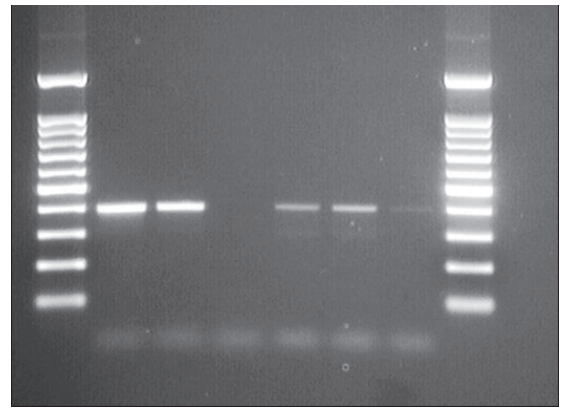


Fig. 3. PCR result for dermatophytes with amplified products weight 366 bp. Lane 1=100 bp DNA ladder, lane 2=positive control *T. tonsurans*, lane 3=positive control *T. mentagrophytes*, lane 4=negative control, lane 5=case 1 strain, lane 6=case 2 strain, lane 7=positive control *T. terrestre*, lane 8=100 bp DNA ladder.

general condition of the patient was good. The results of blood and urine tests were normal.

Scrapings from the lesions of the scalp and trunk showed hyphae in KOH-mounts and a dermatophyte was grown in the cultures. The same mycological and genetic tests were performed as in case 1, and *T. tonsurans* was identified. For treatment, oral terbinafine at a dose of 250 mg/day and topical treatment with clotrimazole was administered. A complete cure was achieved within 4 weeks.

DISCUSSION

T. tonsurans is a ubiquitous fungus. It is particularly common in the USA being responsible for as much as 21.1–44.9% of all dermatophyte infections (1, 2). Of all European countries only in the UK and Croatia the infections are not very rare (14–16). *T. tonsurans* predominantly causes tinea capitis. In the UK and USA 50–90% (15) and 95.8% (17) of tinea capitis were infections with *T. tonsurans*, while in continental Europe, only 3–5% (18, 19).

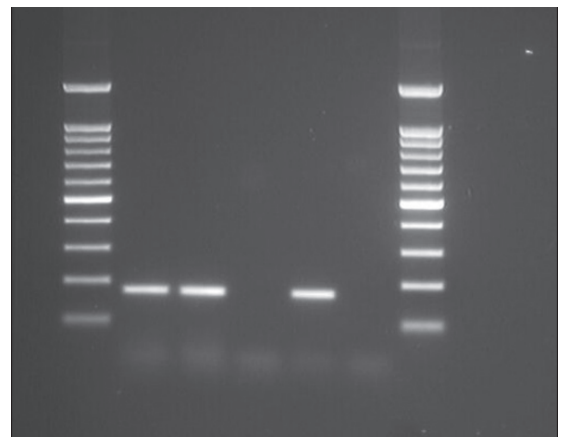


Fig. 4. PCR result for *T. tonsurans* with amplified products weight 173 bp. Lane 1=100 bp DNA ladder, lane 2=case 1 strain, lane 3=case 2 strain, lane 4=control *T. terrestre*, lane 5=positive control *T. tonsurans*, lane 6=negative control, lane 7=100 bp DNA ladder.

Cases of atypical courses of *T. tonsurans* infections have been reported: tinea corporis with an acute inflammatory reaction (20), folliculitis decalvans (21, 22), and Majocchi granulomas (23–25).

We report two cases of infection with *T. tonsurans* with severe inflammatory courses.

In the first case, a 5-year-old child, sterile papules scattered over the trunk and limbs were observed in addition to the tinea lesions on the scalp and face. Such a disseminated and intensely inflammatory eruption suggests a dermatophytid reaction. Interestingly the causative *T. tonsurans* strain showed an unusual microscopic morphology with spiral hyphae. In addition, in both cases *T. tonsurans* strains were positive in a urease test, while most of the fungi of this species are urease negative. It is possible that higher than usual enzymatic activity of *T. tonsurans* strains was the cause of the intensive inflammatory reaction.

Our second patient with an acute inflammatory skin reaction in the course of *T. tonsurans* infection, had been a wrestler in the past. The first skin symptoms appeared 2 years after quitting sport. In the literature some wrestlers have been described as asymptomatic carriers (9), in addition to *T. tonsurans* being cultured from wrestling mats (9, 26). Epidemic outbreaks of *T. tonsurans* infections among members of combat sports clubs have been reported (7–9) as well as in other populations, such as paediatric healthcare workers (27).

This report emphasizes that *T. tonsurans*, a dermatophyte that is still relatively uncommon in Europe, can give rise to infections with quite diverse clinical features, ranging from the carrier-state to severe tinea corporis with heavy inflammation.

REFERENCES

1. Welsh O, Welsh E, Ocampo-Candiani J, Gomez M, Vera-Cabrera L. Dermatophytoses in Monterrey, México. *Mycoses* 2006; 49: 119–123.
2. Weitzman I, Chin NX, Kunjukunju N, Della-Latta P. A survey of dermatophytes isolated from human patients in the United States from 1993 to 1995. *J Am Acad Dermatol* 1998; 39: 255–261.
3. Tietz HJ, Kunzelmann V, Schönian G. Changes in the fungal spectrum of dermatomycoses. *Mycoses* 1995; 38: 33–39.
4. Buchvald J, Simaljaková M. The occurrence of dermatophytes in Slovakia. *Mycoses* 1995; 38: 159–161.
5. Dolenc-Voljc M. Dermatophyte infections in the Ljubljana region, Slovenia, 1995–2002. *Mycoses* 2005; 48: 181–186.
6. Nowicki R. Dermatophytosis in the Gdańsk area, Poland: a 12-year survey. *Mycoses* 1996; 39: 399–402.
7. Hirose N, Sukanami M, Shiraki Y, Hiruma M, Ogawa H. Management and follow-up survey of *Trichophyton tonsurans* infection in a university judo club. *Mycoses* 2008; 51: 243–247.
8. Poisson DM, Rousseau D, Defo D, Estève E. Outbreak of tinea corporis gladiatorum, a fungal skin infection due to *Trichophyton tonsurans*, in a French high level judo team. *Euro Surveill* 2005; 10: 187–190.
9. Hedayati MT, Afshar P, Shokohi T, Aghili R. A study on tinea gladiatorum in young wrestlers and dermatophyte contamination of wrestling mats from Sari, Iran. *Br J Sports Med* 2007; 41: 332–334.
10. Brasch J, Rütther T, Harmsen D. *Trichophyton tonsurans* var. *sulfureum* subvar. *perforans* bei tinea gladiatorum. *Hautarzt* 1999; 50: 363–367.
11. Kane J, Summmerbell R, Sigler L, Krajden S, Land G. *Laboratory handbook of dermatophytes*. Belmont: Star Publishing Co., 1997.
12. Brillowska-Dabrowska A, Saunte DM, Arendrup MC. Five-hour diagnosis of dermatophyte nail infections with specific detection of *Trichophyton rubrum*. *J Clin Microbiol* 2007; 45: 1200–1204.
13. Yoshida E, Makimura K, Mirhendi H, Kaneko T, Hiruma M, Kasai T, et al. Rapid identification of *Trichophyton tonsurans* by specific PCR based on DNA sequences of nuclear ribosomal internal transcribed spacer (ITS) 1 region. *J Dermatol Sci* 2006; 42: 225–230.
14. Babić-Erceg A, Barisić Z, Erceg M, Babić A, Borzić E, Zoranić V, et al. Dermatophytoses in Split and Dalmatia, Croatia, 1996–2002. *Mycoses* 2004; 47: 297–299.
15. Fuller LC. Changing face of tinea capitis in Europe. *Curr Opin Infect Dis* 2009; 22: 115–118.
16. White JM, Higgins EM, Fuller LC. Screening for asymptomatic carriage of *Trichophyton tonsurans* in household contacts of patients with tinea capitis: results of 209 patients from South London. *J Eur Acad Dermatol Venereol* 2007; 21: 1061–1064.
17. Foster KW, Ghannoum MA, Elewski BE. Epidemiologic surveillance of cutaneous fungal infection in the United States from 1999 to 2002. *J Am Acad Dermatol* 2004; 50: 748–752.
18. Devliotou-Panagiotidou D, Koussidou-Eremondi T, Chaidemenos GC, Theodoridou M, Minas A. Tinea capitis in adults during 1981–95 in northern Greece. *Mycoses* 2001; 44: 398–400.
19. Cuétara MS, del Palacio A, Pereiro M, Amor E, Alvarez C, Noriega AR. Prevalence of undetected tinea capitis in a school survey in Spain. *Mycoses* 1997; 40: 131–137.
20. Ohno S, Tanabe H, Kawasaki M, Horiguchi Y. Tinea corporis with acute inflammation caused by *Trichophyton tonsurans*. *J Dermatol* 2008; 35: 590–593.
21. Baroni A, Ruocco E, Aiello FS, Faccenda F, Lo Schiavo A, Satriano RA, et al. Tinea capitis mimicking tufted hair folliculitis. *Clin Exp Dermatol* 2009; 34: 699–701.
22. Twersky JM, Sheth AP. Tinea capitis mimicking dissecting cellulitis: a distinct variant. *Int J Dermatol* 2005; 44: 412–414.
23. Rajpara V, Frankel S, Rogers C, Nouri K. *Trichophyton tonsurans* associated tinea corporis infection with the development of Majocchi's granuloma in a renal transplant patient. *J Drugs Dermatol* 2005; 4: 767–769.
24. Chen HH, Chiu HC. Facial Majocchi's granuloma caused by *Trichophyton tonsurans* in an immunocompetent patient. *Acta Derm Venereol* 2003; 83: 65–66.
25. Liao YH, Chu SH, Hsiao GH, Chou NK, Wang SS, Chiu HC. Majocchi's granuloma caused by *Trichophyton tonsurans* in a cardiac transplant recipient. *Br J Dermatol* 1999; 140: 1194–1196.
26. Ikit M, Ali Saracli M, Kurdak H, Turac-Bicer A, Yuksel T, Karakas M, et al. Clonal outbreak of *Trichophyton tonsurans* tinea capitis gladiatorum among wrestlers in Adana, Turkey. *Med Mycol* 2010; 48: 480–485.
27. Shroba J, Olson-Burgess C, Preuett B, Abdel-Rahman SM. A large outbreak of *Trichophyton tonsurans* among health care workers in a pediatric hospital. *Am J Infect Control* 2009; 37: 43–48.