

## Bosentan is Effective Against Digital Ulcerations and Hyperkeratosis in Systemic Sclerosis

Zsuzsanna Kurgyis<sup>1,2</sup>, Rita Varga<sup>2</sup>, Isabell Sick<sup>2</sup>, Martin Ulrich Lang<sup>2</sup>, Thomas Ruzicka<sup>2</sup> and Miklós Sárdy<sup>2\*</sup>

Departments of Dermatology and Allergology, <sup>1</sup>Faculty of Medicine, University of Szeged, Szeged, Hungary, and <sup>2</sup>Ludwig-Maximilian University, Frauenlobstr. 9–11, DE-80337 Munich, Germany. \*E-mail: miklos.sardy@med.uni-muenchen.de  
Accepted March 2, 2011.

Systemic sclerosis (SSc) is a chronic connective tissue disease of unknown aetiology that causes ischaemia due to widespread microvascular damage and excessive deposition of collagen in the skin and internal organs. SSc is often associated with Raynaud's phenomenon, and together these can lead to digital ulcers (DUs) and hyperkeratosis (1). Bosentan is a dual endothelin receptor antagonist licensed for the management of pulmonary hypertension and the prevention of DUs in SSc. We report here a case in which remarkable remission of not only DUs, but also hyperkeratosis was achieved with long-term administration of bosentan.

### CASE REPORT

A 54-year-old woman with a history of SSc and Raynaud's phenomenon for 18 years presented with DUs, which had started 6 months previously and persisted. She had sclerodactyly with multiple, significantly hyperkeratotic, superficial ulcers on the right index and both middle fingers (Fig. 1). The systemic manifestations included oesophagus dysmotility, gastro-oesophageal reflux disease, mild pulmonary fibrosis (with a reduction in transfer factor for CO ( $T_{LCO}$ ) to 65% at first presentation and 45% at the end of the 3-year follow-up), and slight pulmonary hypertension without progression in the last 3 years (the mean pulmonary arterial pressure had been around 25 mmHg determined only by echocardiographic measurements). She was positive for antinuclear antibodies (titre > 1:10,240) without detectable auto-antigen specificity. In addition, she had essential arterial hypertension. Digital arterial pulse oscillography showed pathological pulse volume in the right index finger, which was irreversible upon intravenous administration of nitroglycerine. The patient was taking nitrendipine 20 mg once daily, lisi-

nopril 20 mg once daily, and clonidine 150 mg twice daily, without effect on the DUs. Intravenous iloprost (5 ng/kg body weight/min), administered additionally for 21 days, led to only temporary improvement. Oral bosentan (Tracleer®, Actelion Pharmaceuticals Deutschland Ltd., Freiburg, Germany) 62.5 mg once daily was subsequently introduced instead of iloprost. When the dose was increased to 62.5 mg twice daily, the patient developed dyspnoea, therefore the reduction in the dose to 62.5 mg once daily was required. Six weeks later, the dose could be elevated to 62.5 mg twice daily. Four months after initiation of continuous bosentan therapy, the ulcers healed completely, and the hyperkeratoses disappeared almost completely without any local therapy (Fig. 2). During the 3-year follow-up, the patient was taking bosentan uninterruptedly, and had insignificant relapses five times, with a single erosion of <2 mm diameter on the right index finger. She developed one ulcer of 1 cm diameter on the right small finger, which healed within 3 weeks after increasing the dose of bosentan to 125 mg twice daily. During the remaining time she was free of DUs, with only scars under mild hyperkeratoses. The duration and frequency of episodes of Raynaud's syndrome was significantly reduced. No major side-effects of bosentan were recorded.

### DISCUSSION

DUs, which are present in approximately 25% of patients with SSc in Germany (1), are very painful and may have enormous negative impact (2). Amanzi et al. (3) classified DUs as follows: pure DUs (48.6% of 1,614 analysed lesions), and DUs derived from pitting scars (44.1%), calcinosis (6.8%), or gangrene (0.8%). Some of the DUs were hidden behind hyperkeratosis (3). According to this classification, our patient had

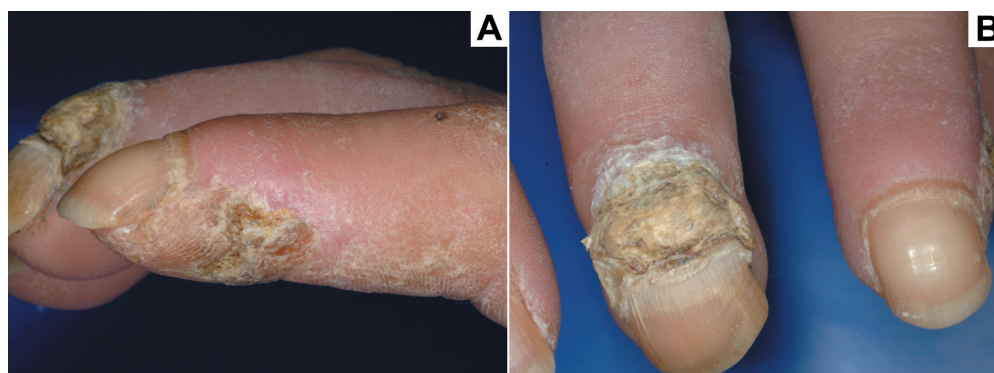

Fig. 1. Severe hyperkeratosis covering ulcers on the proximal nail fold of (A) the right middle and (B) the index fingers.

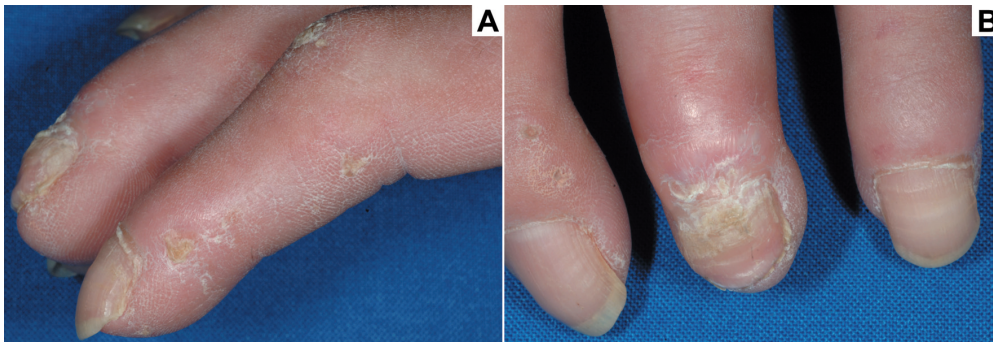


Fig. 2. Almost complete recovery after 4 months of bosentan therapy (62.5 mg twice a day).

three pure DUs with prominent hyperkeratosis, together with hyperkeratoses without DUs. To our knowledge, description of digital hyperkeratoses and their therapeutic response in SSc has not been thoroughly documented in the literature, although several case reports and studies describe the response of DUs to bosentan.

For the treatment of active DUs in SSc, calcium-channel blockers, phosphodiesterase-5 inhibitors, and cyclic use of intravenous prostacyclin analogues have been suggested (4). Supportive therapies, such as keeping the whole body warm, or antiseptics are also important. Bosentan is licensed for prevention rather than therapy of DUs, based on two randomized, double-blind, placebo-controlled trials; RAPIDS-1 and RAPIDS-2 (5, 6). However, in some patients (7–9), in a retrospective study (10) and three prospective, open-label studies (2, 11, 12), it also had a curative effect. These clinical observations confirm the hypothesized role of endothelin in the pathogenesis of DUs. The effect of bosentan on DUs is often reported for a shorter follow-up period (9, 11, 13). To our knowledge, the present paper includes the longest follow-up of case reports published thus far.

In summary, long-term bosentan administration can efficiently prevent ischaemic complications in SSc, including DUs, pain and secondary infections. It may also delay the progression of SSc, thus reducing skin fibrosis (11), and suggesting a possible future role in the prevention of severe sclerodactylia with dermatogenic contractures. The prevention of episodes of Raynaud's syndrome is also among the potential future indications (9).

Digital hyperkeratoses are a rare, but typical finding in SSc, which can be isolated or associate with ulcers or pitting scars. We speculate that they may result from ischaemia, as they can accompany ischaemic lesions and regress on vasoactive therapies. In the future, it may be worth administering bosentan when only hyperkeratoses are present, thus preventing DUs. This report draws attention to these disregarded, but perhaps important, signs of digital ischaemia in SSc.

#### ACKNOWLEDGEMENT

*Conflict of interest:* MS and RV received travel grants from Actelion Pharmaceuticals Ltd.

#### REFERENCES

- Hunzelmann N, Genth E, Krieg T, Lehmacher W, Melchers I, Meurer M, et al. The registry of the German Network for Systemic Scleroderma: frequency of disease subsets and patterns of organ involvement. *Rheumatology (Oxford)* 2008; 47: 1185–1192.
- Tsifetaki N, Botzoris V, Alamanos Y, Argyriou E, Zioga A, Drosos AA. Bosentan for digital ulcers in patients with systemic sclerosis: a prospective 3-year followup study. *J Rheumatol* 2009; 36: 1550–1552.
- Amanzi L, Braschi F, Fiori G, Galluccio F, Miniati I, Guiducci S, et al. Digital ulcers in scleroderma: staging, characteristics and sub-setting through observation of 1614 digital lesions. *Rheumatology (Oxford)* 2010; 49: 1374–1382.
- Schiopu E, Impens AJ, Phillips K. Digital ischemia in scleroderma spectrum of diseases. *Int J Rheumatol* 2010; 2010. pii: 92374.
- Korn JH, Mayes M, Matucci-Cerinic M, Rainisio M, Pope J, Hachulla E, et al. Digital ulcers in systemic sclerosis: prevention by treatment with bosentan, an oral endothelin receptor antagonist. *Arthritis Rheum* 2004; 50: 3985–3993.
- Matucci-Cerinic M, Denton CP, Furst DE, Mayes MD, Hsu VM, Carpentier P, et al. Bosentan treatment of digital ulcers related to systemic sclerosis: results from the RAPIDS-2 randomised, double-blind, placebo-controlled trial. *Ann Rheum Dis* 2011; 70: 32–38.
- Chamaillard M, Heliot-Hosten I, Constans J, Taïeb A. Bosentan as a rescue therapy in scleroderma refractory digital ulcers. *Arch Dermatol* 2007; 143: 125–126.
- Humbert M, Cabane J. Successful treatment of systemic sclerosis digital ulcers and pulmonary arterial hypertension with endothelin receptor antagonist bosentan. *Rheumatology (Oxford)* 2003; 42: 191–193.
- Ramos-Casals M, Brito-Zerón P, Nardi N, Claver G, Risco G, Parraga FD, et al. Successful treatment of severe Raynaud's phenomenon with bosentan in four patients with systemic sclerosis. *Rheumatology (Oxford)* 2004; 43: 1454–1456.
- Launay D, Diot E, Pasquier E, Mouthon L, Boullanger N, Fain O, et al. Bosentan for treatment of active digital ulcers in patients with systemic sclerosis (9 cases). *Presse Med* 2006; 35: 587–592.
- Kuhn A, Haust M, Ruland V, Weber R, Verde P, Felder G, et al. Effect of bosentan on skin fibrosis in patients with systemic sclerosis: a prospective, open-label, non-comparative trial. *Rheumatology (Oxford)* 2010; 49: 1336–1345.
- Funauchi M, Kishimoto K, Shimazu H, Nagare Y, Hino S, Yano T, et al. Effects of bosentan on the skin lesions: an observational study from a single center in Japan. *Rheumatol Int* 2009; 29: 769–775.
- Snyder MJ, Jacobs MR, Grau RG, Wilkes DS, Knox KS. Resolution of severe digital ulceration during a course of Bosentan therapy. *Ann Intern Med* 2005; 142: 802–803.