

## Onychomycosis: First Case Due to *Aspergillus nomius*

Mirca Zotti<sup>1</sup>, Marco Machetti<sup>1</sup>, Agostino Persi<sup>2</sup>, Gianfranco Barabino<sup>3</sup> and Aurora Parodi<sup>2</sup>

<sup>1</sup>Mycology Laboratory, Department for Territory and its Resources Study, Polo Botanico "Hanbury", <sup>2</sup>Department of Endocrinology and Medical Sciences, University of Genoa and <sup>3</sup>UO Department of Social Dermatology, San Martino Hospital, Genoa, Italy. E-mail: milla@klatu.com.dist.unige.it  
Accepted January 20, 2011.

Onychomycosis accounts for >50% of all nail disorders (1) and non-dermatophyte fungi (NDF) cases are increasing, accounting for 2–22% of all cases of onychomycosis (1, 2).

The most frequent NDF are *Aspergillus*, *Fusarium*, *Acremonium* and *Scopulariopsis*, which have high variable incidence depending on the population and geographical area studied (1–4).

In addition, due to an increasing diagnostic effort, in recent years more cases of *Aspergillus* onychomycosis have been identified and several *Aspergillus* species that have never, or rarely, been described previously as causes of onychomycosis, are now identified as nail infection agents (5–8).

We report here a case of onychomycosis due to *Aspergillus nomius* (1–5), to our knowledge a species that has not been described previously as an agent of nail infections.

### CASE REPORT

In 2006, a 53-year-old woman presented with a lesion in her right toenail suggestive for onychomycosis. The lesion affected approximately three-quarters of the nail plate, with a subungual hyperkeratosis that caused nail colour alteration and uneven surface areas, while the nail plate remained substantially intact from a structural standpoint (Fig. 1). The patient was in good health, and no history of trauma or nail abnormalities prior to the lesion were reported. Although the patient had had nail lesions for several months, she had delayed consulting a dermatologist, since the other nails showed no abnormality. Only when she became concerned about the fact the lesions were expanding, she requested a skin examination.

Direct microscopy of nail fragments showed fungal filaments, and inoculation of nail portions on modified Sabouraud medium (1.5%

agar, 2% glucose, 1% neopeptone) yielded a yellow mould with the typical microscopic morphology of the genus *Aspergillus*.

According to the criteria provided by Gupta et al. (9), positive cultures from repeated nail examinations confirmed the diagnosis of non-dermatophytic onychomycosis. In detail, the patient was evaluated every 12 days for a total of three examinations. All direct microscopic examinations were positive, and multiple cultures revealed the presence of the same (and sole) non-dermatophytic mould.

For macro- and micromorphological identification purposes, the isolated strain was sub-cultured on Czapek Yeast Agar (CYA) 25°C/37°C, Malt Extract Agar (MEA), CYA20S and Czapek dox (CZ). Colony diameters at 7 days were: CYA25 45–55 mm; MEA 52–56 mm; CYA37 73–85 mm; CYA20S 57–62 mm; and CZ 40–50 mm.

In CYA 25°C colonies were pale, pastel-yellow, plane, usually velvety, with white vegetative mycelium and moderately abundant conidial structures; the colony reverse varied from pale orange to greyish orange; sclerotia were not observed (Fig. 2).

Microscopic character sizes are reported using three numbers corresponding to the minimum/average/maximum values, respectively, of a set of measurements. Conidial heads were usually biseriolate and columnar, stipes uncoloured, roughened, 450/600/1200 µm in length; vesicles spherical 20/30/50 µm. Conidia were globose to subglobose, echinulates 2.4/3.2/4.8 µm.

Morphological characteristics led to identification of the fungus as an *Aspergillus* belonging to the section Flavi, very closely related to *Aspergillus flavus*.

After identification, viable cultures were deposited at the Centraalbureau voor Schimmelcultures, Utrecht, The Netherlands (CBS 124572), and at the Mycotheca Universitatis Taurinensis, Turin, Italy (MUT 4191).

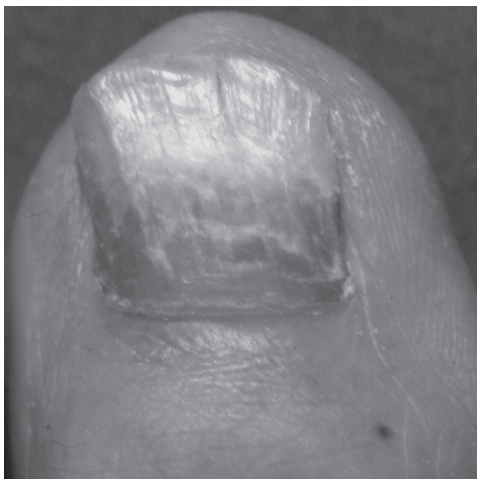


Fig. 1. Clinical features of the toenail lesion caused by *Aspergillus nomius*.

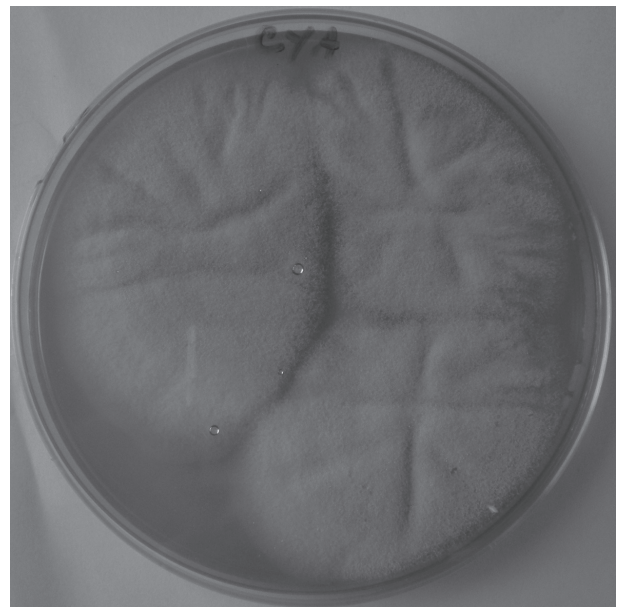


Fig. 2. Culture of the affected nail on Czapek Yeast Agar (CYA) at 25°C, showing *Aspergillus nomius*.

The sequence of the  $\beta$ -tubulin gene was obtained in order to definitely identify the fungus. Total fungal genomic DNA was isolated by means of Qiagen DNeasy Plant Mini Kit® (QIAGEN GmbH, Hilden, Germany) according to the manufacturer's instructions. Amplification of  $\beta$ -tubulin gene was performed using Bt2a and Bt2b primers (10). Polymerase chain reaction (PCR) was performed in a Biometra T3000 Thermocycler (Biometra biomedizinische Analytik GmbH, Goettingen Germany) programmed as follows: 1 cycle of 3 min denaturation at 95°C; 35 cycles of 40 s denaturation at 94°C, primer annealing 45 s at 55°C, primer extension 1 min at 72°C; Final 10 min elongation at 72°C. DNA sequencing was performed by DiNAMYCODE s.r.l. (DiNAMYCODE, Turin, Italy). The sequence of  $\beta$ -tubulin gene was deposited at GenBank (HM640219).

The patient was treated with both systemic and local therapy, in agreement with the literature and our previous clinical experience. Indeed, nail infections due to non-dermatophytic fungi often show a lower sensitivity to treatment and a clear tendency to recur (11).

It was therefore decided to treat the patient with oral itraconazole, since this therapy was considered the most appropriate, due to the spectrum of effectiveness and the administration mode being suitable to maintain good patient compliance. The patient was then prescribed pulsed therapy, which consisted of administration of itraconazole 400 mg daily for one week per month for a period of 4 months. At the same time it was decided to treat the lesion with amorolfine-based enamel, applied twice a week, following the manufacturer's instructions. The patient apparently improved after 6 months; however, in May 2010 she reported new nail lesions in the same nail, but she did not present for a new nail examination.

## DISCUSSION

Among the onychomycosis due to NDF, the genus *Aspergillus* accounts for 7–100% of cases (1, 3, 12). This genus has an emerging role as an agent of onychomycosis. The most frequently identified *Aspergillus* species causing nail infections, are: *A. niger*, *A. flavus*, *A. terreus*, *A. nidulans*, *A. fumigatus* and *A. versicolor* (2–4, 12, 13). Cases of nail infections with *A. candidus*, *A. ochraceus*, *A. persii*, *A. sclerotiorum*, *A. sydowii* and *A. tamarii* have been reported occasionally (5–8, 12, 13).

We reported here a case of onychomycosis due to *A. nomius*, a species described so far as a human pathogen in only one case of mycotic keratitis (14). This cosmopolitan and almost ubiquitous species, is usually isolated from different vegetal substrates and from soil (14, 15). *A. nomius* shows a high degree of morphological variability, and when only micro- and macroscopic features are taken into account, it is far more difficult to distinguish it from *A. flavus*.

Our *A. nomius* strain differs from *A. flavus* mainly in that, after 7 days at 25°C, on all media employed *A. nomius* always grew slower than *A. flavus*. In addition, after 7 days *A. nomius* colonies on CYA at 25°C were pastel yellow, without any green shading (as was seen for the *A. flavus*). However, the ultimate *A. nomius* identification was obtained using molecular analysis, an approach offering a wide variety of targets useful to

differentiate between *A. nomius* and other members of *Aspergillus* section *Flavi* (14).

In conclusion, this case report is the second clinical description of a human disease due to *A. nomius*, which apparently confirms the ability of fungi belonging to the genus *Aspergillus* to expand their habitat with increasing frequency by colonizing human tissues.

## ACKNOWLEDGEMENTS

The authors thank Janos Varga for his assistance in the confirmation of *A. nomius* species.

*The authors declare no conflict of interest.*

## REFERENCES

- Moreno G, Arenas R. Other fungi causing onychomycosis. *Clin Dermatol* 2010; 28: 160–163.
- Bonifaz A, Cruz-Agular P, Ponce RM. Onychomycosis by molds. *Eur J Dermatol* 2007; 17: 70–72.
- Aghamirian MR, Ghiasian SA. Onychomycosis in Iran: epidemiology, causative agents and clinical features. *Nippon Ishinkin Gakkai Zasshi* 2010; 51: 23–29.
- Chadeganipour M, Nilipour S, Ahmadi G. Study of onychomycosis in Isfahan, Iran. *Mycoses* 2010; 53: 153–157.
- Garcia-Martos P, Guarro J, Gené J, Linares M, Ortoneda M. Onychomycosis caused by *Aspergillus sclerotiorum*. *J Mycol Med* 2001; 11: 222–224.
- Kristensen L, Stenderup J, Otkjaer A. Onychomycosis due to *Aspergillus tamarii* in a 3-year-old boy. *Acta Derm Venereol* 2005; 85: 261–262.
- Takahata Y, Hiruma M, Sugita T, Muto M. A case of onychomycosis due to *Aspergillus sydowii* diagnosed using DNA sequence analysis. *Mycoses* 2008; 51: 170–173.
- Zotti M, Machetti M, Perotti M, Barabino G, Persi A. A new species, *Aspergillus persii*, as an agent of onychomycosis. *Med Mycol* 2010; 48: 656–660.
- Gupta A, Cooper E, Mac Donald P, Summerbell RC. Utility of inoculum counting (Walshe and English criteria) in clinical diagnosis of onychomycosis caused by non-dermatophytic filamentous fungi. *J Clin Microbiol* 2001; 39: 2115–2121.
- Glass NL, Donaldson GC. Development of primer sets designed for use with the PCR to amplify conserved genes from filamentous ascomycetes. *Appl Environ Microbiol* 1995; 61: 1323–1330.
- Baudraz-Rosselet F, Ruffieux C, Lurati M, Bontems O, Monod M. Onychomycosis insensitive to systemic terbinafine and azole treatments reveals non-dermatophyte moulds as infectious agents. *Dermatology* 2010; 220: 164–168.
- Escobar ML, Carmona-Fonseca J. Onychomycosis by common non-dermatophyte moulds. *Rev Iberoam Micol* 2003; 20: 6–10.
- Mügge C, Hausteil UF, Nenoff P. Causative agents of onychomycosis – a retrospective study. *J Dtsch Dermatol Ges* 2006; 4: 218–228.
- Manikandan P, Varga J, Kocsubé S, Samson RA, Anita R, Revathi R, et al. Mycotic keratitis due to *Aspergillus nomius*. *J Clin Microbiol* 2009; 47: 3382–3385.
- Kurtzman C P, Horn BW, Hesseltine CW. *Aspergillus nomius*, a new aflatoxin-producing species related to *Aspergillus flavus* and *Aspergillus tamarii*. *Antonie van Leeuwenhoek* 1987; 53: 147–158.