

Cutaneous Intravascular Natural Killer-cell Lymphoma: A Rare Case and Review of the Literature

Jia-Bin Liao¹⁻³, Pin-Pen Hsieh^{2,3}, Yu-Ching Hwang¹, Shong-Ling Lin² and Chieh-Shan Wu^{1,4*}

Departments of ¹Dermatology, ²Pathology and Laboratory Medicine, Kaohsiung Veterans General Hospital, No. 386, Dajhong 1st Road, Zuoying District, Kaohsiung City 81362, Taiwan, ³Centre for General Education, Yuh-Ing Junior College of Health Care and Management, Kaohsiung, Taiwan, and ⁴Department of Dermatology, Faculty of Medicine, College of Medicine, Kaohsiung Medical University, Kaohsiung, Taiwan. *E-mail: dermawu@vghks.gov.tw
Accepted November 23, 2010.

Intravascular lymphoma (IVL) is a rare and aggressive variant of extranodal non-Hodgkin's lymphoma, characterized by almost exclusive proliferation of neoplastic lymphocytes within the blood vessel lumen, and a predilection for the skin and brain (1). Cases of IVL of T-cell or natural killer (NK)-cell lineage are even rarer. We report here a case of cutaneous intravascular NK-cell lymphoma (IVNKL) presenting with multiple erythematous, indurated, tender plaques over both the lower extremities.

CASE REPORT

A 42-year-old Taiwanese woman visited our dermatology clinic with complaints of increasing numbers of erythematous, indurated, tender plaques over both the lower extremities, especially the thighs, for 7 months (Fig. 1). Constitutional symptoms, such as malaise, dizziness, and chilly sensations, were also noted. Under the preliminary impression of panniculitis, a biopsy of the skin of the left thigh was performed. A histological study revealed many distended vessels filled with atypical large lymphoid cells in the dermis and subcutis (Fig. 2A). The tumour cells were all confined within the vessels and had large, irregular hyperchromatic nuclei with ample eosinophilic cytoplasm (Fig. 2B). Scattered mitotic figures were found. Fibrin thrombi mixed

with atypical lymphoid cells were occasionally found. The vessels were surrounded by a small number of non-neoplastic lymphocytes. Immunohistochemical studies showed that the tumour cells were CD3^ε⁺, CD56⁺, granzyme B⁺, βF1⁻, CD4⁻, CD5⁻, CD8⁻, CD20⁻, CD30⁻, Pax5⁻, and TdT⁻. Approximately 99% of the tumour cells were Ki-67-positive. *In situ* hybridization for Epstein-Barr virus-encoded RNA (EBER) revealed the presence of the Epstein-Barr virus (EBV) (Fig. S1, available at <http://www.medicaljournals.se/acta/content/?doi=10.2340/0015555-1083>). The results of immunohistochemical tests and EBER *in situ* hybridization suggested IVNKL.

The patient did not have nasal lymphoma. Bone marrow biopsy and analysis of the aspirate revealed no evidence of tumour involvement. The results of all laboratory and radiological studies, including blood cell counts and liver and renal function tests, were unremarkable. Bone scan, gallium scan for tumour survey and whole body positron emission tomography scan did not suggest lymphadenopathy or lymphomatous involvement of the bone or internal organs. Because of individual factors, the patient was transferred to another medical centre for further treatment after the diagnosis was confirmed. She continually underwent the following regime during a 14-month period because of lesion progression: two courses of radiotherapy (performed using a linear accelerator); one course of cyclophosphamide, doxorubicin, vincristine and prednisone (CHOP) chemotherapy; three courses of proteasome inhibitor (bortezomib) therapy; and four courses of etoposide, prednisolone, vincristine, cyclophosphamide, and doxorubicin (EPOCH) chemotherapy. At the time of reporting the patient is still alive and has had the disease for 14 months since diagnosis.

DISCUSSION

The majority of reported cases of IVL are large B-cell lymphomas (2), and only a few cases of lymphoma of T-cell lineage and histiocytic malignancies have been described (3–6). To the best of our knowledge, only six cases of IVL with a definite NK-cell phenotype have been reported in English literature (1, 7–10). The most typical immunophenotypes of NK cells are CD2⁺; CD56⁺; CD3^ε⁺; TIA-1⁺; granzyme B⁺; perforin⁺; CD4⁻; CD5⁻; CD8⁻; and βF1⁻; among these, TIA-1, granzyme B, and perforin are markers for cytotoxicity. NK cells are always negative for α/β (βF1 antibody) and γ/δ markers, and the T-cell receptor (TCR) genes are not rearranged in true NK-cell proliferations (11).

A comparison with six previously reported cases, as shown in Table SI (available at <http://www.medicaljournals.se/acta/content/?doi=10.2340/0015555-1083>) a female to male ratio of 2.5:1 and an age range from 23 to 71 years (median 42 years). Dermatological manifestation was observed in 6 (86%) cases, including erythematous plaques or nodules over the extremities (6

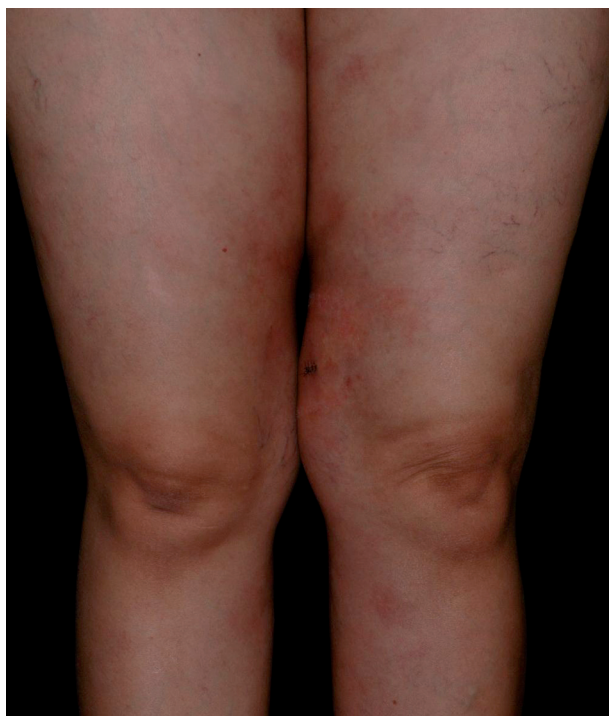

Fig. 1. A 42-year-old Taiwanese woman with increasing number of erythematous indurated tender plaques over both the lower extremities for 7 months.

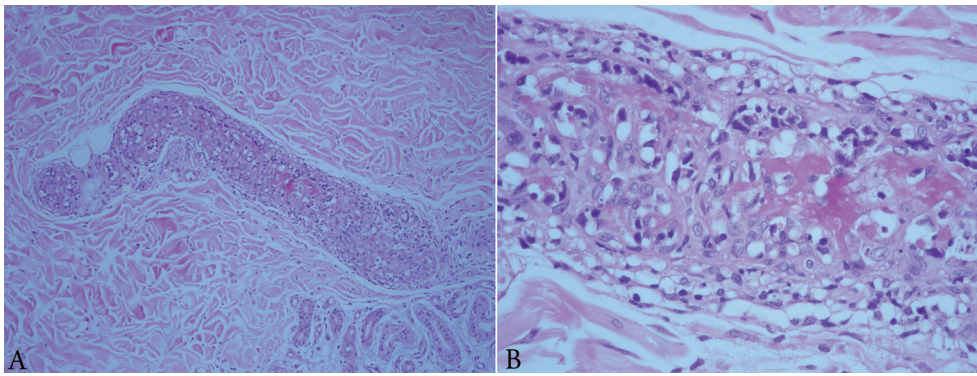


Fig. 2. (A) Distended vessels filled with atypical large lymphoid cells in the dermis. (B) The tumour cells were all confined within the vessels and had large, irregular hyperchromatic nuclei with ample eosinophilic cytoplasm.

cases) and trunk (4 cases). Brain involvement was noted in 2 (29%) cases. In our case, the involvement of the brain and internal organs could not be proved despite the clinical presentation of dizziness and weakness. Despite the intravascular predilection of the tumour cells, peripheral blood involvement is unusual. None of the 7 patients had nasal lymphoma.

All the 7 cases shared the same immunophenotype, which resembled that of nasal-type NK/T-cell lymphomas (12). EBV is generally absent in IVLs of the B-cell lineage (4). However, most cases (6/7, 86%) of IVNKL were associated with EBV infection. The proliferative index determined in 4 cases by using the Ki-67 antibody was 99–100%, and this finding indicates that the neoplastic cells are actively proliferating. Further genetic studies showing the germline *TCR* gene would support the NK-cell lineage of this disease; however, a *TCR* gene rearrangement study was not performed because of the rarity of tumour cells in this case.

The peculiarly restricted intravascular proliferation of the lymphoma cells is attributed to the defective adhesion molecules of the lymphoma cells, which do not allow the extravascular migration of cells (13). As previously described, fibrin thrombi were also observed in the present case, which may be caused by the sluggish blood flow due to obstruction by lymphoma cells. However, the obstruction may not be complete because no ischaemic infarct of the skin was observed.

The one-year overall survival rate of the 7 cases was 64.3%, which indicated the aggressive nature of this disease and its poor prognosis. CHOP is insufficient for the treatment of IVNKL, and its combination with intensive chemotherapy, radiotherapy, proteasome inhibitor, and/or stem cell transplantation may be necessary.

REFERENCES

1. Wu H, Said JW, Ames ED, Chen C, McWhorter V, Chen P, et al. First reported cases of intravascular large cell lymphoma of the NK cell type: clinical, histologic, immunophenotypic, and molecular features. *Am J Clin Pathol* 2005; 123: 603–611.
2. Swerdlow SH. WHO classification of tumours of haematopoietic and lymphoid tissues, 4th edn. Lyon, France: International Agency for Research on Cancer; 2008.
3. Sepp N, Schuler G, Romani N, Geissler D, Gattlinger C, Burg G, et al. "Intravascular lymphomatosis" (angioendotheliomatosis): evidence for a T-cell origin in two cases. *Hum Pathol* 1990; 21: 1051–1058.
4. Au WY, Shek WH, Nicholls J, Tse KM, Todd D, Kwong YL. T-cell intravascular lymphomatosis (angiotropic large cell lymphoma): association with Epstein-Barr viral infection. *Histopathology* 1997; 31: 563–567.
5. O'Grady JT, Shahidullah H, Doherty VR, al-Nafussi A. Intravascular histiocytosis. *Histopathology* 1994; 24: 265–268.
6. Gleason BC, Brinster NK, Granter SR, Pinkus GS, Lindeman NI, Miller DM. Intravascular cytotoxic T-cell lymphoma: a case report and review of the literature. *J Am Acad Dermatol* 2008; 58: 290–294.
7. Santucci M, Pimpinelli N, Massi D, Kadin ME, Meijer CJ, Müller-Hermelink HK, et al. Cytotoxic/natural killer cell cutaneous lymphomas. Report of EORTC Cutaneous Lymphoma Task Force Workshop. *Cancer* 2003; 97: 610–627.
8. Kuo TT, Chen MJ, Kuo MC. Cutaneous intravascular NK-cell lymphoma: report of a rare variant associated with Epstein-Barr virus. *Am J Surg Pathol* 2006; 30: 1197–1201.
9. Song DE, Lee MW, Ryu MH, Kang DW, Kim SJ, Huh J. Intravascular large cell lymphoma of the natural killer cell type. *J Clin Oncol* 2007; 25: 1279–1282.
10. Nakamichi N, Fukuhara S, Aozasa K, Morii E. NK-cell intravascular lymphomatosis – a mini-review. *Eur J Haematol* 2008; 81: 1–7.
11. Cerroni L, Massone C, Kutzner H, Mentzel T, Umberto P, Kerl H. Intravascular large T-cell or NK-cell lymphoma: a rare variant of intravascular large cell lymphoma with frequent cytotoxic phenotype and association with Epstein-Barr virus infection. *Am J Surg Pathol* 2008; 32: 891–898.
12. Kwong YL. Natural killer-cell malignancies: diagnosis and treatment. *Leukemia* 2005; 19: 2186–2194.
13. Ponzoni M, Arrigoni G, Gould VE, Del Curto B, Maggioni M, Scapinello A, et al. Lack of CD 29 (beta1 integrin) and CD 54 (ICAM-1) adhesion molecules in intravascular lymphomatosis. *Hum Pathol* 2000; 31: 220–226.