

INVESTIGATIVE REPORT

Novel and Recurrent *FERMT1* Gene Mutations in Kindler Syndrome

Tanasit TECHANUKUL¹, Gomathy SETHURAMAN², Abraham ZLOTOGORSKI³, Liran HOREV³, Michal MACAROV⁴, Alison TRAINER⁵, Kenneth FONG¹, Marko LENS⁵, Ljiljana MEDENICA⁶, Venkatesh RAMESH⁷, John A. McGRATH¹ and Joey E. LAI-CHEONG¹

¹St John's Institute of Dermatology, King's College London, London, UK, ²Department of Dermatology, All India Institute of Medical Sciences, Delhi, India, ³Department of Dermatology and The Center for Genetic Diseases of the Skin and Hair and ⁴Department of Human Genetics and Metabolic Diseases, Hadassah-Hebrew University Medical Center Jerusalem, Israel, ⁵Victorian Clinical Genetics Services, Murdoch Childrens Research Institute, Parkville, Victoria, Australia, ⁶Genetic Epidemiology Unit, King's College London, London, UK, ⁷Department of Dermatovenereology, School of Medicine, University of Belgrade, Belgrade, Serbia, and ⁷Department of Dermatology, Safdarjung Hospital, New Delhi, India

Kindler syndrome (OMIM 173650) is an autosomal recessive condition characterized by skin blistering, skin atrophy, photosensitivity, colonic inflammation and mucosal stenosis. Fewer than 100 cases have been described in the literature. First reported in 1954, the molecular basis of Kindler syndrome was elucidated in 2003 with the discovery of *FERMT1* (*KIND1*) loss-of-function mutations in affected individuals. The *FERMT1* gene encodes kindlin-1 (also known as fermitin family homologue 1), a 77 kDa protein that localizes at focal adhesions, where it plays an important role in integrin signalling. In the current study, we describe five novel and three recurrent loss-of-function *FERMT1* mutations in eight individuals with Kindler syndrome, and provide an overview of genotype-phenotype correlation in this disorder. Key words: *kindlin-1*; *epidermolysis bullosa*; *skin atrophy*; *poikiloderma*; *blistering*.

(Accepted November 10, 2010.)

Acta Derm Venereol 2011; 91: 267–270.

John McGrath, Dermatology Research Laboratories, Floor 9 Tower Wing, Guy's Hospital, Great Maze Pond, London SE1 9RT, UK. E-mail: john.mcgrath@kcl.ac.uk

Kindler syndrome (KS; OMIM 173650) is a rare autosomal recessive muco-cutaneous disorder. The cutaneous features consist of trauma-induced skin blistering, particularly of acral sites, skin atrophy, poikiloderma (a combination of skin atrophy, hypo- and hyperpigmentation and telangiectases) and varying degrees of photosensitivity (1). The extra-cutaneous features include colonic inflammation, gingivitis, periodontitis and mucosal inflammation affecting the oesophagus, urethra, vagina and anus. There is also an increased risk of muco-cutaneous cancer (1). In 2003, the molecular basis of KS was elucidated with the discovery of loss-of-function *FERMT1* (also known as *KIND1*) gene mutations by genome wide linkage studies and candidate gene sequencing of DNA obtained from large consanguineous pedigrees (2, 3). The *FERMT1* gene

encodes kindlin-1 (also known as fermitin family homologue-1), a 77 kDa protein that localizes to focal adhesions, where it mediates actin cytoskeleton-extracellular matrix (ECM) interaction (3). Kindlin-1 participates in integrin activation, a critical process for cell adhesion, differentiation and migration (4, 5). In normal skin, kindlin-1 is present in the basal keratinocyte layer in a polar fashion (3, 6, 7). In KS skin, reduced kindlin-1 expression is noted, associated with severe disruption of the cutaneous basement membrane (3, 6, 7). To date, 40 different disease-associated *FERMT1* mutations in KS have been reported. In this study, we expand the *FERMT1* mutation database to 45 by reporting an additional five novel and three recurrent mutations in eight individuals with KS and provide an overview of genotype-phenotype correlation in this condition.

MATERIALS AND METHODS

Molecular analysis

This study was approved by the local research ethics committees of the referring hospitals as well as the Guy's and St Thomas' Hospitals NHS Foundation Trust and conducted according to the principles of the Declaration of Helsinki. Peripheral blood samples were taken from eight affected individuals and, where possible, from their parents. Polymerase chain reaction (PCR) amplification of genomic DNA was performed using 14 pairs of primers spanning the coding exons and flanking introns of the *FERMT1* gene (RefSeq NM_016213.1) as described previously (3, 8, 9). The amplicons were purified using the QIAquick PCR purification kit (Applied Biosystems, Warrington, UK) and sequenced using an Applied Biosystems 3730 DNA Analyzer. Mutations were confirmed by bi-directional sequencing and excluded in 200 control chromosomes in unrelated control individuals.

RESULTS

Clinical features of patients with Kindler syndrome

Eight individuals (subjects 1–8) with KS were studied. Their clinical features and clinical details are illustrated in Fig. 1 and Table I, respectively. The clinical details of subjects 2, 7 and 8 have been reported previously (10–12).

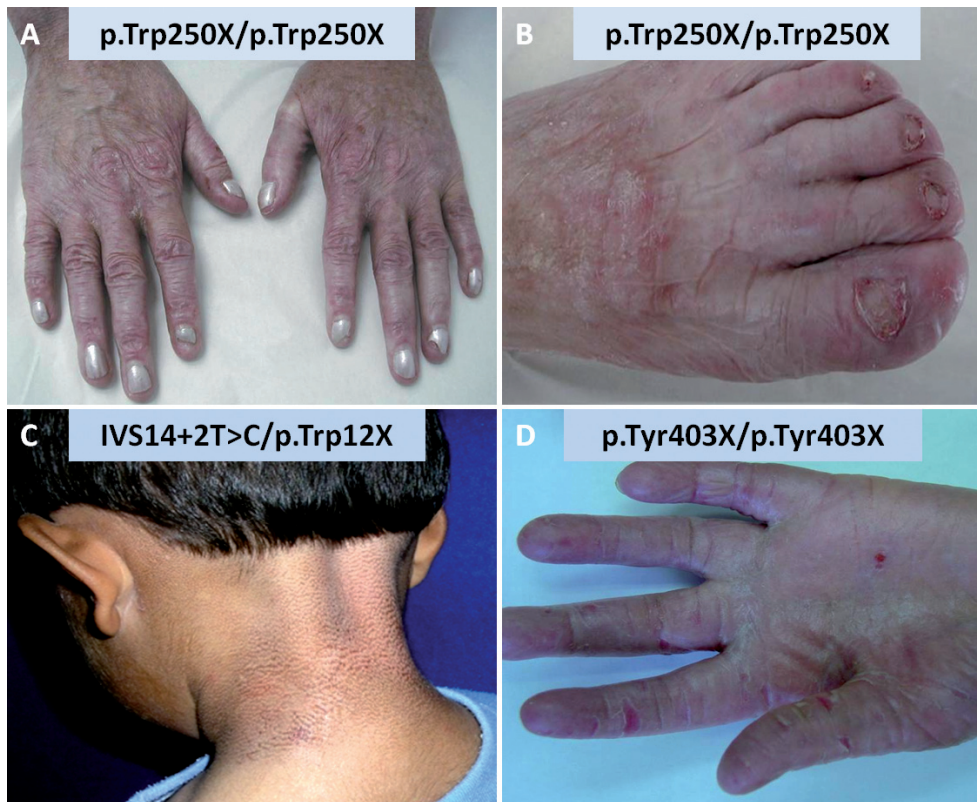

Fig. 1. Clinical features of Kindler syndrome (KS). (A and B) Marked skin atrophy on dorsal aspect of hands and feet of a 42-year-old individual (subject 2) with KS who harboured the homozygous *FERMT1* mutation, p.Trp250X/p.Trp250X. (C) Poikiloderma involving the neck of a 10-year-old individual (subject 1) with compound heterozygous *FERMT1* mutations IVS14+2T>C and p.Trp12X. (D) Palmar hyperkeratosis and erosions in a 9-year-old subject (subject 4) with the homozygous *FERMT1* mutation, p.Tyr403X/p.Tyr403X.

FERMT1 mutation screening

Sequencing analysis of DNA from subject 1 showed compound heterozygous *FERMT1* mutations, namely p.Trp12X and IVS14+2T>C (Fig. S1A; available at <http://www.medicaljournals.se/acta/content/?doi=10.2340/00015555-1063>). Sequencing analysis of parental DNA revealed that the mutation, p.Trp12X, was paternally inherited, while the other mutation, IVS14+2T>C, was maternally transmitted. In subject 2, mutation analysis disclosed a homozygous nonsense mutation, p.Trp250X, in the *FERMT1* gene (Fig. S1B). Mutation analysis of genomic DNA from subject 3 disclosed two heterozygous mutations; namely, a nonsense mutation, p.Gln49X, and a frameshift mutation, c.676insC (Fig. S1C). Sequencing analysis of genomic DNA from subject 4 disclosed a homozygous nonsense mutation, p.Tyr403X, in exon 10 of the *FERMT1* gene (Fig. S1D). Mutation analysis of subject 5 showed a compound heterozygous *FERMT1* mutations, denoted c.384_385+2del4 and IVS13+2T>C (Fig. S1E). In subject 6, a homozygous *FERMT1* mutation, denoted c.676insC was identified in exon 5. In subjects 7 and 8, a homozygous c.676insC mutation was present (Fig. S1F). None of these mutations has been identified in screening 200 chromosomes in unrelated control individuals.

DISCUSSION

In this study, we report 5 novel and 3 recurrent pathogenic *FERMT1* mutations in 8 individuals with KS.

The previously unreported *FERMT1* mutations were p.Trp12X, IVS14+2T>C, p.Trp250X, p.Gln49X and c.384_385+2del4. The following *FERMT1* mutations were recurrent: c.676insC, p.Tyr403X and IVS13+2T>C. When added to the global *FERMT1* mutation database in KS, a total of 46 mutations have now been disclosed. The complete *FERMT1* mutation database is illustrated in Fig. 2. The c.676insC mutation is a recurrent mutation, previously reported in individuals of Pakistani (8), Brazilian (of Italian descent) (13) and Albanian (14) origins. In this study, we disclose the c.676insC mutation for the first time in an Australian Caucasian individual, an Indian subject and two affected brothers from Serbia. The mutation, p.Tyr403X, has recently been described in a 36-year-old individual with KS, but no further details about his ethnicity or geographical background were available (15). Furthermore, the splice site mutation, IVS13+2T>C, has been reported previously in a 5-day-old neonate who remains, to date, the youngest patient to be accurately diagnosed with KS (16).

An increased risk of muco-cutaneous squamous cell carcinoma (SCC) has been noted in KS. Specifically, the following mutations have been reported in association with SCC in KS: IVS7-1G>A, c.93_94delGA, IVS9-6T>A, p.Arg110X and g80929_89169del (1). In our study, we report an additional two *FERMT1* mutations that were associated with SCC, namely c.676insC and p.Trp250X. To our knowledge, two individuals with KS have died as a result of complications of their SCC. It

Table I. Clinical details of the 8 subjects studied with Kindler syndrome

Subject	Mutation	Ethnicity/Gender/ Age at diagnosis, years	Blistering	Skin atrophy	Poikiloderma	Photosensitivity	Dental problems	Other clinical problems	Ref
1	p.Trp12X/ IVS14+2T>C	Indian male, 10	Blistering at birth confined to the acral part	Skin atrophy particularly on the dorsal aspects of the hands and feet	Progressive poikiloderma affecting the neck	Present	Not documented	Urethral stenosis	
2	p.Trp250X/ p.Trp250X	Jewish-Kurdish female, 42 (now deceased)	Blistering of skin at birth overlying pressure points	Skin atrophy of acral sites and overlying sites of previous skin blistering	Poikiloderma affecting the face, neck, upper back and chest	Persistent photosensitivity	Widespread white macules in the buccal mucosa	Squamous cell carcinoma of the hard palate	(10, 11)
3	p.Gln49X/ c.676insC	Australian female, 7	Blistering on distal limbs at day 7	Not documented	Progressive poikiloderma at 3 years	Present	No dental problems	Anal fissure and severe constipation	
4	p.Tyr403X/ p.Tyr403X	Arabic male, 9	Trauma-induced blisters at 1.5 years	Skin atrophy on the dorsal aspects of the hands and feet with palmoplantar hyperkeratosis	Progressive poikiloderma	Photosensitivity beginning at 1.5 years	Severe gingivitis	Urethral stenosis	
5	c.384_385+2del4/ IVS13+2T>C	Indian female, 11	Trauma-induced blisters at 2 years	Skin atrophy of extremities at 6 years	Poikiloderma of sun-exposed sites at 6 years	Not documented	Not documented	Nil	
6	c.676insC/ c.676insC	Indian male, 4	Skin blistering in neonatal period affecting hands and feet	Skin atrophy with onset at 4 months	Poikiloderma at 4 months	Nil	Nil	Nil	
7 and 8	c.676insC/ c.676insC	Serbian brothers aged 60 and 57, respectively	Trauma-induced skin blistering soon after birth on acral sites	Progressive skin atrophy from the neonatal period	Progressive poikiloderma from the neonatal period	Present from neonatal period	Nil	Subject 7 – squamous cell carcinoma of the upper lip at 43 years and a squamous cell carcinoma of the penis at 45 years. Both brothers suffer from keratoconjunctivitis and ectropion. Dystrophic nails and urethral and oesophageal stenoses.	(12)

is, however, premature to speculate whether KS-associated SCC is more aggressive than non-KS-associated SCC, given the small number of individuals with KS with SCC. While an upregulation of kindlin-1 has been described in certain cancers (17), the development of SCC in KS provides an intriguing role for kindlin-1 deficiency in the development of cancer. Although there does not seem to be any correlation between the nature of the mutations and the occurrence of cancer in these individuals, it is possible that some mutations may predispose to carcinogenesis. For instance, the splice site mutation, IVS9-6T>A, led to ablation of exons 9, 10 and 11 of the *FERMT1* gene. Amplification and sequencing of cDNA from the skin of this individual revealed aberrant splicing with either deletion of exon 10 or deletion of exons 9, 10 and 11, both of which involved loss of the pleckstrin homology domain of kindlin-1 (18).

A possible link has been postulated between intestinal pathology in KS and mutations present within exons 2–7 of the *FERMT1* gene. The number of reported cases is, however, small and further work is required to delineate the role of kindlin-1 in colonic pathology. Interestingly, kindlin-1 null mouse, generated by replacing the ATG-containing exon 2 with a neomycin resistance cassette, displayed an ulcerative colitis-like phenotype (5), previously reported in several individuals with KS (14, 19, 20). Although a clear genotype-phenotype correlation is not apparent in KS, the present study expands the global *FERMT1* mutation database as well as helps optimize overall mutation detection strategies and highlights specific mutations in patients from particular geographical origins.

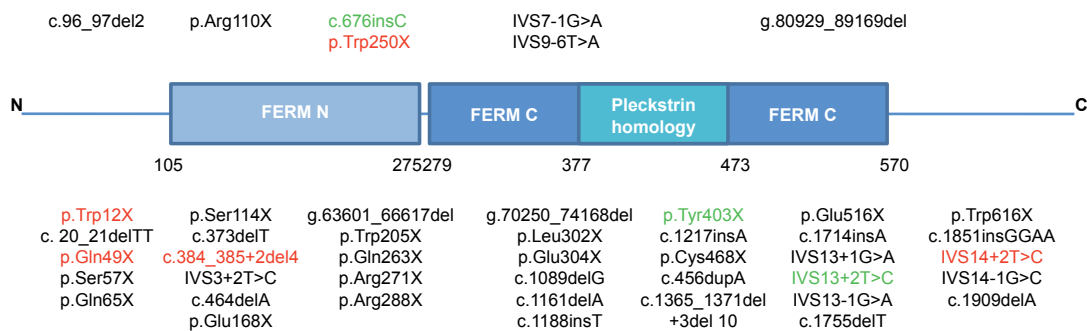


Fig. 2. Summary of global *FERMT1* mutation database. The mutations are aligned alongside kindlin-1 protein domains which include a bipartite FERM domain interrupted by a pleckstrin homology (PH) domain. A total of 45 different loss-of-function mutations have now been identified in Kindler syndrome. Novel mutations are illustrated in red. Recurrent mutations identified in this study are shown in green. Mutations illustrated above the schematic represent those associated with muco-cutaneous malignancy. FERM: Four point one protein, Ezrin, Radixin, Moesin.

ACKNOWLEDGEMENTS

The study was funded by the British Skin Foundation and the British Association of Dermatologists. Support from the Department of Health via the National Institute of Health Research Comprehensive Biomedical Research Centre award to Guy's and St Thomas' Hospital NHS Foundation Trust in partnership with King's College London is gratefully acknowledged.

The authors declare no conflicts of interest.

REFERENCES

- Lai-Cheong JE, Tanaka A, Hawche G, Emanuel P, Maari C, Taskesen M, et al. Kindler syndrome: a focal adhesion genodermatosis. *Br J Dermatol* 2009; 160: 233–242.
- Jobard F, Bouadjar B, Caux F, Hadj-Rabia S, Has C, Matsuda F, et al. Identification of mutations in a new gene encoding a FERM family protein with a pleckstrin homology domain in Kindler syndrome. *Hum Mol Genet* 2003; 12: 925–935.
- Siegel DH, Ashton GH, Penagos HG, Lee JV, Feiler HS, Wilhelmsen KC, et al. Loss of kindlin-1, a human homolog of the *Caenorhabditis elegans* actin-extracellular-matrix linker protein UNC-112, causes Kindler syndrome. *Am J Hum Genet* 2003; 73: 174–187.
- Lai-Cheong JE, Parsons M, Tanaka A, Ussar S, South AP, Gomathy S, et al. Loss-of-function *FERMT1* mutations in kindler syndrome implicate a role for fermitin family homolog-1 in integrin activation. *Am J Pathol* 2009; 175: 1431–1441.
- Ussar S, Moser M, Widmaier M, Rognoni E, Harrer C, Genzel-Boroviczeny O, et al. Loss of kindlin-1 causes skin atrophy and lethal neonatal intestinal epithelial dysfunction. *PLoS Genet* 2008; 4: e1000289.
- Herz C, Aumailley M, Schulte C, Schlotzer-Schrehardt U, Bruckner-Tuderman L, Has C. Kindlin-1 is a phosphoprotein involved in regulation of polarity, proliferation, and motility of epidermal keratinocytes. *J Biol Chem* 2006; 281: 36082–36090.
- Lai-Cheong JE, Ussar S, Arita K, Hart IR, McGrath JA. Colocalization of kindlin-1, kindlin-2, and migfilin at keratinocyte focal adhesion and relevance to the pathophysiology of Kindler syndrome. *J Invest Dermatol* 2008; 128: 2156–2165.
- Ashton GH, McLean WH, South AP, Oyama N, Smith FJ, Al-Suwaid R, et al. Recurrent mutations in kindlin-1, a novel keratinocyte focal contact protein, in the autosomal recessive skin fragility and photosensitivity disorder, Kindler syndrome. *J Invest Dermatol* 2004; 122: 78–83.
- Lai-Cheong JE, Liu L, Sethuraman G, Kumar R, Sharma VK, Reddy SR, et al. Five new homozygous mutations in the *KIND1* gene in Kindler syndrome. *J Invest Dermatol* 2007; 127: 2268–2270.
- Hacham-Zadeh S, Garfunkel AA. Kindler syndrome in two related Kurdish families. *Am J Med Genet* 1985; 20: 43–48.
- Lotem M, Raben M, Zeltser R, Landau M, Sela M, Wygoda M, et al. Kindler syndrome complicated by squamous cell carcinoma of the hard palate: successful treatment with high-dose radiation therapy and granulocyte-macrophage colony-stimulating factor. *Br J Dermatol* 2001; 144: 1284–1286.
- Stevanovic D. The diffuse and macular atrophic dermatosis. A precocious and progressive light degenerative condition. *Arch Dermatol Res* 1979; 265: 91–99.
- Martignago BC, Lai-Cheong JE, Liu L, McGrath JA, Cestari TF. Recurrent *KIND1* (C20orf42) gene mutation, c.676insC, in a Brazilian pedigree with Kindler syndrome. *Br J Dermatol* 2007; 157: 1281–1284.
- Mansur AT, Elcioglu NH, Aydingoz IE, Akkaya AD, Serdar ZA, Herz C, et al. Novel and recurrent *KIND1* mutations in two patients with Kindler syndrome and severe mucosal involvement. *Acta Derm Venereol* 2007; 87: 563–565.
- Has C, Herz C, Zimina E, Qu HY, He Y, Zhang ZG, et al. Kindlin-1 is required for RhoGTPase-mediated lamellipodia formation in keratinocytes. *Am J Pathol* 2009; 175: 1442–1452.
- Fassihi H, Wessagowit V, Jones C, Dopping-Hepenstal P, Denyer J, Mellerio JE, et al. Neonatal diagnosis of Kindler syndrome. *J Dermatol Sci* 2005; 39: 183–185.
- Weinstein EJ, Bourner M, Head R, Zakeri H, Bauer C, Mazzarella R. URP1: a member of a novel family of PH and FERM domain-containing membrane-associated proteins is significantly over-expressed in lung and colon carcinomas. *Biochim Biophys Acta* 2003; 1637: 207–216.
- Arita K, Wessagowit V, Inamadara AC, Palit A, Fassihi H, Lai-Cheong JE, et al. Unusual molecular findings in Kindler syndrome. *Br J Dermatol* 2007; 157: 1252–1256.
- Kern JS, Herz C, Haan E, Moore D, Nottelmann S, von Lilien T, et al. Chronic colitis due to an epithelial barrier defect: the role of kindlin-1 isoforms. *J Pathol* 2007; 213: 462–470.
- Sadler E, Klausegger A, Muss W, Deinsberger U, Pohla-Gubo G, Laimer M, et al. Novel *KIND1* gene mutation in Kindler syndrome with severe gastrointestinal tract involvement. *Arch Dermatol* 2006; 142: 1619–1624.