

## Meyerson Phenomenon Around Naevi: Resolution After Sun Exposure?

Anna Balato, Serena Lembo, Teresa Cirillo, Matteo Megna, Maddalena Napolitano and Nicola Balato

Department of Dermatology, University of Naples Federico II, Via Pansini, 5, IT-80131 Napoli, Italy. E-mail: annabalato@yahoo.it

Accepted November 1, 2010.

Meyerson phenomenon (MP) is an inflammatory, sometimes itchy, eczematous eruption usually encircling a pre-existing melanocytic naevus. The terms halo dermatitis and Meyerson's naevus are also frequently used to describe it (1). MP usually appears in otherwise healthy young male individuals, but has also been reported in females and young children (2). Apart from slight itching, no other symptoms usually arise (3). Such a naevus can be mistaken for melanoma or Sutton's naevus (1). In making a differential diagnosis, halo naevus (4), pityriasis rosea (5) and roseola of syphilis should be considered.

We report here a case of a man with a history of eczematous reaction and itch involving 3 pre-existing melanocytic naevi at different times.

### CASE REPORT

In March 2009 a 28-year-old man was referred to our outpatient clinic for a two-week history of an eczematous plaque around a pre-existing melanocytic naevus on the right side of his abdomen. Clinical examination revealed a 1 cm, circular, erythematovesicular plaque accompanied by scaling, overlying a 2 mm melanocytic naevus. The patient reported severe itch. He was not on any medication, and reported no external contact agent, history of atopy, vitiligo or melanoma. Dermoscopic examination of the lesion revealed intense erythema with scaling and yellow crusts overlying and surrounding the melanocytic naevus. The eczematous manifestation prevented us from examining the naevus pattern. A diagnosis of MP was made, and the patient was started on topical therapy based on corticosteroids and fusidic acid. After 3 weeks the eczema improved and dermoscopic examination showed a regular, reticular pattern with mild scaling and light hypopigmentation encircling the naevus; erythema was absent. Cortico-antibiotic treatment was stopped. After two weeks a relapse of the eczematous manifestation was registered and a similar inflammatory phenomenon involving two other melanocytic naevi developed on the abdomen (Fig. 1). The patient was therefore started on a new course of treatment with topical corticosteroids. At the follow-up visit after one month, the patient presented with complete resolution of all 3 inflammatory manifestations (see Fig. 1); the melanocytic lesions showed no changes, either clinically or dermoscopically. Interestingly, the patient reported whole body exposure in the summer time and low compliance with the prescribed treatment. Eighteen months later, no changes were detected in the involved naevi, with no recurrences of inflammatory background.

### DISCUSSION

The management of MP is controversial; some authors advise surgical excision of the naevus, especially if the lesion does not respond to topical corticosteroids (6). Others report that spontaneous healing occurs in MP, without involution of the naevus, and therefore surgical excision is unnecessary. Topical corticosteroids can be employed in cases of particularly intense inflammation and itch (2).

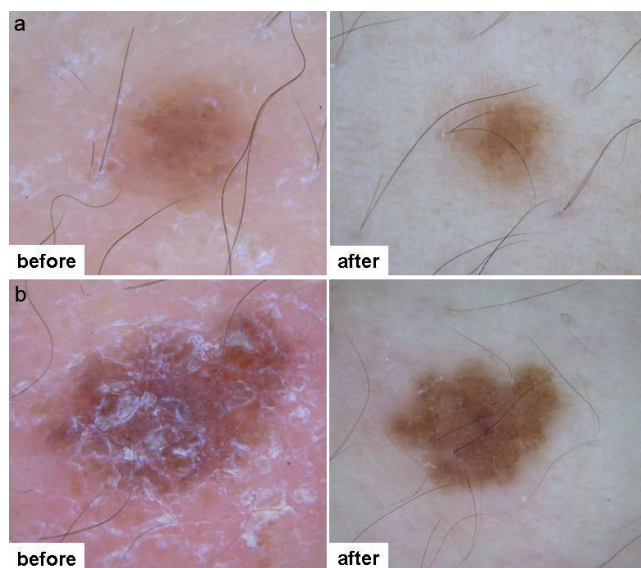


Fig. 1. Dermoscopic examination of 2 out of 3 melanocytic naevi with Meyerson phenomenon before and after cortico-antibiotic treatment and whole body exposure in the summer time.

In our case, we decided to treat the lesions with corticosteroids and fusidic acid in order to enable clinical and dermoscopic analysis of the naevi. Dermoscopy monitoring enabled us to detect any eventual changes.

The inflammation was reduced by corticosteroid treatment, although there was a recurrence when treatment was interrupted. Interestingly, resolution of the eczema occurred after gradual sun exposure. Although sunburn has been reported as a trigger of MP (7), we hypothesize that, in our case, the lesions benefited from the immunosuppressive action of the sunlight, in the same way as other eczematous conditions (e.g. allergic contact dermatitis) do (8).

In conclusion, it may be possible to manage MP by the use of topical corticosteroids in association with follow-up visits, based on dermoscopic controls. In the case of corticosteroid ineffectiveness, narrow-band ultraviolet B treatment may be considered, although more cases need to be observed to confirm this hypothesis. Surgical excision should be reserved for cases with any dermoscopic changes or if the above-mentioned treatments are not successful.

*The authors declare no conflicts of interest.*

### REFERENCES

1. Brenan J, Kossard S, Krivanek J. Halo eczema around melanocytic nevi. *Int J Dermatol* 1985; 24: 226–229.

2. Shifer O, Tchetchik R, Glazer O, Metzker A. Halo dermatitis in children. *Pediatr Dermatol* 1992; 9: 275–277.
3. Vega J, Rodriguez MA, Martinez M. Eczematous halo reaction in congenital nevus. *Int J Dermatol* 2003; 42: 895.
4. Kus S, Ince U, Candan I, Gurunluoglus R. Meyerson phenomenon associated with dysplastic compound nevi. *J Eur Acad Derm Venereol* 2006; 20: 350–351.
5. Meyerson LB. A peculiar papulosquamous eruption involving pigmented naevi. *Arch Dermatol* 1971; 103: 510–512.
6. Cox NH, Bloxham CA, Lawrence CM. Halo eczema-resolution after excision of the central naevus alone. *Clin Exp Dermatol* 1991; 16: 66–67.
7. Petit A, Viney C, Gautier A, Sigal M. Coexistence of Meyerson's with Sutton's naevus after sunburn. *Dermatology* 1994; 189: 269–270.
8. Belsito DV. The diagnostic evaluation, treatment, and prevention of allergic contact dermatitis in the new millennium. *J Allergy Clin Immunol* 2000; 105: 409–420.