

## INVESTIGATIVE REPORT

# Identical Glycine Substitution Mutations in Type VII Collagen May Underlie Both Dominant and Recessive Forms of Dystrophic Epidermolysis Bullosa

Noor ALMAANI<sup>1\*</sup>, Lu LIU<sup>2\*</sup>, Patricia J.C. DOPPING-HEPENSTAL<sup>2</sup>, Joey E. LAI-CHEONG<sup>1</sup>, Alvin WONG<sup>3</sup>, Arti NANDA<sup>4</sup>, Celia MOSS<sup>3</sup>, Anna E. MARTINEZ<sup>5</sup>, Jemima E. MELLERIO<sup>5,6</sup> and John A. McGRATH<sup>1</sup>

<sup>1</sup>St John's Institute of Dermatology, King's College London (Guy's Campus), London, <sup>2</sup>The Robin Eady National Diagnostic Epidermolysis Bullosa Laboratory, GSTS Pathology, St John's Institute of Dermatology, St Thomas' Hospital, London, <sup>3</sup>Department of Dermatology, Birmingham Children's Hospital, Birmingham, UK, <sup>4</sup>As'ad Al-Hamad Dermatology Centre, Al-Sabah Hospital, Kuwait, <sup>5</sup>Department of Dermatology, Great Ormond Street Hospital NHS Trust and <sup>6</sup>St John's Institute of Dermatology, The Guy's and St Thomas' NHS Foundation Trust, London, UK

\*These authors contributed equally to the data presented in this report and should be considered as first authors.

**Autosomal dominant and recessive forms of dystrophic epidermolysis bullosa (DEB) result from mutations in the type VII collagen gene (*COL7A1*). Although paradigms have emerged for genotype/phenotype correlation in DEB, some pathogenic mutations in *COL7A1*, notably glycine substitutions within the type VII collagen triple helix, may lead to diagnostic difficulties, since certain glycine substitutions can result in either dominant or recessive mutant alleles. Delineation of glycine substitution mutations into two discrete groups, however, is made difficult by observations that, for some particular glycine substitutions in type VII collagen, the same mutation can result in both dominant and recessive disease. In this report we describe four further glycine missense mutations: p.Gly1483Asp, p.Gly1770Ser, p.Gly2213Arg and p.Gly2369Ser, which can lead to either dominant or recessive DEB, and which result in a spectrum of clinical abnormalities. We also identify a further 30 new glycine substitution mutations that cause either dominant or recessive DEB, but not both. In screening the *COL7A1* gene for mutations in individuals with DEB our data highlight that delineation of glycine substitutions in type VII collagen has important implications for genetic counselling. **Key words:** blister; genodermatosis; mechanobullous; basement membrane; gene mutation.**

(Accepted October 28, 2010.)

Acta Derm Venereol 2011; 91: 262–266.

John McGrath, Dermatology Research Laboratories, Floor 9 Tower Wing, Guy's Hospital, Great Maze Pond, London SE1 9RT, UK. E-mail: john.mcgrath@kcl.ac.uk

All subtypes of dystrophic epidermolysis bullosa (DEB) result from mutations in the type VII collagen gene, *COL7A1* (1). Type VII collagen is the major component of anchoring fibrils at the dermal–epidermal junction and in DEB the anchoring fibrils show variable numerical and/or structural abnormalities, changes

that lead to blistering beneath the lamina densa (2). In dominant forms of DEB, the pathogenic mutations typically involve heterozygous (dominant-negative) glycine substitution (GS) mutations within the type VII collagen triple helix (3–5). In contrast, the molecular pathology of recessive DEB usually comprises nonsense, frameshift or splice site mutations on both *COL7A1* alleles (3–5). However, some cases of recessive DEB also result from GS mutations, which may be silent when heterozygous, but pathogenic when inherited on both alleles or *in trans* with another loss-of-function mutation in *COL7A1* (3, 6). As a result, distinguishing between some dominant and recessive GS mutations can be very difficult, which may have important implications for making accurate diagnoses and for giving appropriate genetic counselling. This challenge is compounded by reports that some specific GS mutations can underlie both dominant and recessive forms of DEB, thus creating diagnostic dilemmas and difficulties (7–15). In this report we add four further GS mutations that can lead to both dominant and recessive forms of DEB and discuss their clinical and genetic significance. These cases were identified in diagnostic *COL7A1* mutation screening performed in the UK National Diagnostic EB Laboratory in London, UK. In addition, we have tabulated all published GS mutations in type VII collagen, sub-dividing them into mixed-type (Table 1), dominant and recessive mutations (Tables SI and SII (available at <http://www.medicaljournals.se/acta/content/?doi=10.2340/00015555-1053>)). These Tables also contain an additional previously unpublished 19 dominant and 15 recessive GS mutations that were disclosed during diagnostic screening within the UK National Diagnostic EB service. Collectively, this information expands the mutation database and helps to refine genotype-phenotype correlation. We believe that the collective data will provide a useful reference resource for other investigators and diagnostic laboratories.

## PATIENTS AND METHODS

### Patients

DNA samples from patients with clinically suspected or skin biopsy proven DEB and their parents (if available) were analysed at the Robin Eady National Diagnostic Epidermolysis Bullosa Laboratory in London, UK. This laboratory was established in 2003 and provides a diagnostic service for EB serving the whole of the UK. Given the multi-cultural nature of the UK, patient ethnicities included white Caucasian, Middle-Eastern, South American, South-East Asian and Asian. Most DNA sequencing was performed as part of the patients' routine clinical care, but for cases linked to separate research projects, DNA screening was undertaken with ethics' committee approval (St Thomas' Hospital Ethics' Committee; 07/H0802/104) with informed consent and carried out in accordance with the principles of the Declaration of Helsinki.

### Mutation detection

Genomic DNA was extracted from peripheral blood leukocytes using standard methods (16). *COL7A1* mutation screening was performed by direct sequencing of all 118 exons and flanking introns of the *COL7A1* gene, as described previously, using an ABI 3100 sequencer (17). Mutations were verified by bi-directional sequencing and restriction endonuclease digestions, where possible.

## RESULTS AND DISCUSSION

### Dominant and recessive mutation: *p.Gly1483Asp*

The mutation p.Gly1483Asp was identified in four Kuwaiti individuals with different forms of DEB. A 7-year-old girl was diagnosed with bullous disease of the newborn (BDN) based on a history of generalized blistering at birth, which healed with minimal scarring and only occasional milia. The frequency of blistering decreased with age and had completely ceased by the age of 4 months. No subsequent blistering occurred. She was shown to be heterozygous for p.Gly1483Asp; identification of this dominant mutation was published in 2009 (18). However, a seemingly unrelated 16-month-old Kuwaiti child was found to be homozygous for this mutation. Fragility of the skin was noted soon after birth, with spontaneous blistering on the hands, trunk and extremities, which healed with minimal scarring but some milia formation. A few oral erosions and occasional periungual blistering were also present. There was some reduction in blistering severity with age, but new lesions continued to develop. The underlying diagnosis therefore was mild generalized recessive DEB. Neither of his parents, who were both shown to be heterozygous for this GS, had any clinical abnormalities. Two further individuals, a 17-year-old brother and a 23-year-old sister of Kuwaiti origin, who were not known to be related to the other cases, had generalized blistering at birth with recurrent oral ulcers. There was persistent skin fragility and oral erosions with gingival inflammation. Scattered albopapuloid lesions were noted on the chest, trunk and upper back. Nail dystrophy with loss of several fingernails and toe-

nails was present, consistent with moderately severe generalized recessive DEB. Both individuals were homozygous for p.Gly1483Asp. Their parents were heterozygous carriers of this GS mutation but were clinically unaffected with no blistering, milia, abnormal scarring or nail dystrophy.

### Dominant and recessive mutation: *p.Gly1770Ser*

The mutation p.Gly1770Ser also resulted in a variable phenotype (Fig. 1). This mutation has not been reported previously, although a substitution by a different amino acid, p.Gly1770Asp, on one allele has been found in a case of autosomal dominant EB pruriginosa (18). In a Pakistani family three children were observed to have generalized skin fragility with oral erosions. Wound healing was poor and scarring ensued. The features were consistent with severe generalized recessive DEB. Of these three affected individuals, two subjects (aged 1 year and 4 years) were brothers, whereas the other (aged 9 months) was a distant cousin. All three children were shown to be homozygous for p.Gly1770Ser, consistent with this being a recessive GS. However the parents of the two affected brothers both showed phenotypic abnormalities. Their DNA revealed heterozygosity for p.Gly1770Ser. The heterozygous father had nail dystrophy, but no skin blistering, whereas the heterozygous mother had nail dystrophy, blistering and inflammation on her shins consistent with pretibial DEB. Thus in these individuals heterozygosity for p.Gly1770Ser appeared to be acting as a dominant mutation with features of nail dystrophy or pretibial dominant DEB. By contrast the parents of the affected 9-month-old child were also heterozygous for p.Gly1770Ser, but neither of them had any phenotypic abnormalities. Thus, in both these individuals this particular GS appeared to function as a recessive allele that was silent in the heterozygous state.

### Dominant and recessive mutation: *p.Gly2213Arg*

The mutation p.Gly2213Arg can also be associated with dominant or recessive forms of DEB (Fig. 2). A 45-year-old British woman with blistering and itching affecting the lower legs since the age of 37 years had scattered blisters and prurigo-like lesions on her shins consistent with a diagnosis of EB pruriginosa. DNA screening showed heterozygosity for the GS p.Gly2213Arg, but no other mutation was identified, leading to the diagnosis of a dominant form of dominant DEB; details of this case have been published previously (18). However, an unrelated 24-year-old British man was also shown to possess this mutation. He had generalized blistering affecting the skin, eyes and oral mucosa with some scarring. The phenotype was consistent with moderately severe generalized recessive DEB. DNA screening showed heterozygosity

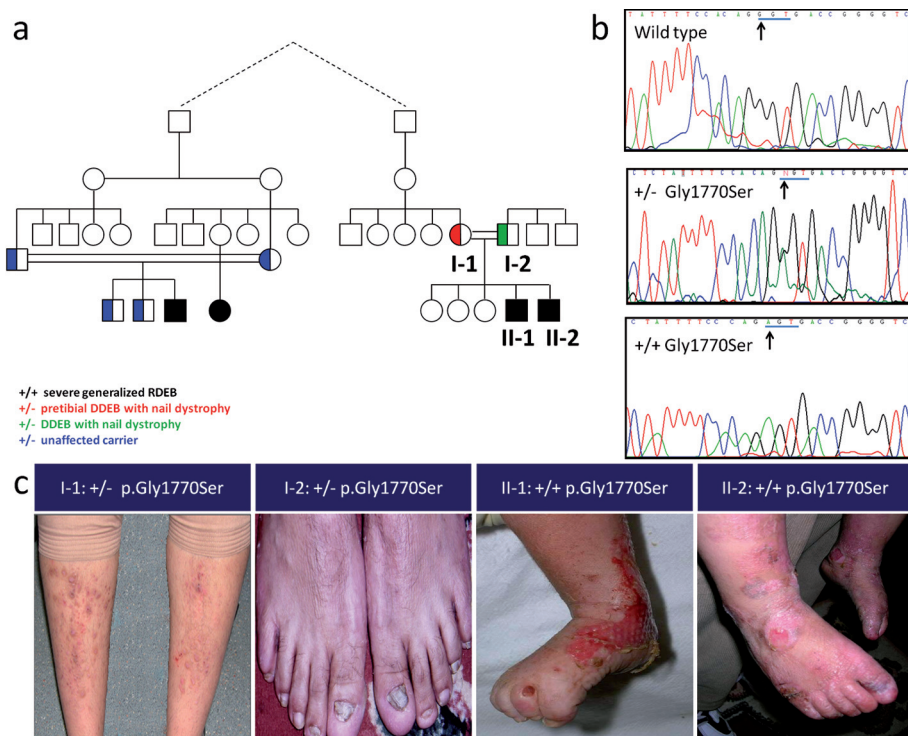


Fig. 1. The glycine mutation p.Gly1770Ser leads to both dominant and recessive disease in two distantly related Pakistani pedigrees. (a) Pedigree shows the presence/absence of dominant or recessive disease in relation to the genotype. (b) DNA sequencing shows heterozygosity or homozygosity for the mutation p.Gly1770Ser in type VII collagen. (c) Clinical illustration of family members showing varying degrees of skin fragility, nail dystrophy and scarring.

for p.Gly2213Arg, but this mutation had been inherited *in trans* with the frameshift mutation c.4918delG (p.Gly1640fsX69), consistent with recessive DEB. Neither of his parents, including the carrier of the GS, had any clinical abnormalities.

*Dominant and recessive mutation: p.Gly2369Ser*

The mutation p.Gly2369Ser can also result in dominant or recessive DEB. A 49-year-old Pakistani man had a history of blistering and scarring with itching affecting his forearms, shins, hands and feet; he also had nail dystrophy. Examination showed extensive lichenified prurigo-like lesions consistent with EB pruriginosa. DNA screening showed heterozygosity for the mutation p.Gly2369Ser, but no other mutation was identified and he was therefore considered to have dominant DEB, details, of which were reported previously (19). However, this mutation was also detected in an unrelated 6-year-old British girl who presented with generalized skin fragility with scattered blisters, especially around the ankles and knees; blistering also affected the oral mucosa. Progressive flexion contractures and webbing of her fingers were present, consistent with severe generalized recessive DEB. DNA screening revealed homozygosity for the mutation p.Gly2369Ser, confirming a recessive form of DEB. Her parents were both shown to be heterozygous carriers of this mutation, but neither had any clinical

abnormalities, including signs of nail dystrophy, in contrast to the previously reported heterozygous individual.

*Database of dominant and recessive GS mutations in type VII collagen*

In this study we noted that some GS mutations in type VII collagen (p.Gly1483Asp, p.Gly1770Ser, p.Gly2213Arg and p.Gly2369Ser) may function in a dominant or recessive manner. This observation has also been reported for some other GS mutations, namely p.Gly1595Arg, p.Gly1815Arg, p.Gly2028Arg, p.Gly2028Trp, p.Gly2210Val, p.Gly2251Glu, p.Gly2287Arg and p.Gly2351Arg (7–15) (Table I). With regards to the previous reports, it is clear that, similar to the new mutations we identified, these atypical GS mutations are associated with diverse clinical and genetic consequences.

Collectively, these type VII collagen GS mutations that can underlie both dominant and recessive forms of DEB (Table I) comprise <10% of all GS within this particular collagen, the remainder being almost evenly split between dominant and recessive cases of DEB (see Tables SI and SII). A key question, however, is whether there is anything

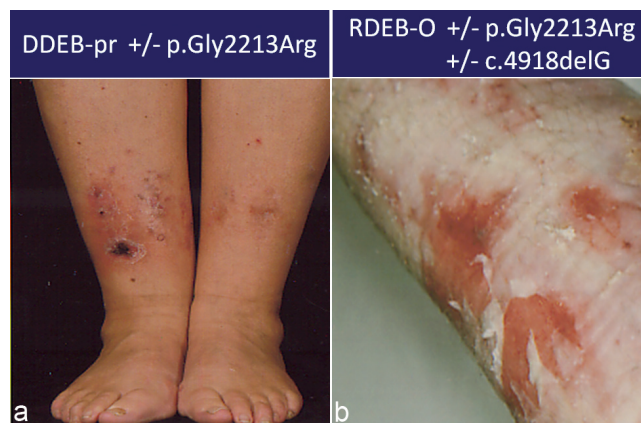


Fig. 2. The glycine mutation p.Gly2213Arg leads to both dominant and recessive disease in two unrelated white Caucasians. (a) Clinical illustration of an individual, heterozygous for p.Gly2213Arg, with itchy skin and blisters on the shins and a diagnosis of dominant dystrophic epidermolysis bullosa-pruriginosa (DDEB-pr). (b) The other individual is a compound heterozygote for p.Gly2213Arg and a frameshift mutation in COL7A1 resulting in recessive DEB–other (RDEB-O); there is more extensive skin fragility and scarring, illustrated here on the leg.

Table I. COL7A1 glycine substitution mutations with both dominant and recessive inheritance

Diagnosis	Dominant	Exon	Recessive	Diagnosis	Reference
DDEB-BDN, asymptomatic carrier	p.Gly1483Asp	42	<b>p.Gly1483Asp/p.Gly1483Asp</b>	RDEB-O	(18); <b>This paper</b>
DDEB-na	p.Gly1595Arg	50	p.Gly1595Arg/p.Cys2827Stop	RDEB-O	(11)
DDEB-na, asymptomatic carrier, DDEB-pt	p.Gly1770Ser	61	<b>p.Gly1770Ser/p.Gly1770Ser</b>	RDEB-sev gen	<b>This paper</b>
DDEB-na	p.Gly1815Arg	63	p.Gly1815Arg/c.5818delC	RDEB-O	(11)
DDEB-gen, DDEB-pr, DDEB-na	p.Gly2028Arg	73	p.Gly2028Arg/c.1661del57 or p.Gly1580Asp+p.Pro2438Leu	RDEB-sev gen	(10, 12, 13, 14)
DDEB-gen	p.Gly2028Trp	73	p.Gly2028Trp/c.8698del11	RDEB-O	(12)
DDEB-pr, DDEB-gen	p.Gly2210Val <sup>a</sup>	83	p.Gly2210Val/p.Arg2791Trp	RDEB-sev gen	(12, 15)
DDEB-pr, asymptomatic carrier	p.Gly2213Arg	83	<b>p.Gly2213Arg/c.4918delG</b>	RDEB-O	(18); <b>This paper</b>
DDEB-na	p.Gly2251Glu	86	p.Gly2251Glu/p.Gly1519Asp	RDEB-BDN	(8)
DDEB-na	p.Gly2287Arg	87	p.Gly2287Arg/p.Gly2316Arg	RDEB-O	(9)
DDEB-gen	p.Gly2351Arg	91	p.Gly2351Arg/c.5103delCCinsG	RDEB-sev gen	(7)
DDEB-pr, asymptomatic carrier	p.Gly2369Ser	93	<b>p.Gly2369Ser/p.Gly2369Ser</b>	RDEB-sev gen	(19); <b>This paper</b>

DDEB: dominant dystrophic epidermolysis bullosa; BDN: bullous dermolysis of the newborn; DDEB-gen: generalized; DDEB-na: nails only; DDEB-pr: pruriginosa; DDEB-pt: pretibial; RDEB: recessive dystrophic epidermolysis bullosa; RDEB-sev gen: severe generalized; RDEB-O: other; **bold**: new mutations.

<sup>a</sup>Inherited with the missense mutation p.Arg2791Trp on the same allele (15).

specific about the nature of a particular GS in type VII collagen that might have implications for the genotype and genetic counselling. Such characteristics might include: the nature of the substituted amino acid, the position of the GS in the triple helix, the proximity of the GS to the non-helical hinge region in the triple helix or the non-collagenous NC-1 or NC-2 domains, unpredicted consequences of the nucleotide substitution on splicing, as well as biochemical changes to the collagen affecting helix formation, protein folding, thermal stability, intracellular transport, secretion, and assembly into anti-parallel dimers or anchoring fibrils (6–8, 10, 11, 20–29). Assessment of the data in Tables SI and SII, however, shows no clear indication of which particular mutations are likely to be dominant or recessive, an interpretation reinforced by the identification of the 12 specific type VII collagen GS mutations that can be either dominant or recessive (Table I). In addition, amino acid substitutions in glycines 1522, 2009, 2061, 2073, 2233, 2366, 2623 and 2719 may all cause dominant or recessive disease, but with different substituting residues in the different disease subtypes. There does not appear to be any specific differences in males or females with regards to phenotype. Clinical heterogeneity within a specific genotype may reflect influences such as functional polymorphisms within genes such as the matrix metalloproteinase 1 promoter (30), but this cannot impact on whether the inheritance pattern is in fact dominant or recessive.

For investigators screening for COL7A1 gene pathology who identify a GS mutation, we recommend cross-referencing with the data presented in our three Tables. This information is likely to provide an accurate guide to interpreting the genotype, although it is possible that further patient data may shift more of the GS mutations from either the dominant or recessive GS lists into the group of mixed GS mutations. In all cases of DEB, we recommend comprehensive screening of the COL7A1

gene and not curtailing the sequencing work once a “possible” dominant GS mutation has been identified. Such an approach is likely to reveal more examples of recessive GS mutations as well as mixed-type pathology.

#### ACKNOWLEDGEMENTS

N.A. is a clinical research fellow supported by the Dystrophic Epidermolysis Bullosa Research Association (DebRA, UK). We acknowledge financial support from the Department of Health via the National Institute for Health Research (NIHR) comprehensive Biomedical Research Centre award to Guy’s and St Thomas’ NHS Foundation Trust in partnership with King’s College London and King’s College Hospital NHS Foundation Trust.

*The authors declare no conflicts of interest.*

#### REFERENCES

1. Fine JD, Eady RA, Bauer EA, Bauer JW, Bruckner-Tuderman L, Heagerty A, et al. The classification of inherited epidermolysis bullosa (EB): report of the Third International Consensus Meeting on Diagnosis and Classification of EB. *J Am Acad Dermatol* 2008; 58: 931–950.
2. McGrath JA, Ishida-Yamamoto A, O’Grady A, Leigh IM, Eady RA. Structural variations in anchoring fibrils in dystrophic epidermolysis bullosa: correlation with type VII collagen expression. *J Invest Dermatol* 1993; 100: 366–372.
3. Uitto J, Pulkkinen L, Christiano AM. Molecular basis of the dystrophic and junctional forms of epidermolysis bullosa: mutations in the type VII collagen and kalinin (laminin 5) genes. *J Invest Dermatol* 1994; 103: 39S–46S.
4. Whittock NV, Ashton GH, Mohammadi R, Mellerio JE, Mathew CG, Abbs SJ, et al. Comparative mutation detection screening of the type VII collagen gene (COL7A1) using the protein truncation test, fluorescent chemical cleavage of mismatch, and conformation sensitive gel electrophoresis. *J Invest Dermatol* 1999; 113: 673–686.
5. Dang N, Murrell DF. Mutation analysis and characterization of COL7A1 mutations in dystrophic epidermolysis bullosa. *Exp Dermatol* 2008; 17: 553–568.
6. Shimizu H, McGrath JA, Christiano AM, Nishikawa T,

- Uitto J. Molecular basis of recessive dystrophic epidermolysis bullosa: genotype/phenotype correlation in a case of moderate clinical severity. *J Invest Dermatol* 1996; 106: 119–124.
7. Christiano AM, Anton-Lamprecht I, Amano S, Ebschner U, Burgeson RE, Uitto J. Compound heterozygosity for COL7A1 mutations in twins with dystrophic epidermolysis bullosa: a recessive paternal deletion/insertion mutation and a dominant negative maternal glycine substitution result in a severe phenotype. *Am J Hum Genet* 1996; 58: 682–693.
  8. Hammami-Hauasli N, Raghunath M, Küster W, Bruckner-Tuderman L. Transient bullous dermolysis of the newborn associated with compound heterozygosity for recessive and dominant COL7A1 mutations. *J Invest Dermatol* 1998; 111: 1214–1219.
  9. Shimizu H, Hammami-Hauasli N, Hatta N, Nishikawa T, Bruckner-Tuderman L. Compound heterozygosity for silent and dominant glycine substitution mutations in COL7A1 leads to a marked transient intracytoplasmic retention of procollagen VII and a moderately severe dystrophic epidermolysis bullosa phenotype. *J Invest Dermatol* 1999; 113: 419–421.
  10. Lee JY, Li C, Chao SC, Pulkkinen L, Uitto J. A de novo glycine substitution mutation in the collagenous domain of COL7A1 in dominant dystrophic epidermolysis bullosa. *Arch Dermatol Res* 2000; 292: 159–163.
  11. Sato-Matsumura KC, Yasukawa K, Tomita Y, Shimizu H. Toenail dystrophy with COL7A1 glycine substitution mutations segregates as an autosomal dominant trait in 2 families with dystrophic epidermolysis bullosa. *Arch Dermatol* 2002; 138: 269–271.
  12. Varki R, Sadowski S, Uitto J, Pfenninger E. Epidermolysis bullosa. II. Type VII collagen mutations and phenotype-genotype correlations in the dystrophic subtypes. *J Med Genet* 2007; 44: 181–192.
  13. Murata T, Masunaga T, Shimizu H, Takizawa Y, Ishiko A, Hatta N, et al. Glycine substitution mutations by different amino acids in the same codon of COL7A1 lead to heterogeneous clinical phenotypes of dominant dystrophic epidermolysis bullosa. *Arch Dermatol Res* 2000; 292: 477–481.
  14. Nakamura H, Sawamura D, Goto M, Sato-Matsumura KC, LaDuca J, Lee JY, et al. The G2028R glycine substitution mutation in COL7A1 leads to marked inter-familial clinical heterogeneity in dominant dystrophic epidermolysis bullosa. *Dermatol Sci* 2004; 34: 195–200.
  15. Dang N, Klingberg S, Marr P, Murrell DF. Review of collagen VII sequence variants found in Australasian patients with dystrophic epidermolysis bullosa reveals nine novel COL7A1 variants. *J Dermatol Sci* 2007; 46: 169–178.
  16. Sambrook J, Fritsch EF, Maniatis T, editors. *Molecular cloning. A laboratory manual*. Cold Spring Harbor, NY: Cold Spring Harbor Laboratory Press, 1989.
  17. Christiano AM, Hoffman GG, Zhang X, Xu Y, Tamai Y, Greenspan DS, Uitto J. Strategy for identification of sequence variants in COL7A1 and a novel 2-bp deletion mutation in recessive dystrophic epidermolysis bullosa. *Hum Mutat* 1997; 10: 408–414.
  18. Almaani N, Liu L, Harrison N, Tanaka A, Lai-Cheong J, Mellerio JE, et al. New glycine substitution mutations in type VII collagen underlying epidermolysis bullosa pruriginosa but the phenotype is not explained by a common polymorphism in the matrix metalloproteinase-1 gene promoter. *Acta Derm Venereol* 2009; 89: 6–11.
  19. Mellerio JE, Ashton GH, Mohammadi R, Lyon CC, Kirby B, Harman KE, et al. Allelic heterogeneity of dominant and recessive COL7A1 mutations underlying epidermolysis bullosa pruriginosa. *J Invest Dermatol* 1999; 112: 984–987.
  20. Hammami-Hauasli N, Schumann H, Raghunath M, Kilgus O, Lüthi U, Luger T, et al. Some, but not all, glycine substitution mutations in COL7A1 result in intracellular accumulation of collagen VII, loss of anchoring fibrils, and skin blistering. *J Biol Chem* 1998; 273: 19228–19234.
  21. Hovnanian A, Rochat A, Bodemer C, Petit E, Rivers CA, Prost C, et al. Characterization of 18 new mutations in COL7A1 in recessive dystrophic epidermolysis bullosa provides evidence for distinct molecular mechanisms underlying defective anchoring fibril formation. *Am J Hum Genet* 1997; 61: 599–610.
  22. Kern JS, Kohlhase J, Bruckner-Tuderman L, Has C. Expanding the COL7A1 mutation database: novel and recurrent mutations and unusual genotype-phenotype constellations in 41 patients with dystrophic epidermolysis bullosa. *J Invest Dermatol* 2006; 126: 1006–1012.
  23. Chiaverini C, Charlesworth AV, Youssef M, Cuny JF, Rabia SH, Lacour JP, et al. Inversa dystrophic epidermolysis bullosa is caused by missense mutations at specific positions of the collagenic domain of collagen type VII. *J Invest Dermatol* 2010; 130: 2508–2511.
  24. Chen M, Keene DR, Costa FK, Tahk SH, Woodley DT. The carboxyl terminus of type VII collagen mediates antiparallel dimer formation and constitutes a new antigenic epitope for epidermolysis bullosa acquisita autoantibodies. *J Biol Chem* 2001; 276: 21649–21655.
  25. Chen M, Costa FK, Lindvay CR, Han YP, Woodley DT. The recombinant expression of full-length type VII collagen and characterization of molecular mechanisms underlying dystrophic epidermolysis bullosa. *J Biol Chem* 2002; 277: 2118–2124.
  26. Brittingham R, Colombo M, Ito H, Steplewski A, Birk DE, Uitto J, et al. Single amino acid substitutions in procollagen VII affect early stages of assembly of anchoring fibrils. *J Biol Chem* 2005; 280: 191–198.
  27. Hyde TJ, Bryan MA, Brodsky B, Baum J. Sequence dependence of renucleation after a Gly mutation in model collagen peptides. *J Biol Chem* 2006; 281: 36937–36943.
  28. Fritsch A, Spassov S, Elfert S, Schlosser A, Gache Y, Meneguzzi G, et al. Dominant-negative effects of COL7A1 mutations can be rescued by controlled overexpression of normal collagen VII. *J Biol Chem* 2009; 284: 30248–30256.
  29. Woodley DT, Hou Y, Martin S, Li W, Chen M. Characterization of molecular mechanisms underlying mutations in dystrophic epidermolysis bullosa using site-directed mutagenesis. *J Biol Chem* 2008; 283: 17838–17845.
  30. Titeux M, Pendaries V, Tonasso L, Décha A, Bodemer C, Hovnanian A. A frequent functional SNP in the MMP1 promoter is associated with higher disease severity in recessive dystrophic epidermolysis bullosa. *Hum Mutat* 2008; 29: 267–276.