

QUIZ SECTION

A Pregnant Woman with a Nodule on the Tongue: A Quiz

Salvador Arias-Santiago¹, José Aneiros-Fernández², Jacinto Orgaz-Molina¹, María Antonia Fernández-Pugnaire¹, María Sierra Girón-Prieto¹, Ramon Naranjo-Sintes¹ and Jose Aneiros-Cachaza¹

Departments of ¹Dermatology and ²Pathology, San Cecilio University Hospital, Av Dr. Oloriz 16, ES-18012 Granada, Spain. E-mail: salvadorarias@hotmail.es

A 34-year-old woman, in her fourth month of pregnancy, presented with an isolated exophytic lesion of the tongue, which had developed 2 months previously and which caused discomfort when swallowing. On examination, we found a pink nodule (diameter 15 mm) of hard consistency on the dorsum of the tongue (Fig. 1A). A cutaneous examination revealed nothing abnormal. Analysis of a biopsy sample

revealed multiple separate vascular lobules within the dermis, each composed of aggregates of endothelial cells (Fig. 1B). Cells were positive for CD34 (Fig. 1C), and negative for Factor VIII, HHV-8 and androgen, estrogen and progesterone receptors.

What is your diagnosis? See next page for answer.

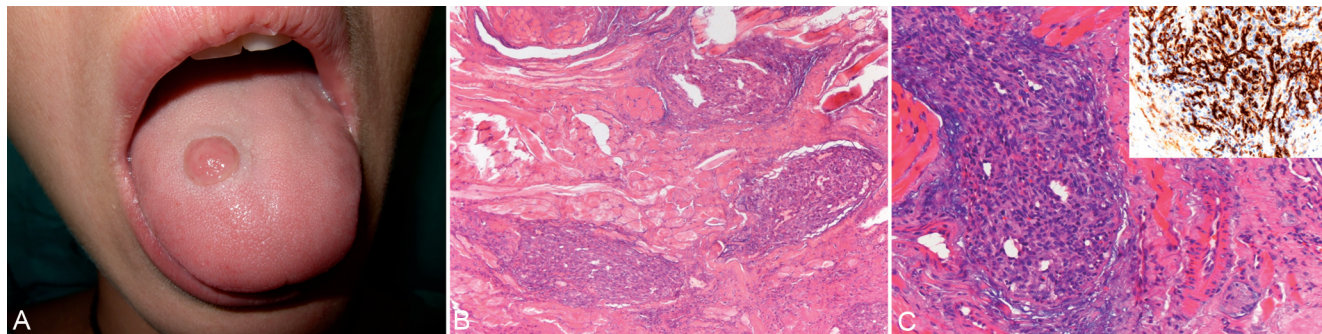


Fig. 1. (A) A 15-mm pink nodule of hard consistency on the dorsum of the tongue. (B and C) Vascular lobules, comprising endothelial cell aggregates, in the dermis (haematoxylin and eosin). C Inset. More than 90% of cells were positive for CD34.

doi: 10.2340/00015555-1019

ANSWERS TO QUIZ

A Pregnant Woman with a Nodule on the Tongue: Comment

Acta Derm Venereol 2011; 91: XX–XX

Diagnosis: Lobular capillary haemangioma (pyogenic granuloma)

Lobular capillary haemangioma (pyogenic granuloma) is a very common benign vascular lesion that has been considered a hyperplastic condition or vascular neoplasm. Lesions typically present as red or bluish papules or polyps that bleed easily. An homogenous reddish area surrounded by a white collarette is found in the majority of cases. Lesions may arise at any age in both sexes and most commonly occur in the head and neck (especially in mucous membranes) and limbs. They preferentially affect the lips, gingiva, mucosa, nose, fingers and face (1). However, there have been very few reports of these tumours affecting the tongue (2). Pyogenic granuloma is especially common in children and young adults. Congenital lesions are uncommon (3). Multiple lesions in the trunk are common in adolescents and young adults after electrodesiccation or surgical removal of the first lesion, and have been associated with the use of certain drugs, including isotretinoin therapy (4). Lesions often appear as a result of hormonal factors and have, for example, been linked to pregnancy and the use of contraceptive pills. Gingival lesions that develop during pregnancy are known as *granuloma gravidarum* and involute after delivery. Histologically, lesions display a lobular pattern with fibrous septa. Each lobule comprises aggregates of capillaries and venules lined by plump endothelial cells. Re-epithelialization of the surface and peripheral hyperplastic adnexal epithelioid collarettes may be noted. Surgical excision and the combination of electrodesiccation and curettage have been successfully used to treat pyogenic granuloma. In the

present case, the lesion caused discomfort when swallowing and was surgically excised. However, pyogenic granuloma during pregnancy often regresses spontaneously. Pyogenic granulomas with satellitosis that recur after surgical excision have been found to respond to intralesional and systemic steroid treatment (5). Other therapeutic options include imiquimod (6), alitretinoin gel, erythromycin and intralesional bleomycin (7).

The authors declare no conflict of interest.

REFERENCES

- Harris MN, Desai R, Chuang TY, Hood AF, Mirowski GW. Lobular capillary hemangiomas: an epidemiologic report, with emphasis on cutaneous lesions. *J Am Acad Dermatol* 2000; 42: 1012–1016.
- Al-Omari B, Keogh I, Waheed K, Hughes J, Timo C. Lingual granuloma of pregnancy. *Rev Laryngol Oto Rhinol (Bord)* 2008; 129: 345–346.
- Ogunleye AO, Nwaorgu OG. Pyogenic granuloma, a cause of congenital nasal mass: case report. *Ann Trop Paediatr* 2000; 20: 137–139.
- Hagler J, Hodak E, David M, Sandbank M. Facial pyogenic granuloma-like lesions under isotretinoin therapy. *Int J Dermatol* 1992; 31: 199–200.
- Tursen U, Demirkan F, Ikizoglu G. Giant recurrent pyogenic granuloma on the face with satellitosis responsive to systemic steroids. *Clin Exp Dermatol* 2004; 29: 40–41.
- Tritton SM, Smith S, Wong LC, Zagarella S, Fischer G. Pyogenic granuloma in ten children treated with topical imiquimod. *Pediatr Dermatol* 2009; 26: 269–272.
- Daya M. Complete resolution of a recurrent giant pyogenic granuloma on the palm of the hand following single dose of intralesional bleomycin injection. *J Plast Reconstr Aesthet Surg* 2010; 63: e331–333.