

## Organised Angular Cheilitis as the Initial Sign of Crohn's Disease in Two Children

Nannie Bangsgaard<sup>1</sup>, Birgitte Weile<sup>2</sup> and Lone Skov<sup>1</sup>

<sup>1</sup>Department of Dermato-allergology, Copenhagen University Hospital Gentofte, DK-2900 Hellerup, <sup>2</sup>Department of Paediatrics, The Juliane Marie Centre, University of Copenhagen, Denmark. E-mail: nanban01@geh.regionh.dk  
Accepted September 2, 2010.

Mucocutaneous lesions are relatively common during the course of Crohn's disease (CD) (1). Orofacial lesions, presenting as the initial sign of CD in children, are uncommon but can be an important clue in the diagnosis of CD before the development of gastrointestinal symptoms (2). We highlight the need for increased awareness of the possibility that children with organised angular cheilitis may have CD, in order to avoid delays in diagnosis.

### CASE REPORTS

*Case 1.* A ten-year-old boy presented to our dermatological clinic with a two-year history of recurrent angular fissures. Over time, chronic organised angular cheilitis had developed with indurated, erythematous plaques on the cheeks (Fig. 1A). The boy had a history of mild atopic dermatitis and the lesions were initially diagnosed as such. On suspicion of allergy, he underwent skin prick testing and patch testing, the results of which were negative. Repeated skin cultures were negative for bacteria, viruses and fungi. Treatment with antibiotic, steroid cream and tacrolimus was unrewarding. Histological assessment of a skin biopsy revealed epithelial hyperplasia, hyperkeratosis and marked unspecific inflammation. No granulomas were found. There were no other complaints at presentation, notably none of lip swelling or gastro-

intestinal symptoms. The patient's family history contained no mention of CD. Physical examination revealed an apparently healthy boy. Height and weight percentiles were above median values, but, due to the fact that his parents were tall, his height was below target. The results of a clinical examination were unremarkable, except for an asymptomatic anal skin tag. Serological examination revealed only slight zinc deficiency.

During follow-up, the boy developed daily abdominal pain and loose stool. Endoscopy revealed changes in the colon and ileum consistent with CD. The diagnosis was confirmed histologically by the presence of aphthous and granulomatous inflammation. The boy was referred to a paediatric gastroenterological department for further evaluation, and treatment with Imurel (50 mg daily) was instituted. A treatment effect of skin changes was noted. These changes worsened over time, as did the intestinal symptoms. Treatment with biologics was being considered at the time of writing.

*Case 2.* A nine-year-old girl presented to the clinic with a two-year history of recurrent bilateral angular cheilitis. Her condition was now chronic and had developed into organised, indurated erythematous plaques on the cheeks (Fig. 1B). She had a history of mild atopic dermatitis and, as in case 1, her lesions were initially diagnosed as such. Suspecting allergy, we performed skin prick testing and patch testing with negative results. Repeated bacterial, viral and fungal cultures were negative. The lesions were treated with topical steroid with some effect, but with instant flare-up on withdrawal of treatment.

The girl had no gastrointestinal symptoms and no family history of CD. Physical examination revealed a healthy girl with normal height and weight curves. Serological testing was normal, without signs of malabsorption. The results of a clinical examination were unremarkable, except for asymptomatic anal skin tags and discrete signs of thickening of the oral mucosa. An oral biopsy, as well as gastroscopy and colonoscopy, was performed under general anaesthesia. Endoscopy produced no abnormal findings. However, histological analysis of anal skin tags revealed non-caseous granulomatous inflammation, while the oral biopsy showed inflammation, with epithelioid granulomas and giant cell granulomata. A biopsy sample from the skin affected by angular cheilitis contained no granulomas.

During the course of follow-up, the girl developed extensive hyperplastic oral lesions and bilateral erythema of the gingival and buccal mucosa, along with lip swelling. She still suffered no gastrointestinal symptoms. She was treated with oral prednisolone (50 mg daily) and metronidazole (250 mg, 3 times daily), which together cleared the lesions. On withdrawal of treatment, the lesions reappeared, but could be controlled by topical steroid treatment.

### DISCUSSION

Mucocutaneous lesions represent the most frequent extraintestinal manifestation of CD and may be divided into three groups: 1, specific lesions, in which there is direct involvement of mucous membranes or skin by the same disease process as in CD (contiguous or metastatic); 2, non-specific, reactive skin disease such

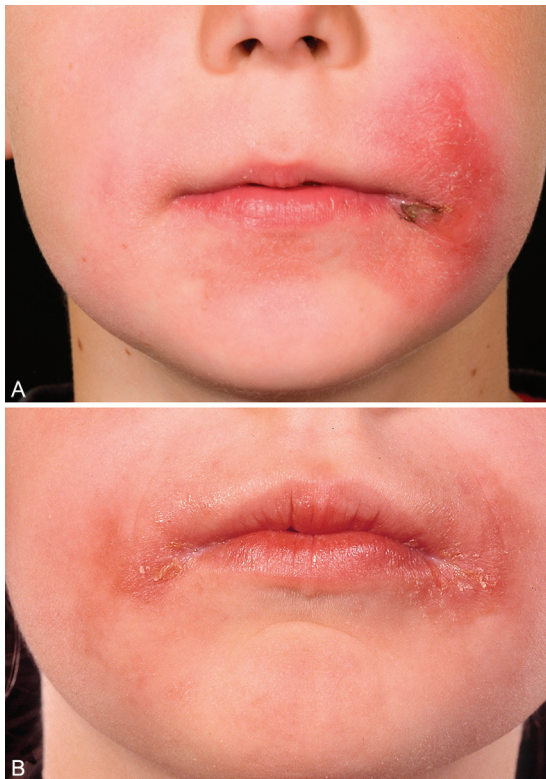


Fig. 1. Organised angular cheilitis in a ten-year-old boy (A) and a nine-year-old girl (B).

as erythema nodosum, pyoderma gangrenosum and pustular eruptions; and 3, mucocutaneous manifestations secondary to nutritional deficiency (3, 4).

The facial eruptions in our two cases were histologically non-specific without granulomas and may be classified as reactive. However, since granulomas can be very discrete, it is possible that the lesions are in fact a specific manifestation of CD. In both cases, we describe organised angular cheilitis as the initial manifestation of CD.

Scully et al. (5) described oral manifestation in 19 patients without historical evidence of gastrointestinal disease. In addition to swelling, "cobblestoning" and ulcers, angular cheilitis was present in 7/19 cases. Only one of these presented with no additional swelling, as was the case in our two patients. The authors describe one patient in whom, like our two patients, no granulomas were detected. Furthermore, Tyldesley (6) described seven patients with oral lesions only. All presented with swollen lips, angular cheilitis, buccal lesions and palpable nodes. The girl we describe in case 2 developed orofacial granulomatosis. Typified by recurrent or persistent swelling of the lips, cheeks, gingiva and/or oral mucosa, and the identification of granulomas in histological analyses, this presentation has been described as a separate entity as well as a feature of CD (7). Our patient displayed no gastrointestinal symptoms or signs of CD in endoscopic evaluation, but the finding of granulomas in her anal skin tags supports the diagnosis CD. Because of the atypical initial presentation of organised angular cheilitis without lip swelling, the diagnosis of CD was delayed for several years in both children.

When confronted with a child with organised angular cheilitis, with or without lip swelling, it is important to consider the diagnosis of CD. The patient's medical

history should be checked thoroughly and other physical signs of CD, such as asymptomatic genital or perianal lesions, sought. Although not uncommon in otherwise healthy children, some 25–30% of patients with CD show perianal lesions before gastrointestinal complaints (8). A systematic oral examination, involving the sub-mandibular lymph nodes, lips, labial mucosa and sulci, commissures, buccal mucosa and sulci, gingiva, tongue, floor of the mouth and hard and soft palates, should be performed in children with suspected CD.

#### ACKNOWLEDGEMENT

We are indebted to clinical photographer Helene Ryttersgaard.

#### REFERENCES

1. Basu MK, Asquith P. Oral manifestations of inflammatory bowel disease. *Clin Gastroenterol* 1980; 9: 307–321.
2. Ploysangam T, Heubi JE, Eisen D, Balistreri WF, Lucky AW. Cutaneous Crohn's disease in children. *J Am Acad Dermatol* 1997; 36: 697–704.
3. Berkowitz EZ, Lebwohl M. Cutaneous manifestations of inflammatory bowel disease. *J Eur Acad Dermatol Venereol* 2000; 14: 349–350.
4. Lebwohl M, Lebwohl O. Cutaneous manifestations of inflammatory bowel disease. *Inflamm Bowel Dis* 1998; 4: 142–148.
5. Scully C, Cochran KM, Russell RI, Ferguson MM, Ghouri MAK, Lee FD, et al. Crohn's disease of the mouth: an indicator of intestinal involvement. *Gut* 1982; 23: 198–201.
6. Tyldesley WR. Oral Crohn's disease and related conditions. *Br J Oral Surg* 1979; 17: 1–9.
7. Khouri JM, Bohane TD, Day AS. Is orofacial granulomatosis in children a feature of Crohn's disease? *Acta Pediatr* 2005; 94: 501–504.
8. Baker WN, Milton-Thompson GJ. The anal lesion as the sole presenting symptom of intestinal Crohn's disease. *Gut* 1971; 12: 865.