

Oral and Oesophageal Lichen Planus Following Radiotherapy of Nasopharyngeal Carcinoma

Yi Na Wang¹, Hong Chao Chen¹, Bo Wang² and Hong Fang^{1*}

Departments of ¹Dermatology and ²Pathology, First Affiliated Hospital, Zhejiang University School of Medicine, Hangzhou, 310003, China. *E-mail: fanghongzy@sina.com

Accepted June 12, 2010.

Oral lichen planus is a relatively frequent inflammatory mucocutaneous disease of middle-aged patients, affecting approximately 1.27% of the world population (1). Oesophageal lichen planus accounts for approximately 1% of cases (2), and is often unidentified due to its rarity. The association with other immune diseases and the damage to the basal keratinocytes in lichen planus supports an autoimmune aetiology mediated by autocytotoxic T cells (3). Although generalized lichen planus induced by radiation therapy has been described previously (4, 5), to our knowledge, there have been no previous reports of lichen planus with concomitant oral and oesophageal mucosa involvement following radiotherapy.

CASE REPORT

A 46-year-old Chinese man with a history of early-stage nasopharyngeal carcinoma (histologically proven stage I according to the American Joint Committee on Cancer Staging/ International Union Against Cancer (AJC/UICC) staging system, undifferentiated carcinoma) but no known autoimmune disease received definitive radiotherapy in the First Affiliated Hospital, Zhejiang University School of Medicine, Hangzhou, China, in February 2009. The patient was treated with a conventional external radiotherapy regime of five fractions per week, 1.8 Gy per fraction. After 26 fractions, radiation to the primary tumour area was boosted using a 10 Mv beam, providing 20 Gy in 12 fractions. The radiotherapy lasted for 6 weeks and the total external dose reached 66.8 Gy. An ear nose and throat (ENT) examination, head and neck computed tomography (CT) and magnetic resonance imaging (MRI) scans performed 2 weeks later confirmed complete local control of the nasopharyngeal carcinoma.

Two months after radiotherapy, the patient was noted to have developed white plaques on his lower lip. These plaques slowly enlarged and the upper lip was affected over the next month (Fig. 1). No concurrent lesions were observed on the buccal mucosa, tongue, genital mucosa, skin, scalp, nails or conjunctivae. The

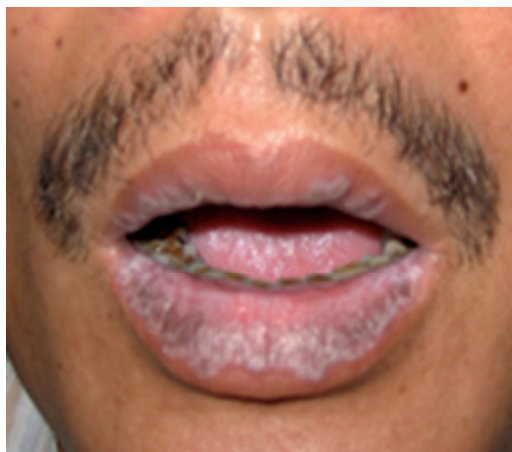

Fig. 1. Irregular plaques with white lacy streaks on the upper and lower lips.

patient also reported emaciation (approximately 18 kg weight loss during 3 months), dysphagia and odynophagia. A skin biopsy was performed on the site of lower lip lesion. Microscopy revealed a dense, band-like infiltration of lymphocytes under the epithelium, and liquefactive degeneration of the basal cells. These histological findings and the typical clinical lesions of reticular papules led to the diagnosis of oral lichen planus (6). Further investigations were carried out to detect any associated diseases, such as thyroid disease, AIDS, diabetes mellitus, arterial hypertension, and chronic viral hepatitis. Routine blood examination was normal and circulating anti-skin antibodies were not detected. Culture for fungi was negative. Thyroid antibodies, anti-human immunodeficiency virus, anti-hepatitis C virus and hepatitis B surface antigen were negative. Increased numbers of CD8+ and CD4+ T lymphocytes were detected in the patient's peripheral blood (34% and 52%, normal range 20–30% and 40–50%, respectively). Barium swallow showed a stricture in the upper oesophagus (Fig. 2a), and endoscopic examination revealed a proximal stricture and a thin white pseudomembrane with ulcerative oesophagitis (Fig. 2b). Biopsies taken from the stricture showed marked epithelial detachment, and the mucosa could easily be stripped away. Histological examination demonstrated a mild chronic oesophagitis with infiltration of lymphocytes, and reflux oesophagitis was initially diagnosed. However, 3 weeks of treatment with proton pump inhibitors resulted in no improvement in the gastrointestinal discomfort. Diagnosis of oesophageal lichen planus concomitant with oral lichen planus was suspected and the patient was commenced on topical corticosteroid (mometasone furoate) and oral prednisone at a dose of 30 mg/day. The symptoms of dysphagia and odynophagia alleviated remarkably within 3 weeks and the oral lesions disappeared 5 weeks later.

DISCUSSION

Oral lichen planus affects mostly women and has specific clinical forms, with the most common forms being the reticular and erosive forms (7). Oesophageal involvement appears to be very rare (especially in male patients) and the diagnosis of oesophageal lichen planus is rather difficult. Due to the absence of gastrointestinal symptoms in the present case, upper endoscopy was not performed before radiotherapy, and the possibility of pre-existent oesophagitis thus not excluded. Nevertheless, the oral and oesophageal symptoms were only gradually noticed after radiotherapy. A diagnosis of lichenoid oesophagitis was finally considered, based on the following evidence: first, the patient had, histologically confirmed oral lichen planus. Second, he presented with symptoms of dysphagia, odynophagia and sudden weight loss, and barium swallow as well as endoscopic examination revealed a stricture in the upper oesophagus, which corresponded to the previously described cases of lichenoid oesophagitis (8, 9), even if histological findings were non-specific and resembled those of chronic mucosal inflammation.

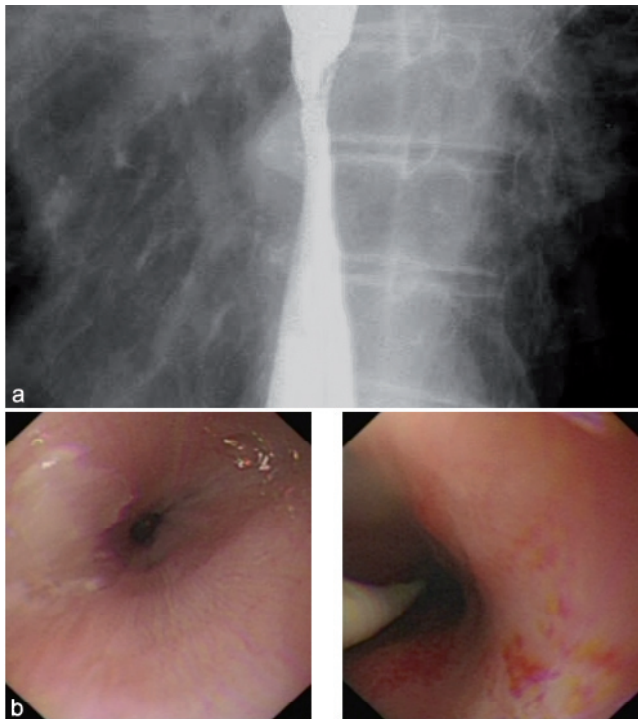


Fig. 2. (a) Barium swallow examination shows a stricture at proximal oesophagus. (b) Endoscopic views of peeling oesophageal mucosa of oesophageal lichen planus and stricture formation.

Third, poor response to proton pump inhibitors and good response to the treatment with systemic corticosteroid supported the autoimmunity aspects of the disorder.

Cases of generalized or localized lichen planus caused or re-elicited by radiotherapy have been reported sporadically (4, 5, 10–12). To date, little is known about the mechanism of radiotherapy-related lichen planus. However, the isomorphic response of skin to trauma has been suggested to play a role (11–13). There are a number of possible explanations for the concomitance of oral and oesophageal lichen planus after radiotherapy in the patient described here. The first, and most likely, is that there was an autoimmune process in which cytotoxic CD8+ and CD4+ T lymphocytes were activated by the malignant tumour and subsequent radiotherapy, inducing cellular apoptosis, degeneration of the basal layer and destruction of the epithelial basal membrane. The increased numbers of CD8+ and CD4+ T lymphocytes in the patient's peripheral blood support this hypothesis. The second possibility is that the oral lichen planus occurred as a Koebner's phenomenon, as described in a number of cases reported in patients with breast cancer, thyroid gland carcinoma or penile carcinoma (10–12). Notably, all of the reported cases received surgical resection before radiotherapy. However, in this case, due to the early diagnosis and the sensitivity of nasopharyngeal carcinoma to radiation, the patient was treated with radiotherapy alone.

Mucositis is one of the most common complications of radiotherapy. However, in the present case, the

oesophagus was beyond the region that was directly treated with radiation therapy. We speculate that the oesophagus was involved, both as a neighbouring site of direct mucous injuries and due to mucous damage resulting from an autoimmune response.

Finally, possible paraneoplastic changes in the oral and oesophageal mucosae should be considered in this case. Caused by the interplay of humoral and cell-mediated responses, such events have been implicated in the pathogenesis of lichen planus. Moreover, mucocutaneous lichen planus-like lesions are characteristically found in paraneoplastic pemphigus and thymoma (14).

In summary, we have presented a novel case of oral and oesophageal lichen planus following radiotherapy for nasopharyngeal carcinoma. We propose that the lesions developed as a result of radiological trauma and the activation of CD8+ and CD4+ lymphocytes during carcinogenesis.

The authors declare no conflicts of interest.

REFERENCES

1. McCartan BE, Healy CM. The reported prevalence of oral lichen planus: a review and Critique. *J Oral Pathol Med* 2008; 37: 447–453.
2. Eisen D. The evaluation of cutaneous, genital, scalp, nail, esophageal and ocular involvement in patients with oral lichen planus. *Oral Surg Med Oral Pathol Oral Radiol Endod* 1999; 88: 431–436.
3. Lehman JS, Tollefson MM, Gibson LE. Lichen planus. *Int J Dermatol* 2009; 48: 682–694.
4. Eichbaum M, Harms W, Bolz S, Schneeweiss A, Sohn C. Generalized lichen ruber planus – induced by radiotherapy of the breast? *Onkologie* 2006; 29: 521–523.
5. Morar N, Francis ND. Generalized lichen planus induced by radiotherapy: shared molecular mechanisms? *Clin Exp Dermatol* 2009; 34: e434–e435.
6. Van der Meij EH, van der Waal I. Lack of clinicopathologic correlation in the diagnosis of oral lichen planus based on the presently available diagnostic criteria and suggestions for modifications. *J Oral Pathol Med* 2003; 32: 507–512.
7. Eisen D, Carrozzo M, Sebastian J-VB, Thongprasom K. Number V Oral lichen planus: clinical features and management. *Oral Dis* 2005; 11: 338–345.
8. Evans AV, Fletcher CL, Owen WJ, Hay RJ. Oesophageal lichen planus. *Clin Exp Dermatol* 2000; 25: 36–37.
9. Bobadilla J, van der Hulst RW, ten Kate FJ, Tytgat GN. Esophageal lichen planus. *Gastrointest Endosc* 1999; 50: 268–271.
10. Kim JH, Krivda SJ. Lichen planus confined to a radiation therapy site. *J Am Acad Dermatol* 2002; 46: 604–605.
11. Shurman D, Reich HL, James WD. Lichen planus confined to a radiation field: The “isoradiotopic” response. *J Am Acad Dermatol* 2004; 50: 482–483.
12. Pretel M, España A. Lichen planus induced by radiotherapy. *Clin Exp Dermatol* 2007; 32: 582–583.
13. Sciallis GF, Loprinzi CL, Davis MD. Lichen planus induced by radiotherapy. *Br J Dermatol* 2005; 152: 399–401.
14. Khan S, Campbell A, Hunt C, Sewell WA. Lichen planus in a case of Good's syndrome (thymoma and immunodeficiency). *Interact Cardiovasc Thorac Surg* 2009; 9: 345–346.