

Paclitaxel-induced Neutrophilic Adverse Reaction and Acral Erythema

Antonio Cruz¹, Tecla Temu², Gladys Hines-Telang¹ and George Kroumpouzos^{1*}

¹Department of Dermatology, Rhode Island Hospital, APC 10, Brown Medical School, 593 Eddy Street, Providence, RI 02903, and ²Warren Alpert Medical School of Brown University, Providence, Rhode Island, USA. *E-mail: gk@gkderm.com
Accepted May 25, 2010.

Paclitaxel, a microtubule-stabilizing anti-neoplastic agent that belongs to the family of taxanes, is used in the treatment of advanced and/or refractory lung, breast, head, neck and other epithelial cancers. Site-specific reactions, such as inflammation at injection sites or cellulitis after extravasation (1), have been reported. Adverse cutaneous reactions associated with paclitaxel treatment include bullous fixed drug eruption (2), erythema multiforme (3), pustular eruption (4), scleroderma-like cutaneous lesions (5), onycholysis (6), and acral erythema (one case) (7). Of note, acral erythema (erythrodysesthesia) has been reported with multi-drug chemotherapy protocols that included paclitaxel (8, 9). We report here the first case of paclitaxel-induced neutrophilic adverse reaction with concomitant acral erythema, and highlight the mechanisms that may be involved.

CASE REPORT

A 77-year-old Caucasian woman undergoing chemotherapy for breast cancer presented with mildly sensitive skin lesions on the dorsal hands and painful lesions on the lower extremities. She had been treated with weekly intravenous paclitaxel for 3 months, and the skin lesions were noticed after the second cycle of the drug, flared after each subsequent dose of the medication. There was no history of fever or other systemic symptoms, and no prior trauma to the extremities. The treatment protocol involved premedication with diphenhydramine and ranitidine 3 h prior to receiving paclitaxel. Other medications during this period were alendronate sodium, levothyroxine, vitamin D and aspirin. The patient had been taking these medications for several years prior to paclitaxel exposure and continued taking them after the skin lesions resolved. Physical examination revealed erythematous, mildly edematous, tender papules and plaques on the dorsal hands (Fig. 1a), palms, dorsal feet and soles, as well as multiple, tender, erythematous, dusky red or violaceous papules and plaques symmetrically on the lower extremities (Fig. 1b).

Biopsy specimens from the left leg demonstrated hyperkeratosis, acanthosis, spongiosis, dyskeratosis with occasional satellite cell necrosis, and a moderately dense predominantly neutrophilic infiltrate (Fig. 2). Stains for microorganisms (Gram and Giemsa) were negative. Complete blood cell count and differential, urinalysis, electrolytes, liver function tests, serum protein electrophoresis, hepatitis serologies and autoantibody profile (antinuclear, SSA, SSB and anti-neutrophilic cytoplasmic antibodies) were within normal limits. Treatment with clobetasol 0.05% cream was not helpful. The lesions on the legs resolved spontaneously over the course of several weeks after the last cycle of paclitaxel.

DISCUSSION

Paclitaxel is the only drug in this patient's regimen that has been reported to cause acral erythema (known also as erythrodysesthesia or toxic erythema of chemotherapy) (7). The lesions on the hands were noticed 2 weeks into her weekly treatment of paclitaxel, flared after each subsequent dose of the medication, and disappeared within 2 weeks after discontinuation of the drug; this clinical course is consistent with chemotherapy-induced acral erythema. To our knowledge, development of a neutrophilic adverse reaction has not been reported with paclitaxel treatment. The differential diagnosis for the lesions on the legs includes Sweet's syndrome (acute febrile neutrophilic dermatosis), Sweet's-like drug hypersensitivity, rheumatoid neutrophilic dermatosis, neutrophilic eccrine hidradenitis, panniculitis and vasculitis. There has been a report (10) of a "neutrophilic dermatosis of the dorsal hands", but the course and clinical features of the hand lesions in our patient were not the same.

The histological feature of a predominantly neutrophilic infiltrate in this case is suggestive of Sweet's syndrome or rheumatoid neutrophilic dermatosis. However, the

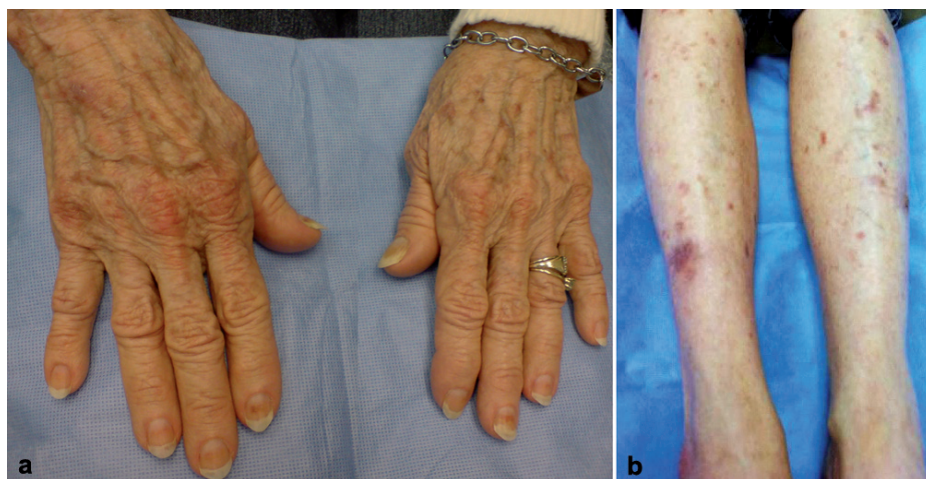


Fig. 1. (a) Erythematous macules and papules on the dorsa of the hands. (b) Tender erythematous or violaceous papules and plaques on the legs.

satellite cell necrosis (Fig. 2) in our case is indicative of a cytotoxic mechanism or graft-versus-host (GvH)-like reaction which can be seen in drug eruptions and not in Sweet's syndrome or rheumatoid neutrophilic dermatitis. The typical presentation of Sweet's syndrome is marked by leukocytosis, fever, and malaise in 78% of patients (11). In our patient, the morphology of lesions and absence of infection, fever and leukocytosis do not support the diagnosis of Sweet's syndrome, and she was not taking any of the medications that can cause a Sweet's-like drug hypersensitivity (11). She had no history of rheumatoid arthritis, and her lesions did not follow the clinical course of rheumatoid neutrophilic dermatitis (11, 12).

A drug-induced neutrophilic adverse reaction in our case is favored by the clinical course of the lesions, which were noticed after the second cycle of paclitaxel chemotherapy and resolved spontaneously after discontinuation of the medication. This case is also unique, in that it demonstrates cytotoxic effects (dyskeratosis, satellite cell necrosis) and a conspicuous neutrophilic infiltrate, both induced by paclitaxel. Chemotherapy-induced acral erythema is believed to be the result of a direct cytotoxic effect of anti-metabolites or alkylating agents (cytarabine, methotrexate, 5-fluorouracil, mercaptopurine) or, alternatively, a GvH-like or host-versus-altered host-type reaction (13). Paclitaxel, which is neither an anti-metabolite nor an alkylating agent, has been reported to cause acral erythema, presumably through a unique GvH-like reaction independent of nucleotide metabolism (7). Perhaps an altered clone of lymphocytes generated by this drug activity may result in a host-versus-altered host reaction (13). Certain histopathologic features in our case (apoptotic keratinocytes, exocytosis of mononuclear cells and focal areas of hydropic degeneration of the basal cell layer) are reminiscent of a GvH-like reaction. The mechanisms that cause the neutrophilic dermatitis in our case may be related to immune complex formation with subsequent cell adhesion and release of chemotactic cytokines, as seen in other neutrophilic reactions (14). As illustrated in this case, paclitaxel may cause a neutrophilic reaction and acral erythema, possibly through different mechanisms.

REFERENCES

- Stanford BL, Hardwicke F. A review of clinical experience with paclitaxel extravasations. *Support Care Cancer* 2003; 11: 270–277.
- Young PC, Montemarano AD, Lee N, Sau P, Weiss RB, James WD. Hypersensitivity to paclitaxel manifested as a bullous fixed drug eruption. *J Am Acad Dermatol* 1996; 34: 313–314.
- Payne JY, Holmes F, Cohen PR, Gagel R, Buzdar A, Dhingra K. Paclitaxel: severe mucocutaneous toxicity in a patient with hyperbilirubinemia. *South Med J* 1996; 89: 542–545.
- Weinberg JM, Egan CL, Tangoren IA, Li LJ, Laughinghouse KA, Guzzo CA. Generalized pustular dermatosis following paclitaxel therapy. *Int J Dermatol* 1997; 36: 559–560.
- Kupfer I, Balguerie X, Courville P, Chinet P, Joly P. Scleroderma-like cutaneous lesions induced by paclitaxel: a case study. *J Am Acad Dermatol* 2003; 48: 279–281.
- Link CJ Jr, Sarosy GA, Kohn EC, Christian MC, Davis P, Adamo DO, et al. Cutaneous manifestations of Taxol therapy. *Invest New Drugs* 1995; 13: 261–263.
- De Argila D, Dominguez JD, Iglesias L. Taxol-induced acral erythema. *Dermatology* 1996; 192: 377–378.
- Bafaloukos D, Papadimitriou C, Linardou H, Aravantinos G, Papakostas P, Skarlos D, et al. Combination of pegylated liposomal doxorubicin (PLD) and paclitaxel in patients with advanced soft tissue sarcoma: a phase II study of the Hellenic Cooperative Oncology Group. *Br J Cancer* 2004; 91: 1639–1644.
- Bafaloukos D, Linardou H, Aravantinos G, Papadimitriou C, Bamias A, Fountzilas G, et al. A randomized phase II study of carboplatin plus pegylated liposomal doxorubicin versus carboplatin plus paclitaxel in platinum sensitive ovarian cancer patients: a Hellenic Cooperative Oncology Group study. *BMC Med* 2010; 8: 3.
- Rockers KM, Fielder LM. Neutrophilic dermatosis of the dorsal hands. *Cutis* 2009; 83: 37–39.
- Callen JP. Neutrophilic dermatoses. *Dermatol Clin* 2002; 20: 409–419.
- Defaria D, Kroumpouzou G. Rheumatoid neutrophilic dermatitis as the only presenting sign of seronegative arthritis. *Acta Derm Venereol* 2004; 84: 236–237.
- Beard JS, Smith KJ, Skelton HG. Combination chemotherapy with 5-fluorouracil, folic acid, and α -interferon producing histologic features of graft-versus-host disease. *J Am Acad Dermatol* 1993; 29: 325–330.
- Yamamoto T, Ohukubo H, Nishioka K. Rheumatoid neutrophilic dermatitis. *Int J Dermatol* 1994; 11: 798–800.

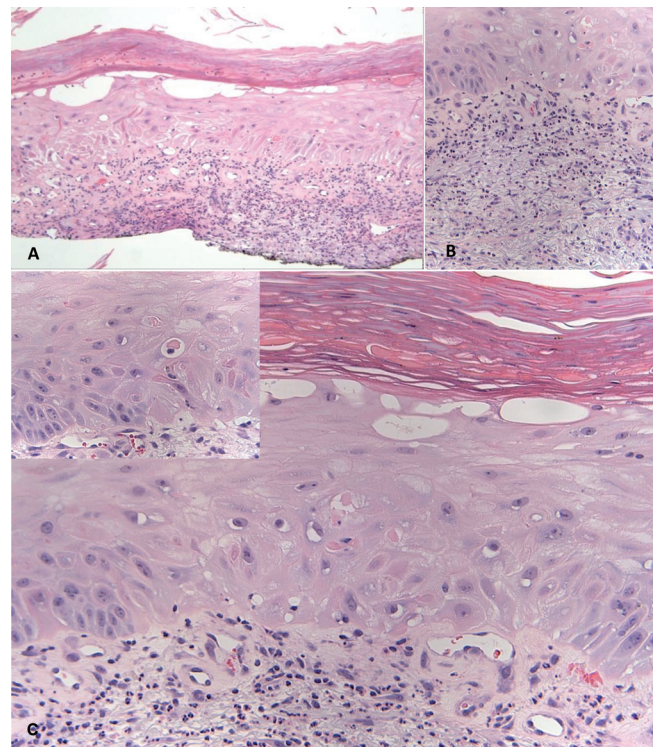


Fig. 2. (A) Biopsy from left leg shows hyperkeratosis, acanthosis and focal areas of hydropic degeneration of the basal cell layer. (B) Moderately dense, predominantly neutrophilic dermal infiltrate with nuclear dust. (C) High-power magnification demonstrates keratinocytes with pink glassy cytoplasm, dysmaturation, dyskeratosis, mild spongiosis, and mononuclear cell exocytosis. Insert: occasional satellite cell necrosis (haematoxylin-eosin stain: (A) $\times 4$; (B) $\times 10$, (C) $\times 20$).