

QUIZ SECTION

A Reddish Papular Lesion on the Scrotum: A Quiz

Roberto Betti¹, Silvano Menni¹, Amilcare Cerri¹ and Carlo Crosti²

¹Dermatological Department, University of Milan, AO San Paolo, Via A Di Rudini 8, I-20142 Milan, and ²Dermatology Unit – Department of Anaesthesia, Intensive Care and Dermatological Sciences, Università degli Studi di Milano – Fondazione IRCCS Ca' Granda, Ospedale Maggiore Policlinico, Milan, Italy. E-mail: berbet@alice.it

A 59-year-old healthy man presented with a 14-month history of an asymptomatic, slow-growing red papulo-nodular lesion on the left side of his scrotum. Physical examination revealed a 0.9 cm erythematous, dome-shaped nodule with a “stuck-on” appearance (Fig. 1a). Dermoscopic examination revealed multiple, dotted, pinpoint-size and globular regular vessels following regular pearl-like and serpiginous lines, especially on the upper half of the lesion (Fig. 1b). Surgical excision of the lesion confirmed the diagnosis suspected at dermoscopy.

Histological examination (Fig. 1c) demonstrated a sharply demarcated area of acanthotic epidermis, with psoriasiform appearance. The nuclei appeared normal. Slight spongiosis was observed and neutrophils were present throughout the epidermis. Periodic acid-Schiff reaction revealed the presence of large amounts of glycogen within the cells.

What is your diagnosis? See next page for answer.

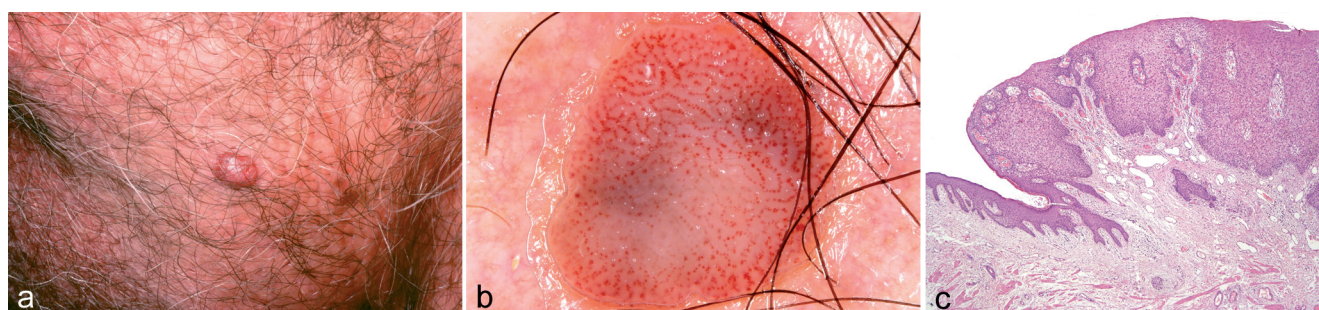


Fig. 1. (a) A reddish nodule on the scrotal surface. (b) Dermoscopic features. Multiple dotted, pinpoint-size and globular regular vessels distributed all over the lesion. The capillaries are distributed following regular pearl-like and serpiginous lines. (c) Histology shows a sharply demarcated area of acanthotic epidermis with a psoriasiform appearance.

doi: 10.2340/00015555-0921

ANSWERS TO QUIZ

A Reddish Papular Lesion on the Scrotum: Comment

Acta Derm Venereol 2010; 90: XX–XX (contd).

Diagnosis: Clear cell acanthoma

Clear cell acanthoma (CCA) is a first-stage, epidermal tumour, first described by Degos et al. in 1962 (1). It occurs more frequently as a solitary asymptomatic nodule or plaque, usually located on the legs and trunk of elderly people (2). CCA typically presents itself as a slowly growing, pink-brown, dome-shaped lesion. The appearance is usually “stuck-on” or bluish (3), while the size ranges from several millimetres to occasionally some centimetres in diameter (2). A thin collarette scaling often circumscribes the lesion. The tumour is composed of pale, glycogen-filled, normal- or large-size keratinocytes. The aetiology remains unknown; however, some authors have suggested that CCA is a reactive psoriasiform dermatosis (4).

The dermoscopic pattern of CCA was first described by Blum in 2001, as a psoriasis-like pattern consisting of partly homogeneous, symmetrical or bunch-like arranged, dotted vessels (3). According to Zalaudek et al. (4), the dotted vessels do not display a homogeneous distribution, as they usually do in psoriasis cases, but appear in a linear regular pearl-like distribution, following serpiginous lines or in a reticular pattern. Thus far, only a few reports have supplied a complete dermoscopic description of CCA (5–8). The dermoscopically described vessels represent the dilated capillaries oriented mainly perpendicularly to the skin surface in the elongated dermal papillae. This dermoscopic pattern may be a useful differential diagnostic tool for other

non-pigmented tumours, in particular amelanotic melanoma, Spitz naevus, and Bowen’s disease (9). The peculiarities of this case are the very unusual scrotal localization and the almost completely pearl-like and serpiginous distribution of capillaries detected on dermoscopy.

REFERENCES

1. Degos R, Delort J, Civatte J, Poiars BA. Tumeur epidermique d’aspect particulier: acanthoma a cellules claires. *Dermatologica* 1962; 129: 361–372.
2. Murphy R, Kessler ME, Slater DN. Giant clear cell acanthoma. *Br J Dermatol* 2000; 143: 114–115.
3. Fine RM, Chernosky ME. Clinical recognition of clear cell acanthoma (Degos). *Arch Dermatol* 1969; 100: 559–563.
4. Finch TM, Tan CY. Clear cell acanthoma developing on a psoriatic plaque. Further evidence of an inflammatory aetiology? *Br J Dermatol* 2000; 842–843.
5. Blum A, Metzler G, Bauer J, Rassner G, Garbe C. The dermoscopic pattern of clear cell acanthoma resembles psoriasis vulgaris. *Dermatology* 2001; 203: 50–52.
6. Zalaudek I, Hofmann-Wellenhof R, Argenziano G. Dermoscopy of clear-cell acanthoma differs from dermoscopy of psoriasis. *Dermatology* 2003; 207: 428.
7. Akin FY, Ertam I, Ceylan C, Kazandi A, Ozdemir F. Clear cell acanthoma: new observations on dermatoscopy. *Indian J Dermatol Venereol Leprol* 2009; 74: 285–287.
8. Bugatti L, Filosa G, Broganelli P, Tomasini C. Psoriasis-like dermoscopic pattern of clear cell acanthoma. *J Eur Acad Dermatol Venereol* 2003; 17: 452–455.
9. Zalaudek I, Argenziano G, Di Stefani A, Ferrara G, Marghoob AA, Hofmann-Wellenhof R, et al. Dermoscopy in general dermatology. *Dermatology* 2006; 212: 7–18.