

QUIZ SECTION

Thickening of the Skin on the Forehead: A Quiz

Román Barabash-Neila¹, Lourdes Rodríguez-Fernández Freire¹, Teresa Zulueta-Dorado² and Julián Conejo-Mir²

Departments of ¹Dermatology and ²Pathology, Virgen del Rocío University Hospital, Santa Fe, 9, 1ºD, ES-41011 Seville, Spain. E-mail: romanbarabash@hotmail.com

A 41-year-old man presented with a 3-year history of hyperpigmentation and thickening of the skin on the forehead. His family history was negative, and no history of drug or alcohol intake was observed. There were no pathological findings, except obesity, upon physical examination. His body mass index was 37.2 kg/m². Dermatological examination revealed a marked brownish-grey hyperpigmented velvety plaque with papillomatous elevations on his forehead (Fig. 1a).

Laboratory analyses reflected normal values for full blood count, serum chemistry, plasma glucose, plasma protein electrophoresis, thyroid function, plasma cortisol, tumour markers and HbA1c. The lipid profile revealed a high level of low-density lipoprotein cholesterol. Microscopic examination of biopsy specimen was performed (Fig. 1b).

What is your diagnosis? See next page for answer.

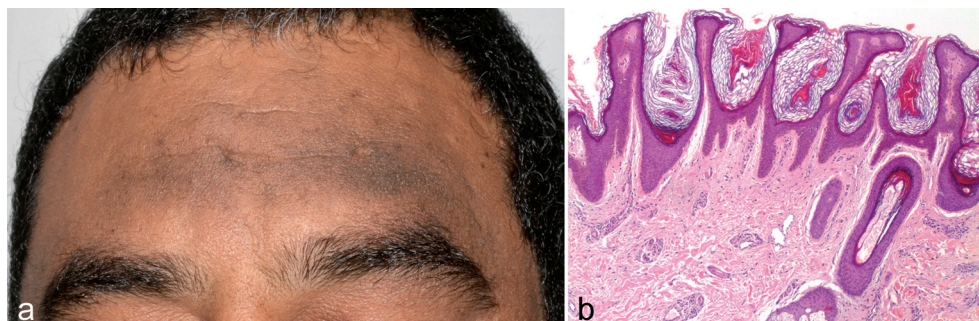


Fig. 1. (A) A brownish-grey hyperpigmented velvety plaque with papillomatous elevations located on forehead. (B) Biopsy specimen revealed epidermal orthokeratotic hyperkeratosis, papillomatosis and acanthosis.

doi: 10.2340/00015555-0906

ANSWERS TO QUIZ

Thickening of the Skin on the Forehead: A Comment

Acta Derm Venereol 2011; 91: 108–111 (contd).

Diagnosis: Acanthosis nigricans with forehead location

Acanthosis nigricans (AN) is a cutaneous disease characterized by velvety, hyperpigmented, papillomatous and hyperkeratotic patches and plaques. AN has a predilection for intertriginous areas, such as the neck, submammary region, axillae and groin. AN affecting the face, and especially the forehead, is very unusual.

No pathological finding was detected in our patient on chest X-ray or abdominal echography and a laboratory screening was normal except for hyperlipidaemia. Only 2 cases of adult patients with obesity and hyperinsulinaemia with AN localized on the forehead and on the cheeks have been reported (1, 2). An obese paediatric patient with AN localized on the *sulcus mentolabialis* and *nasolabial sulcus* has also been reported (3). Furthermore, there is another adult case with obesity but without hyperinsulinaemia, who developed AN on the *sulcus mentolabialis* (4). The rest of the published cases of facial AN have been in connection with malignancy, when it is habitually seen as part of widespread paraneoplastic disease (5).

AN is thought to be caused by factors that stimulate epidermal keratinocyte and dermal fibroblast proliferation. In the benign form of AN, the factor is probably insulin or an insulin-like growth factor (IGF) that stimulates epidermal cell propagation. When a high concentration level is reached, insulin may exert strong proliferative effects via high-affinity binding to IGF-1 receptors. In addition, free IGF-1 levels may be elevated in obese patients with hy-

perinsulinaemia (6). Perspiration or friction may also play a contributory role, as suggested by the predilection of this disease for body folds. In malignant AN, the stimulating factor is hypothesized to be a substance secreted either by the tumour or in response to the tumour. Transforming growth factor (TGF)-alpha is structurally similar to epidermal growth factor and is a likely candidate (7).

Because insulin resistance and malignancy were not detected as aetiology factors in our patient, we suggest that other mechanisms apart from those mentioned above could play a role in the formation of AN in obese patients.

REFERENCES

1. Hisler BM, Savoy LB. Acanthosis nigricans of the forehead and fingers associated with hyperinsulinemia. Arch Dermatol 1987; 123: 1441–1442.
2. Veysey E, Ratnavel R. Facial acanthosis nigricans associated with obesity. Clin Exp Dermatol 2005; 30: 437–439.
3. Akyol M, Polat M, Özçelik S, Elagöz S, Marufihah M. Acanthosis nigricans with atypical localization. Acta Derm Venereol 2000; 80: 399.
4. Gönül M, Cakmak SK, Kiliç A, Demirel O, Gül U. Acanthosis nigricans with an unusual localization. Australas J Dermatol 2006; 47: 212–213.
5. Schwartz RA. Acanthosis nigricans. J Am Acad Dermatol 1994; 31: 1–19.
6. Higgins SP, Freemark M, Prose NS. Acanthosis nigricans: a practical approach to evaluation and management. Dermatol Online J 2008; 14: 2.
7. Krawczyk M, Mykala-Ciesla J, Kolodziej-Jaskula A. Acanthosis nigricans as a paraneoplastic syndrome. Case reports and review of literature. Pol Arch Med Wewn 2009; 119: 180–183.