

Lipoblastoma-like Tumour of the Lip in an Adult Woman

Taek Jo Jeong, Yu Jin Oh, Jae Jun Ahn, Min Kyung Shin and Nack In Kim*

Department of Dermatology, School of Medicine, Kyung Hee University, 1 Hoegi-dong, Dongdaemun-gu, Seoul 130-702, Korea. *E-mail: nikim@khmc.or.kr
Accepted March 30, 2010.

Lipoblastomas are rare benign tumours of the white fatty tissue that occur almost exclusively in infants and young children (1). Commonly affected areas are the extremities and trunk, but other sites, including the head, neck, axilla, groin, labia, peritoneum, and retroperitoneum, can be involved (2–4).

Only a few cases of lipoblastoma and lipoblastomatosis have been reported in older children and young adults (3–7). We report here a case of adult onset of a benign adipocytic tumour, akin to a lipoblastoma, developing on the lip.

CASE REPORT

A 61-year-old woman presented to our hospital with a 1-year history of a slowly growing mass on the lower lip, without associated symptoms. Physical examination revealed a 2 × 1 cm soft, erythematous dermal nodule with slight elevation (Fig. 1a). The patient was otherwise healthy and had no history of injection of a foreign body, such as a filler. The differential diagnosis included: Fordyce's spot, nevus lipomatosus superficialis and foreign body granuloma; therefore, an excisional biopsy was performed. The excised specimen showed numerous dermal lobules composed predominantly of multivacuolated cells resembling lipoblasts and mature fat cells. The lipoblasts varied in size, and some of them had several vacuoles that displaced or indented the nuclei. The lobules were separated by fibrous septa containing capillaries. No necrosis or mitotic activity was identified (Figs 1b and c). The cells stained positively for vimentin (Fig. 1d) and negatively for cytokeratins, CD34, CD68 and desmin. The histopathological findings were consistent with a lipoblastoma. Neither local recurrence nor metastasis was observed one year after surgery.

DISCUSSION

Because lipoblastomas are usually well encapsulated and have little adjacent tissue, the definitive treatment is complete surgical excision. However, focal recurrence can be a problem in up to 25% of cases, due to incomplete resection (1, 3, 8). Despite their ability for local invasion and rapid growth, the prognosis is excellent (1, 2).

The histopathological findings of a lipoblastoma are characterized by lobular architecture and an admixture of mature adipocytes and lipoblasts in various stages of development (5, 9). The matrix can be myxoid. The histopathological differential diagnosis of a liposarcoma includes other tumours with adipocytic differentiation, such as atypical lipomatous tumours/well-differentiated liposarcomas, myxoid liposarcomas, and spindle cell lipomas. Because of the presence of lipoblasts, a lipoblastoma may have a strong resemblance to well-differentiated liposar-

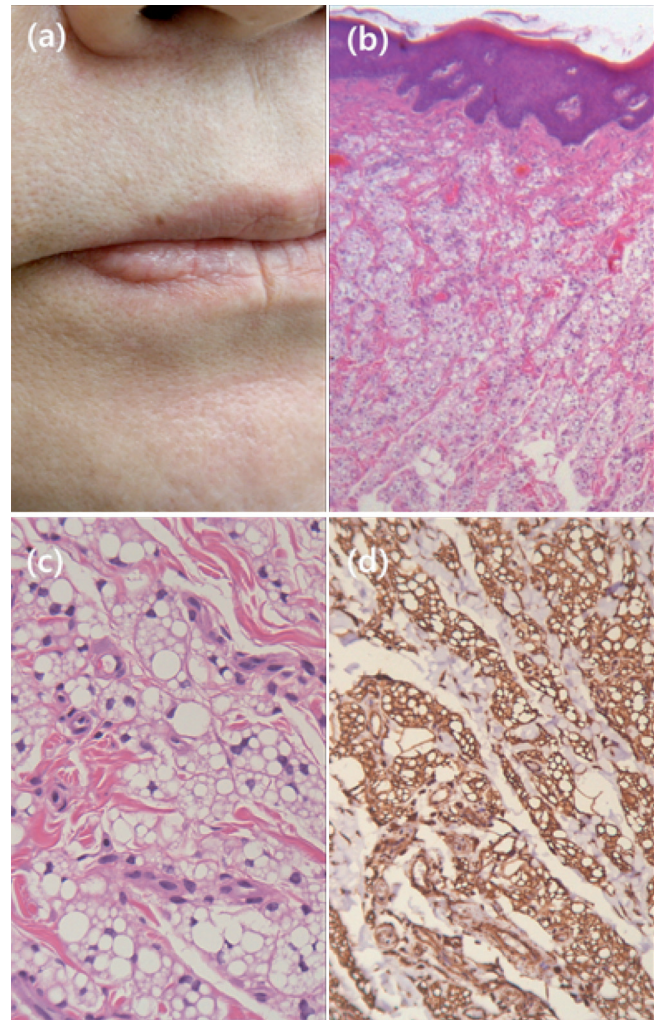


Fig. 1. (a) A 2 × 1 cm soft tumour of the lower lip. (b) Histopathology of the excised mass showing numerous dermal lobules separated by fibrous septa containing capillaries (haematoxylin and eosin (H&E), × 100). (c) Admixture of peripheral immature lipoblasts and central mature adipocytes (H&E, × 400). (d) Immunohistochemical staining reaction for vimentin is strongly positive (immunoperoxidase, × 200).

comas. Cases with myxoid changes may be extremely difficult to distinguish from myxoid liposarcomas. The recent innovation of the term lipofibromatosis also adds to the diagnostic difficulty. The degree of the fibroblastic component is generally greater in lipofibromatosis than in lipoblastoma (10). In immunohistochemical studies, the neoplastic cells are positive for vimentin and stain negatively for other markers, including cytokeratins, CD34, desmin and NKIC3 (10). These markers can be helpful in distinguishing lipoblastoma from the appendageal tumours and other mesenchymal tumours, such as spindle

cell lipoma, angiomyofibroblastoma and lipofibromatosis (4, 10, 11). The immunohistochemical findings in the current study were consistent with a lipoblastoma.

Cytogenetic analysis of adipose tissue tumours including lipoblastoma has shown distinct chromosomal aberrations (5, 7, 12). Accordingly, it may be used for diagnostic confirmation. Most lipoblastomas present with rearrangements of the 8q12/PLAG1 region (5, 7). Some subsets of lipoblastomas show polysomy for chromosome 8 (5, 13). Although chromosomal studies might help in the differential diagnosis of adipocytic tumours, in this case the patient refused further evaluation.

The neoplasm in the case reported here shared some histological features of a lipoblastoma: prominent lobulation, the admixture of peripheral immature lipoblasts with fat vacuoles of various sizes, central mature fat cells, and fibrous septae containing a rich capillary network. However, the clinical manifestations in this case did not suggest the diagnosis of lipoblastoma. To our knowledge, lesions occurring on the lip have not been reported. However, lipoblastomas of mucosal sites, such as the perianal area and vulva, have rarely been reported (1, 3, 4). In addition, lipoblastomas are neoplasms of infants and young children under 5 years of age. Very rare cases have been reported in patients ≥ 18 years of age (3–5, 7, 12).

The name “lipoblastoma-like tumour of the vulva” was first suggested by Lae et al. (4), who reported three cases with an adipose tissue tumour of the vulva affecting women of 13, 23 and 38 years of age. These tumours histopathologically resembled an infantile lipoblastoma. The tumour in our report is similar to this unique clinical entity referred to as a “lipoblastoma-like tumour” (4).

REFERENCES

1. Chung EB, Enzinger FM. Benign lipoblastomatosis. An analysis of 35 cases. *Cancer* 1973; 32: 482–492.

2. Hicks J, Dilley A, Patel D, Barrish J, Zhu SH, Brandt M. Lipoblastoma and lipoblastomatosis in infancy and childhood: histopathologic, ultrastructural, and cytogenetic features. *Ultrastruct Pathol* 2001; 25: 321–333.
3. Collins MH, Chatten J. Lipoblastoma/lipoblastomatosis: a clinicopathologic study of 25 tumors. *Am J Surg Pathol* 1997; 21: 1131–1137.
4. Lae ME, Pereira PF, Keeney GL, Nascimento AG. Lipoblastoma-like tumour of the vulva: report of three cases of a distinctive mesenchymal neoplasm of adipocytic differentiation. *Histopathology* 2002; 40: 505–509.
5. de Saint Aubain Somerhausen N, Coindre JM, Debiec-Rychter M, Delplace J, Sciort R. Lipoblastoma in adolescents and young adults: report of six cases with FISH analysis. *Histopathology* 2008; 52: 294–298.
6. Miller GG, Yanchar NL, Magee JF, Blair GK. Lipoblastoma and liposarcoma in children: an analysis of 9 cases and a review of the literature. *Can J Surg* 1998; 41: 455–458.
7. Sciort R, De Wever I, Debiec-Rychter M. Lipoblastoma in a 23-year-old male: distinction from atypical lipomatous tumor using cytogenetic and fluorescence in-situ hybridization analysis. *Virchows Arch* 2003; 442: 468–471.
8. Do NY, Cho SI, Park JH, Choi JY. Lipoblastoma arising from the submandibular region. *J Pediatr Surg* 2008; 43: e13–e15.
9. Fletcher CDM, Unni KK, Mertens F, World Health Organization, International Agency for Research on Cancer. *Pathology and genetics of tumours of soft tissue and bone*. Lyon: IARC Press, 2002.
10. Ende L, Upton J, Richkind KE, Vargas SO. Lipoblastoma: appreciation of an expanded spectrum of disease through cytogenetic analysis. *Arch Pathol Lab Med* 2008; 132: 1442–1444.
11. Suster S, Fisher C. Immunoreactivity for the human hematopoietic progenitor cell antigen (CD34) in lipomatous tumors. *Am J Surg Pathol* 1997; 21: 195–200.
12. Silverman JS, Hamilton J, Tamsen A. Benign recurring lipoblastoma in an adult versus well differentiated subcutaneous myxoid liposarcoma: clinicopathologic, immunohistochemical and molecular analysis of a unique case. *Pathol Res Pract* 1999; 195: 787–792; discussion 93.
13. Fletcher JA, Kozakewich HP, Schoenberg ML, Morton CC. Cytogenetic findings in pediatric adipose tumors: consistent rearrangement of chromosome 8 in lipoblastoma. *Genes Chromosomes Cancer* 1993; 6: 24–29.