

Phototherapy as a Useful Therapeutic Option in the Treatment of Diphenylcyclopropenone-induced Vitiligo

Giulia Ganzetti, Oriana Simonetti, Anna Campanati, Katia Giuliodori and Annamaria Offidani

Dermatologic Clinic, Polytechnic University of Marche, Italy. E-mail: giulia.ganzetti@alice.it

Accepted March 16, 2010.

Alopecia areata (AA) is an inflammatory non-scarring hair loss that affects the anagen-stage hair follicles. It is determined by an autoimmune process and characterized histologically by peri- and intra-follicular infiltration of CD4+ and CD8+ T cells (1).

At present the most effective therapy for AA is diphenylcyclopropenone (DPCP), a contact sensitizer that has been used in the treatment of extensive AA since 1983. The immunological mechanism of action of DPCP is unknown (2).

Vitiligo is one of a number of adverse events resulting from the application of DPCP and, like *Vulgaris*-type vitiligo, it represents a great challenge for dermatologists, due to its significant resistance and recalcitrance to many conventional therapies. We report here a case of DPCP-induced vitiligo in a patient with AA, which was treated successfully with phototherapy.

CASE REPORT

A 34-year-old man, who had developed AA 6 months previously, was referred to our clinic. The disease involved part of the right parietal area, one patch on the edge of the scalp and the occipital area. Anamnesis was negative for remarkable disease, thyroid disease, autoimmune disorders and atopic dermatitis; no familiar or personal history of vitiligo was identified. The AA was resistant to topical and systemic corticosteroid therapy, thus DPCP therapy was commenced.

After 2 weeks of sensitization with DPCP 2% in acetone on a 2 × 2 cm area of the affected occipital patch,

increasing concentrations of DPCP (from 0.0001% to 0.5%) were applied progressively in all alopecic areas. DPCP 0.5% was determined as the therapeutic dosage to obtain pruritus and local erythema.

Initial hair regrowth commenced after approximately 10 weeks of topical treatment. After 24 weeks the patch on the vertex was completely covered by terminal hair, and there was an 85% regrowth on the occipital and parietal areas, and a significant improvement in the patient's psychological profile.

After 9 months of treatment, the patient developed significant acute contact eczema with blistering on the occipital area after the usual application of DPCP 0.5%, and thus application was discontinued and the dermatitis treated with oral steroids and antihistamines.

Vitiligo appeared after resolution of the contact dermatitis in all areas treated with DPCP, not only the occipital ones. Distant sites were not involved. At the same time the AA returned and increased progressively in the same areas (Fig. 1A).

DPCP was stopped, and after a failed attempt with topical and oral steroids to treat the rapid progression of the disease, the patient was switched to phototherapy with narrowband UVB, twice a week for 8 weeks, at an initial dosage of 0.3 J increasing in steps of 0.5 J up to a maximum dose of 1 J.

The patient showed a good clinical response to narrowband UVB (Fig. 1B), with total repigmentation on the vertex area, repigmentation of approximately 90% on the other involved sites, and a significant improvement in AA. Thus, a maintenance phase was

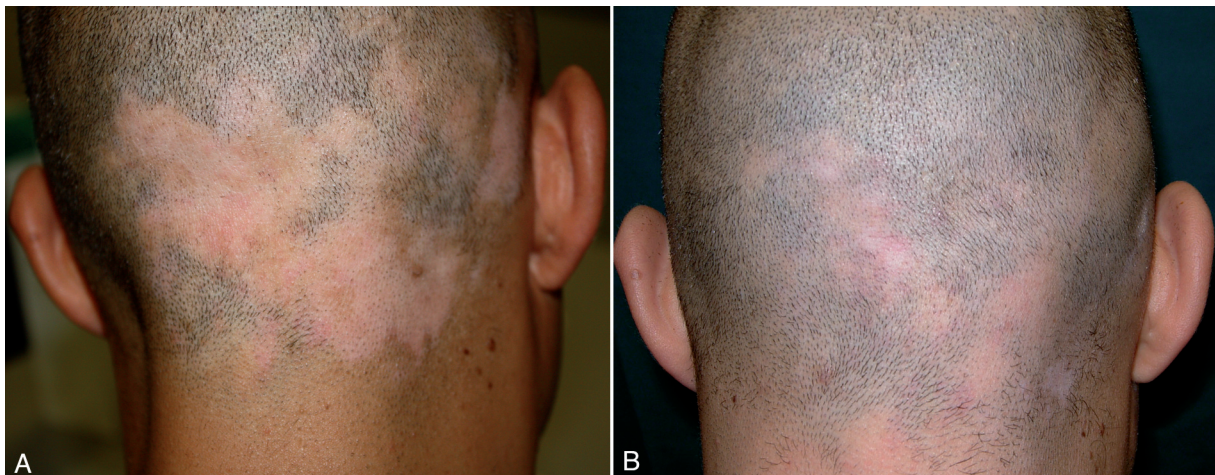


Fig. 1. (A) Vitiligo following diphenylcyclopropenone (DPCP) therapy for alopecia areata. (B) Clinical response of vitiligo after 8 weeks of narrowband UVB therapy.

instigated, with gradual tapering of the frequency of phototherapy.

DISCUSSION

Vitiligo and AA are skin disorders characterized by an autoimmune pathogenesis that has not yet been elucidated.

There is currently a wide range of therapeutic possibilities for the management of both diseases, although it is often difficult to obtain satisfactory and long-term clinical results. Topical immunotherapy, and in particular DPCP, has been used extensively as a therapeutic approach for many dermatological disorders with an immunological basis, such as AA, viral warts and vitiligo (3, 4).

DPCP-induced vitiligo is a rare, but documented, adverse event during DPCP treatment for AA (5). There are many hypotheses about this clinical manifestation: it may be a Koebner phenomenon in patients who are predisposed to vitiligo, or it may be linked to a direct cytotoxic effect of the contact sensitizer on melanocytes following systemic absorption, in particular when distant sites are involved (5, 6).

The patient described here did not have a familiar or personal history of vitiligo, thus the onset of depigmentation during treatment was not anticipated. Moreover, it occurred after an important contact reaction at a relatively high dosage of DPCP (0.5%) and not after lower dosages.

Although previous electron microscopic studies have confirmed that the depigmentation is not post-inflammatory, but sustained by an isomorphic phenomenon, our case does not support this data, because the vitiligo occurred after a significant acute contact dermatitis (7).

It can be hypothesized that this rare adverse effect of DCPC immunotherapy may be secondary to a "sum effect" linked to long-term therapy in genetically predisposed patients, but probably independent from the therapeutic dosage used, which varies from patient to patient.

When the therapeutic dosage has been determined it may be useful to apply the application every 2–3 weeks until satisfactory hair regrowth or Switch the immediately to a lower dosage in order to avoid the risk of inducing contact eczema.

Treatment of this leukoderma is based on discontinuation of DPCP treatment, followed by topical or systemic steroid treatment and phototherapy (psoralen plus ultraviolet A (PUVA) or narrowband UVB) (8). The clinical response to these proposed treatments is extremely variable; repigmentation may occur, but complete recovery is uncommon (5).

In the present case narrowband UVB phototherapy was the most effective treatment for the patient's vitiligo and AA, leading to a satisfactory improvement and long-term clinical response for both diseases.

REFERENCES

1. Herbst V, Zoller M, Kissling S, Wenzel E, Stutz N, Freyschmidt-Paul P. Diphenylcyclopropanone treatment of alopecia areata induces apoptosis of perifollicular lymphocytes. *Eur J Dermatol* 2006; 16: 537–542.
2. Sotiriadis D, Patsatsi A, Lazaridou E, Kastanis A, Vakirlis E, Chrysomallis F. Topical immunotherapy with diphenylcyclopropanone in the treatment of chronic extensive alopecia areata. *Clin Exp Dermatol* 2007; 32: 48–51.
3. Aghaei S, Ardekani GS. Topical immunotherapy with diphenylcyclopropanone in vitiligo: a preliminary experience. *Indian J Dermatol Venereol Leprol* 2008; 74: 628–631.
4. Aghaei S. Topical immunotherapy of severe alopecia areata with diphenylcyclopropanone (DPCP): experience in an Iranian population. *BMC Dermatol* 2005; 5: 6.
5. Pan JY, Theng C, Lee J, Goh BK. Vitiligo as an adverse reaction to topical diphenylcyclopropanone. *Ann Acad Med Singapore* 2009; 38: 276–277.
6. Hatzis J, Gourgiotou K, Tosca A, Varelzidis A, Stratigos J. Vitiligo as a reaction to topical treatment with diphenylcyclopropanone. *Dermatologica* 1988; 177: 146–148.
7. Duhra P, Foulds IS. Persistent vitiligo induced by diphenylcyclopropanone. *Br J Dermatol* 1990; 123: 415–416.
8. Henderson CA, Ilchyshyn A. Vitiligo complicating diphenylcyclopropanone sensitization therapy for alopecia universalis. *Br J Dermatol* 1995; 133: 496–497.