

INVESTIGATIVE REPORT

Differences in the Peritumoural Inflammatory Skin Infiltrate Between Squamous Cell Carcinomas in Organ Transplant Recipients and Immunocompetent Patients

Britta KRYNITZ¹, Barbro LUNDH ROZELL¹ and Bernt LINDELÖF²

¹Department of Pathology and Cytology, Karolinska University Laboratories, and ²Department of Dermatology, Karolinska University Hospital, Stockholm, Sweden

Organ transplant recipients (OTR) have a greatly increased risk (up to 100 times) of developing squamous cell carcinomas (SCC) in the skin. This is attributed specifically to chronic immunosuppression, causing dysfunctional viral defence and tumour protection. To investigate the possible link between increasing risk of SCCs and type of inflammation in these tumour-prone patients, we analysed the peritumoural infiltrates with regard to cell types and densities. Seven SCCs from immunosuppressed OTR and 14 SCCs from immunocompetent patients were immunohistochemically stained for CD3, CD4, CD8, CD56, CD20, CD138, CD14, CD68, CD1a. Cell counts were performed with the aid of computer-based image analysis of >100,000 cells. When comparing the percentage distributions, significant differences were detected (outlined as median values (min–max)): T cells (CD3+): OTR 57% (35–78), controls 68% (48–80), $p=0.036$; plasma cells (CD138+): OTR 2% (0.7–7), controls 0.2% (0–1.2), $p=0.001$; monocytes (CD14+): OTR 3.2% (1.1–5.6), controls 9.3% (2.2–17.2), $p=0.014$. Surprisingly, no differences in cell densities, i.e. cells/mm² tumour section area, were detected between the 2 groups. In conclusion, we found that the peritumoural infiltrates in immunosuppressed compared with immunocompetent patients differ in cellular composition, inferring a more tumour-submissive environment in OTR. However, cellular densities were equal, suggesting deviating cellular functionality in OTR. *Key words: non-melanoma skin cancer; cutaneous squamous cell carcinoma; organ transplant recipient; peritumoural inflammatory infiltrate; computer-based image analysis.*

(Accepted February 9, 2010.)

Acta Derm Venereol 2010; 90: 379–385.

Britta Krynitz, Department of Pathology and Cytology, Karolinska University Laboratories, F46 Huddinge, S-14186 Stockholm, Sweden. E-mail: britta.krynitz@karolinska.se

Cutaneous squamous cell carcinoma (SCC) is one of the most rapidly increasing cancers in the fair-skinned population worldwide. Overall, one-third of all cancers occur in the skin (1, 2). In Sweden the incidence of non-melanoma skin cancer for 2008 shows an average annual increase of 3.9% for men and 5.9% for women during the latest 10-year period. The skin, excluding melanoma and

basal cell carcinoma is the second most common cancer site in males and the third most common in females (2). In immunosuppressed, solid organ transplant recipients (OTR), the risk of developing a cutaneous SCC 5 years after transplantation is up to 100 times greater than in immunocompetent subjects in a Nordic population (3). These SCCs account for approximately 50% of all cancers in OTR patients (4). The OTR-associated SCCs, especially those on chronically sun-exposed sites, are often multiple, fast and deep growing, i.e. show a more aggressive behaviour, which is also revealed by an increased risk of local recurrence and metastasis (5–8). They are potentially life-threatening, which is emphasized by a 50-fold increased mortality rate compared with the general population in Sweden (6). The aetiology of post-transplant SCC is, apart from sun exposure, multifactorial, but emphasis is placed on the long-term immunosuppression to which these patients are subjected. Immune-modulating drugs, which are necessary to control transplant failure due to rejection, also negatively regulate the immune responses that are indispensable for viral defence and anti-tumour surveillance. The prolonged use of these drugs probably explains the increasing incidence of SCC in OTR over time (4, 9). A tumour-promoting potential of the drugs themselves, independent of their immunosuppressive effects, has been described for agents such as azathioprine, cyclosporine and even for corticosteroids (9–11). In addition, all immunosuppressive drugs currently used result in a more or less pronounced depression or altered function of different immune cells. Whether or not this is important for tumour development in OTR is uncertain, but T cell function appears to be critical to the immunological control of SCCs. The contribution of inflammation to tumour development and progression is gaining increasing acceptance (12). Sites of chronic irritation and inflammation are being considered as tumour-promoting environments. Similar to that of a non-healing wound, the inflammatory reaction is also long-lived around an invasive cancer. The persistent recruitment of different cell types into the tumour stroma generates oxidative stress, thereby promoting protein and DNA damage, but also contributing to tissue remodelling and angiogenesis (13, 14). In tumours the balance between desirable anti-tumour immune responses and undesirable pro-tumour inflammatory responses is generally polarized towards a so-called response type Th2 (15). This means

that the immune cell composition around tumours exhibits increased levels of mainly CD4 regulatory T cells, CD4 (Th2) T cells, macrophages (tumour-associated macrophages (TAMS), also referred to as type 2 macrophages), B cells and possibly also mast cells, and shows reduced levels of mainly CD8 T cells, CD4 (Th1) T cells and type 1 macrophages. In cutaneous SCC successful topical therapy with imiquimod is believed to be due to a shift in immunity from a tumour-promoting Th2 environment towards a tumour-rejecting Th1 response (16). However, Clark et al. (17) found very few Th2-biased T cells in untreated SCCs. Their results suggest instead faulty T-cell homing, due to down-regulation of vascular E-selectin, and the recruitment of regulatory T cells as the main reason for non-effective anti-tumour immune response of the host.

The mechanism by which inflammation promotes skin carcinogenesis is highly complicated and not fully understood. Even less is known about its role in cutaneous SCC development in immunosuppressed OTR, which we believe to be a suitable model system for the study of the effects of an inhibited and limited immune response on tumour development. These considerations have led us to systematically investigate the quantity and nature of the cells in the inflammatory microenvironment at the invasive margins of SCCs from immunocompetent patients as well as from immunosuppressed OTR, in order to study possible differences between these groups. This was done by processing archived SCC tissue blocks, formalin-fixed and paraffin-embedded (FFPE), by using a broad panel of well-established immunohistochemical markers and methods and with the aid of computer-based image analysis.

MATERIALS AND METHODS

Patients

Seven SCCs from OTR, all renal transplants, with a history of at least 5 cutaneous SCCs, had been collected for a previous study (6). All tumours date from the period 1993 to 1997 and were collected from 7 different pathology laboratories in Sweden. Information about the type of immunosuppressive drugs taken by the OTR was lacking, but since the analysed tumours were all excised during the period 1993 to 1997, we can confidently assume that azathioprine, cyclosporin A and corticosteroids were the main drugs used in all OTR patients.

Fourteen cutaneous SCCs from immunocompetent patients, with no other cancers up to 2006 according to a search in the Swedish Cancer Registry, were used as control tumours. All control tumours date from between 2003 and 2006 and were collected from one pathology laboratory in Sweden, Karolinska University Laboratory, Department of Pathology and Cytology, Huddinge. The distinction between *in situ* and invasive forms of SCC was made according to the recent World Health Organization (WHO) skin tumour classification (18). When choosing suitable tumour specimens two criteria were applied: firstly, complete excision with a margin of normal skin and, secondly, no signs of ulceration as evaluated in haematoxylin and eosin stained sections. The characteristics of OTR and controls, including details of tumour type and site are shown in Table I.

This study was approved by the regional board of the ethics committee at Karolinska Institute, Stockholm, Sweden.

Immunohistochemistry

Antibodies. All antibodies were monoclonal mouse antibodies; the antibody, its code, dilution used, manufacturer's name, city and country: CD1a, NCL-L-CD1a-235, 1:3; CD3, clone LN10, NCL-L-CD3-565, 1:100; CD4, NCL-L-CD4-368, 1:100; CD8, NCL-CD8-4B11, 1:50; CD14, NCL-CD14-223, 1:50; CD56 (NCAM), NCL-L-CD56-1B6, 1:50 (all from Novocastra, Newcastle Upon Tyne, UK); CD20,

Table I. Characteristics of patients and squamous cell carcinomas (SCC)

Patient no./sex	Age (years)	Time since transplantation (years)	Analysed SCC ^a	Tumour section area (mm ²)	Tumour site	Analysed SCCs rank number/patient's total number of SCCs
<i>Immunosuppressed organ transplant recipients</i>						
1/M	54	17	<i>In situ</i>	0.95	Elbow	9/9
2/M	53	15	<i>In situ</i>	6	Clavicle	15/18
3/M	60	14	High	13	Upper arm	2/6
4/M	51	20	High	17	Breast	13/14
5/M	48	5	High	2.3	Clavicle	4/7
6/F	49	14	Moderate	6.5	Head	4/22
7/F	50	19	Low	10.9	Breast	8/12
<i>Immunocompetent controls</i>						
1/M	76	–	<i>In situ</i>	4.8	Elbow	1
2/F	77	–	<i>In situ</i>	1.5	Sternum	1
3/F	51	–	<i>In situ</i>	0.85	Lower arm	1
4/M	56	–	<i>In situ</i>	7.6	Finger	1
5/M	72	–	High	39	Shoulder	1
6/M	65	–	High	65	Shoulder	1
7/F	86	–	High	17	Dorsum hand	1
8/F	76	–	High	12.6	Face	1
9/F	91	–	High	7.7	Face	1
10/M	75	–	High	57	Dorsum hand	1
11/M	57	–	High	15	Torso	1
12/M	51	–	Moderate	6.5	Upper leg	1
13/M	80	–	Moderate	42	Breast	1
14/M	72	–	Moderate	15	Face	1

^aInvasive SCC with grade of differentiation or *in situ* SCC.

anti-human CD20cy, clone L26, code M0755, 1:600; CD68, clone PG-M1, code M0876, 1:300 (all from Dako, Glostrup, Denmark); CD138, PN IM2757, clone B-B4, 1:200 (from Immunotech, Marseille, France)

Tissue sections. Paraffin-embedded complete excision SCC specimens were sectioned at 4 μm thickness, mounted on Superfrost plus glass slides and dried overnight at 37°C, deparaffinized and rehydrated. Endogenous peroxidase activity was blocked with Dako REAL Peroxidase-Blocking Solution (code S2023, Dako). Slides were pre-treated overnight in citrate buffer pH 7.2 at 60°C (CD1a, CD56), with cooking (microwave) in citrate buffer at pH 6.0 for 3 min, then for 15 min on "defrost" and subsequent cooling for 20 min (CD3, CD8, CD20, CD138), with overnight storage in EDTA-buffer pH 8.0 (E5134 Sigma-Aldrich, USA) and 1.0 M NaOH at 60°C (CD14). To visualize CD4 and CD68 retrieval solution pH 9.0 (Dako, Glostrup, Denmark) was used. For staining the "labelled streptavidin-biotin" method (LSAB) was used together with appropriate biotinylated secondary antibodies on an automatic immunostaining instrument, Dako REAL detection system, peroxidase/diaminobenzidine (DAB+) Tech Mate 500+ (Dako, Glostrup, Denmark). Finally, reactions were visualized by DAB+ chromogen (all steps with Dako REAL) and counterstained with Mayer haematoxylin. Tissue mast cells were stained with Astra Blue (Merck, Poole, UK) (19). Since all staining methods are well established in routine laboratory practice, a specific positive and negative control was not run for these panels.

Morphometric methods

Scanning. Scanning of slides, whole slide imaging, was performed with a Mirax scan (Carl Zeiss Inc., Munchen, Germany) (Operating manual: B 46-0064 e) standard configuration including a 20 \times /0.75 objective, resolution 0.23 μm per pixel with a

Sony DFW-X710 Fire Wire camera (Sony Inc., Tokyo, Japan). Most scanning was done in automatic mode with a pre-set scan setting of JPEG quality at 90% and automatic thresholding. When the manual mode was used the threshold was adjusted according to colour intensities.

Image viewing and analysis. Viewing and analysis of the digital slides was performed on a 30" Cinema Display monitor (Apple Inc., Cupertino, USA) with a resolution of 2560 \times 1600 pixels. The initial digital slide file could be viewed with the Mirax Viewer software (Carl Zeiss Inc., Munchen, Germany), conversion to JPEG was performed using Mirax slide export utility software (Carl Zeiss Inc., Munchen, Germany). This step was necessary to import the pictures to AxioVision digital image analysis software version 4.6.3 interactive measurement module (Carl Zeiss Inc., Munchen, Germany). The crucial features for this project included area measurements in square micrometers, circle measurements and marking of events. Specimens were examined at a magnification of up to \times 1000, compared with \times 400 magnification in a standard bright field microscope.

Inflammatory cell enumeration/statistical analysis

Data acquisition was performed as follows: (i) first, total tumour area was measured on the individual CD3 slide of each tumour, including mainly viable tumour epithelium, i.e. little hyperkeratosis; (ii) in order to achieve an adequate representation of the peritumoural field, an area equal to 10% of the total tumour area was selected; (iii) this counting area was further divided into 4 equally sized circles, which were placed symmetrically along the infiltrating border of the tumours, one on each lateral side and two along the deep, central margin, all circles touching the tumour epithelium. Creases, splits or uneven parts were avoided. The aim was to place the 4 circles in approximately the same positions throughout the individual cut

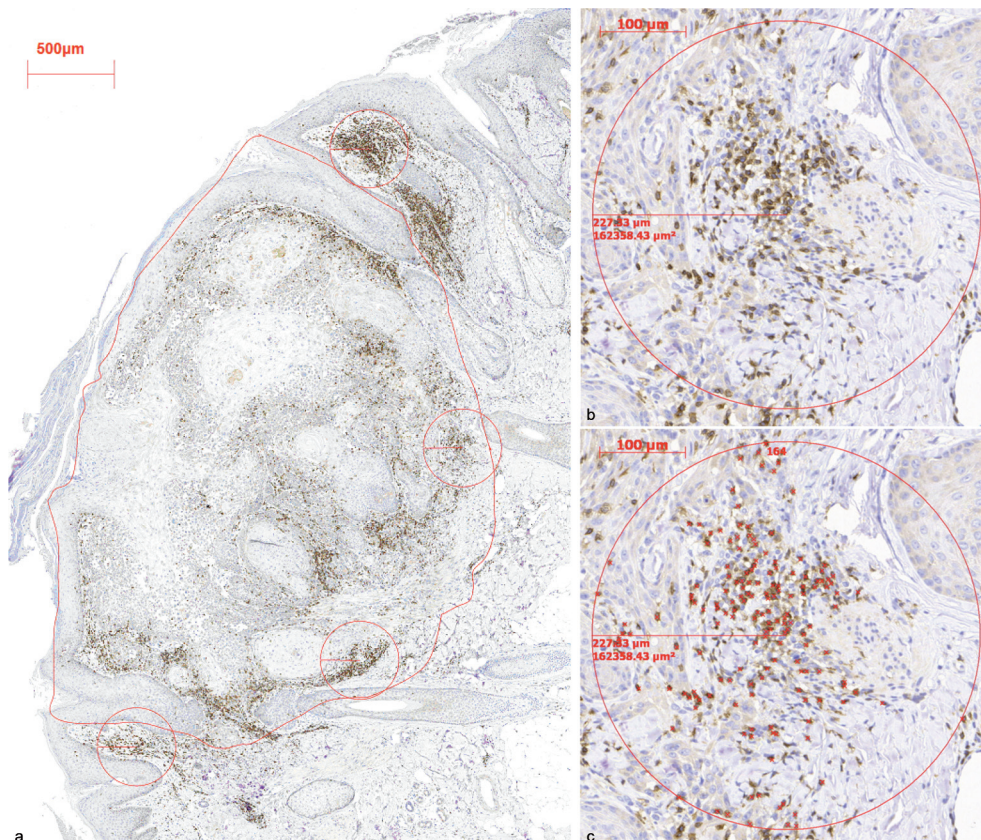


Fig. 1. (a) Photomicrograph of squamous cell carcinoma (SCC) with marked total tumour section area (red line) and circles marking the selected 10% area in which inflammatory cells were counted (organ transplant recipient (OTR)/case 6, CD3 stain, tumour section area 6.49 mm², small text). (b) Magnification of the second circle from the top with CD3-stained cells (stating circle diameter and area). (c) Same circle as (b) with marked positive cells.

sections (Fig. 1); (iv) in each circle positive cells were counted (for definitions of positive cells see below). The mean of this count was used to calculate the percentages of the individual cell types in each SCC, with the total cell count in each tumour being 100%; (v) the cell density in each tumour was obtained by dividing the total cell count by the tumour section area in mm²; (vi) statistical analysis was carried out with the Mann-Whitney U test, a non-parametric ranking test. The percentages of the individual cell types, as well as the total cell densities in each SCC were ranked, *p*-value < 0.05. Descriptive statistics describe the main features of each variable, stating its median and range (min–max).

Counting of the cells was predominantly carried out by one junior dermatopathologist and dermatologist (BK) with continuous supervision of a senior dermatopathologist (BLR) and in independent agreement with a senior dermatologist (BL).

Definitions for positive cells

The staining pattern for each antibody was assessed carefully and strict criteria for a “positive” cell were defined as including a nucleus or a nuclear shadow. In T and B cells (CD3, CD8, CD20) the staining pattern was intensely membranous, and the cells were round. The CD4 antigen was difficult to assess, apart from having been present in clusters, it not only stained helper T cells but, to a lesser extent, also monocytes, macrophages and dendritic cells. Thus we chose not to count, but to calculate, the number of CD4 cells by subtracting the CD8 count from the CD3 count. In natural killer cells (NK cells, CD56, neural cell adhesion molecule (NCAM)), the staining pattern was mainly membranous with some cytoplasmic staining, and the cells were round. Plasma cells (CD138) had a characteristic silhouette, the staining pattern was cytoplasmic, the cells were round to oval, and the nucleus was partially surrounded by a pale zone. In monocytes (CD14) the staining pattern was both membranous and cytoplasmic; the cells varied in size and shape, some with dendrites. In Langerhans’ cells (CD1a) the staining pattern was membranous, cells varied in shape, some round, others irregular with dendrites. In macrophages (CD68) the staining pattern was intense in cytoplasmic granules and sparsely membranous, these cells were irregularly shaped. Mast cells (Astra Blue) were large, round to oval cells with abundant blue-turquoise cytoplasm and a dark purple nucleus.

We had to accept some overlap in antigen detection between some of the antibodies. For example, CD8, which marked the cytotoxic/suppressor subset of T cells, can also be expressed on a subtype of T cells (gamma delta) and on some NK cells. CD14 antigen, a receptor for bacterial lipopolysaccharide (LPS), expression was intense on cells of the myelomonocytic lineage including monocytes, macrophages and Langerhans’ cells, while lower intensity could be anticipated on neutrophilic granulocytes and B cells. Cells with a marked staining pattern were counted preferentially. CD20 antigen is expressed on pre-pre B cells through to memory cells, but not on either pro-B cells or plasma cells. CD68 antigen also stains some monocytes, neutrophilic and basophilic granulocytes and some NK cells.

RESULTS

In 7 SCCs from immunosuppressed OTR the total number of inflammatory cells counted was 15,818, giving a median density of 328 cells/mm² tumour section area (range 160–523 cells/mm²). In 14 SCCs from immunocompetent control patients the total number of inflammatory cells was 88,352, giving a median density

of 323 cells/mm² tumour section area (range 121–814 cells/mm²). This difference was non-significant. No significant differences were detected in overall cell densities between the two groups when specifically analysing the lateral and the deep tumour margins (Figs 2a and b).

The distribution of different cell types within each individual SCC is shown in 100% columns with absolute cell counts in an adjacent table (Figs 3a and b; c presents all SCCs taken together as a group). We found significant differences in the cellular distributions of 4 cell types: CD3+ T cells were the dominant cells in both groups, the median percentage in OTR was 57% (range 35–78%) and in controls 68% (range 48–80%), *p* = 0.036. The median percentage of plasma cells (CD138+) in OTR was 2% (range 0.7–7%) compared with 0.2% (range 0–1.2%) in controls, *p* = 0.001. The median percentage of monocytes (CD14+), in OTR was 3.2% (range 1.1–5.6%) compared with 9.3% (range 2.2–17.2%) in controls, *p* = 0.014. When calculating the percentage distributions separately for the cells at the lateral and at the deep tumour margins, a significant difference for B cells (CD20+), could be seen: their median percentage at the lateral tumour margins was 12.2% (range 3–38%) in OTR tumours compared with 4.1% (range 0–33%) in controls, *p* = 0.036. Though, there was no difference in the overall distribution of B cells between the two groups. When comparing only the invasive SCCs (5 in OTR and 10 in controls), the difference in CD3+ T cells percentage distributions became more significant (*p* = 0.027).

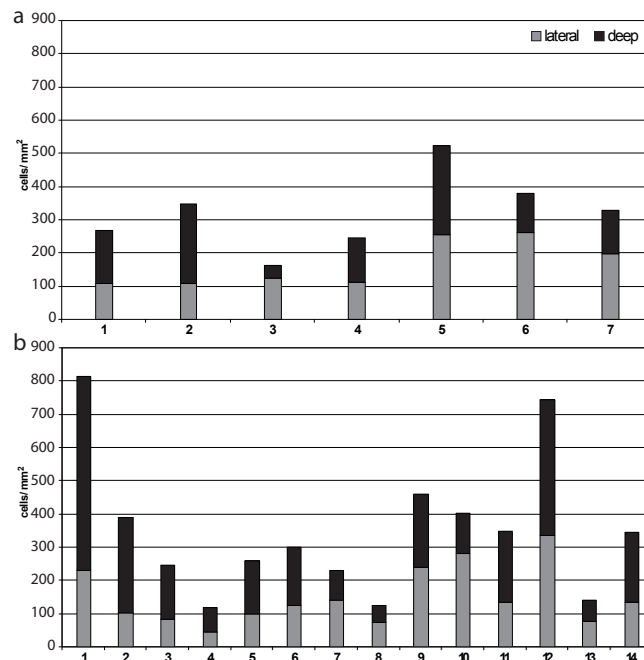


Fig. 2. Cell densities, cells/mm² tumour section area, within each individual squamous cell carcinomas (SCC) at the lateral and the deep tumour margins; (a) in 7 immunosuppressed organ transplant recipients, (b) in 14 immunocompetent controls.

The median CD4+/CD8+ ratio for OTR was 6.5 (range 1.4–20) and for controls 5 (range 2–16); this difference was non-significant. No further differences were found for cell densities or for cellular distributions.

DISCUSSION

This study found surprisingly variable cell counts regarding all inflammatory cell types, leading to a unique composition of the peritumoural infiltrate in each individual

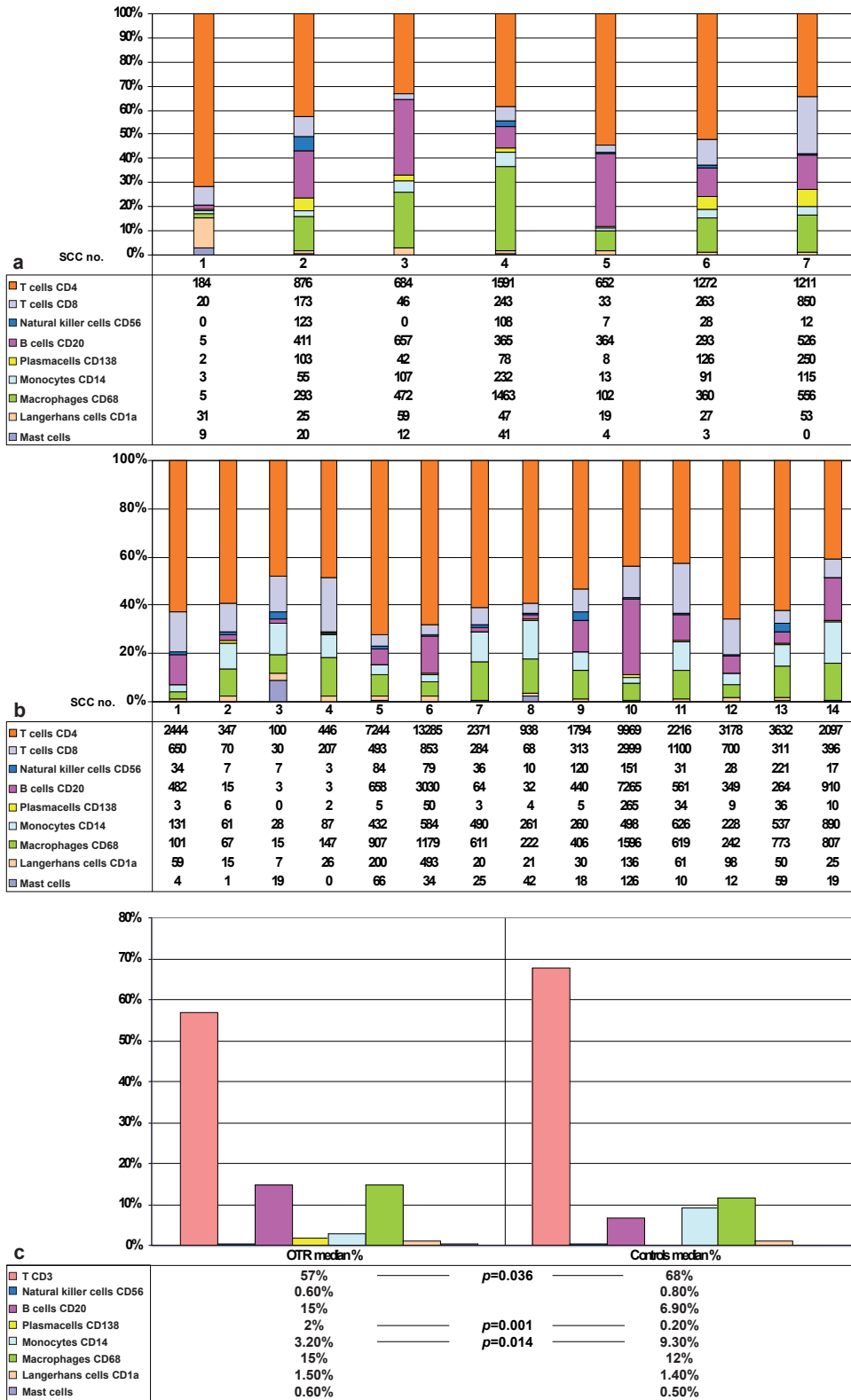


Fig. 3. Cell percentage distributions within the peritumoural infiltrate in each individual squamous cell carcinoma (SCC); (a) in 7 immunosuppressed organ transplant recipients, absolute cell counts shown in table below, (b) in 14 immunocompetent controls, absolute cell counts shown in table below, (c) median cell percentage distributions in all SCCs shown by group, values shown in table below (percentages do not add up to 100 because of median).

tumour (Figs 2 and 3). A total of more than 100,000 cells in 21 tumours were defined and no obvious differences were found in cell densities (cells/mm² tumour section area). Thus, impaired recruitment of inflammatory cells to the target site does not appear to be an issue in OTR. Based on estimations, dense inflammatory infiltrates around SCCs in OTR equal to those adjacent to ordinary SCCs have been reported (20). Overall lower estimated cell densities in SCCs from OTR were observed by others (8, 21, 22). It is possible that our method is more precise, since actual counting was performed, but our sample numbers are low.

The major prevailing cell groups were CD3+ T cells, CD20+ B cells, CD14+ monocytes and CD68+ macrophages, with CD3+ T cells and the CD4+ subtype being the dominating cell group, i.e. our findings confirm earlier reports on the cellular composition of the peritumoural infiltrate in cutaneous SCCs in non-immunosuppressed humans (8, 23, 24). We found significant differences between OTR and controls in 3 out of 9 cell types. CD3+ T cells were significantly lower in number in OTR compared with controls, confirming the results of a recent study (21). These findings could therefore reflect the state of systemic immunosuppression at a peripheral body site, in this case the skin, since it has been shown that immunosuppressive drugs affect lymphocyte subsets and function both *in vivo* and *in vitro* (25, 26).

When subdividing the CD3+ T-cell counts into CD4+ and CD8+ T cells, a much higher CD4+ count was found, with equal CD4+/CD8+ ratios in the two groups. In previous studies on peritumoural inflammation in SCC from immunocompetent patients the CD4+/CD8+ ratio was variable, but somewhat lower (23, 27–31).

Cell counts of CD14+ monocytes were lower in OTR tumours. Since monocytes mature into tissue macrophages, and overlapping of expression of the markers used can be expected, this finding is difficult to interpret. Added to this is the circumstance that no significant differences between OTR and controls were found when calculating the added percentage distributions of monocytes and macrophages.

B cells were only increased in number at the lateral tumour margins in OTR tumours; otherwise their total numbers did not differ from controls. This observation could reflect a more tumour submissive environment at the lateral margins of the OTR tumours. Plasma cell numbers were increased in OTR tumours, but since plasma cell counts were low overall, the difference cannot be interpreted with certainty.

Based on the above findings, our hypothesis for SCC progression in OTR is that the inflammatory balance is somewhat pushed towards a cellular composition promoting tumour progression, that is, a Th2 similar pattern. CD3+ T-cell counts are lower in SCCs in OTR, with a reduced proportion of the tumour rejecting cytotoxic CD8+ T cells. We further speculate that if CD4

regulatory T cells and CD4 T cells of Th2 type are in the majority, they could also facilitate antibody production by B cells and bias the immunity even more towards a tumour-promoting response. In addition, macrophages, being a heterogeneous population of cells, can also contribute to tumour destruction or facilitate tumour growth depending on their phenotype. Tumour destruction is favoured by macrophages that act as antigen-presenting cells and activate cytotoxic CD8 T cells. Since these T cells are in the minority in SCCs in OTR we suggest that the macrophages present are mainly of the tumour-promoting phenotype (TAMS).

In our opinion, one of the strengths of this work is the systematic computer supported counting and measurement of the peritumoural cell infiltrates, which demonstrates how modern software can make traditional manual quantification analysis more transparent.

Another strength is the sharpened OTR cohort; with all patients having had a history of large tumour burden. This cohort, although small, should be highly representative, but the selection of *in situ* tumours and tumours with different grades of differentiation could have made possible differences more difficult to detect.

We are aware of the fact that two different age groups were studied. For the OTR the mean age was 52 years, and for controls 70 years. This difference mirrors the factual ages of patients affected by SCCs in the two groups in Sweden (2, 32).

The overall smaller tumour section area of SCCs in the OTR group could imply that OTR tumours were lesions of shorter duration, whereas the control tumours were more chronic lesions. The difference in size should be seen as a positive effect of frequent skin checks combined with prompt excision in the clinics, as well as increased self-awareness among the OTR patients. On the other hand, the immunocompetent first-time skin SCC patient had a longer latency period, probably due to slower routines in the public healthcare system as well as patient delay factors.

In conclusion, peritumoural infiltrates of SCC in immunosuppressed compared with immunocompetent patients differ in cellular composition but not in cellular density. The differences in cell composition might have consequences for tumour development in OTR. However, the equal recruitment of cells in immunosuppressed and in immunocompetent patients might be strongly affected by the possible deviating functionality of the different cell types in the OTR, about which this study gives no information. Whether the functional status of these cells influences tumour development is uncertain and warrants further research.

ACKNOWLEDGEMENTS

We thank Elisabeth Berg for support with the statistical analysis, Anita Lindström for excellent laboratorial work and Maria

Ulvmar for reviewing the manuscript. This study was supported by grants from the Edward Welander Foundation and the Finsen Foundation.

REFERENCES

- World Health Organization. How common is skin cancer? [cited 2010 Feb 1]. Available from: URL: <http://www.who.int/uv/faq/skincancer/en/index1.html>
- National Board of Health and Welfare CFE. Cancer incidence in Sweden. [cited 2010 Feb 1]. Available from: URL: <http://www.socialstyrelsen.se/publikationer>
- Lindelöf B, Sigurgeirsson B, Gäbel H, Stern RS. Incidence of skin cancer in 5356 patients following organ transplantation. *Br J Dermatol* 2000; 143: 513–519.
- Adami J, Gäbel H, Lindelöf B, Ekström K, Rydh B, Glimelius B, et al. Cancer risk following organ transplantation: a nationwide cohort study in Sweden. *Br J Cancer* 2003; 89: 1221–1227.
- Berg D, Otley CC. Skin cancer in organ transplant recipients: epidemiology, pathogenesis, and management. *J Am Acad Dermatol* 2002; 47: 1–17; quiz 8–20.
- Lindelöf B, Jarnvik J, Ternesten-Bratel A, Granath F, Hedblad MA. Mortality and clinicopathological features of cutaneous squamous cell carcinoma in organ transplant recipients: a study of the Swedish cohort. *Acta Derm Venereol* 2006; 86: 219–222.
- Smith KJ, Hamza S, Skelton H. Histologic features in primary cutaneous squamous cell carcinomas in immunocompromised patients focusing on organ transplant patients. *Dermatol Surg* 2004; 30: 634–641.
- Harwood CA, Proby CM, McGregor JM, Sheaff MT, Leigh IM, Cerio R. Clinicopathologic features of skin cancer in organ transplant recipients: a retrospective case-control series. *J Am Acad Dermatol* 2006; 54: 290–300.
- Buell JF, Gross TG, Woodle ES. Malignancy after transplantation. *Transplantation*. 2005; 80: S254–264.
- O'Donovan P, Perrett CM, Zhang X, Montaner B, Xu YZ, Harwood CA, et al. Azathioprine and UVA light generate mutagenic oxidative DNA damage. *Science* 2005; 309: 1871–1874.
- Odenbro Å. Skin cancer in relation to tobacco use and organ transplantation [thesis]. Stockholm: Karolinska Institutet; 2009.
- Balkwill F, Mantovani A. Inflammation and cancer: back to Virchow? *Lancet* 2001; 357: 539–545.
- Mueller MM. Inflammation in epithelial skin tumours: old stories and new ideas. *Eur J Cancer* 2006; 42: 735–744.
- Kundu JK, Surh YJ. Inflammation: gearing the journey to cancer. *Mutat Res* 2008; 659: 15–30.
- Ostrand-Rosenberg S. Immune surveillance: a balance between protumor and antitumor immunity. *Curr Opin Genet Dev* 2008; 18: 11–18.
- Smith KJ, Hamza S, Skelton H. Topical imidazoquinoline therapy of cutaneous squamous cell carcinoma polarizes lymphoid and monocyte/macrophage populations to a Th1 and M1 cytokine pattern. *Clin Exp Dermatol* 2004; 29: 505–512.
- Clark RA, Huang SJ, Murphy GF, Mollet IG, Hijnen D, Muthukuru M, et al. Human squamous cell carcinomas evade the immune response by down-regulation of vascular E-selectin and recruitment of regulatory T cells. *J Exp Med* 2008; 205: 2221–2234.
- LeBoit PE, Weedon D, Sarasin A. World Health Organization Classification of Tumours. Pathology and Genetics of Skin Tumours. Lyon: IARC Press, 2006: p. 30–32.
- Duffy JP, Smith PJ, Crocker J, Matthews HR. Combined staining method for the demonstration of tissue eosinophils and mast cells. *J Histotechnol* 1993; 16: 143–144.
- Mehrany K, Byrd DR, Roenigk RK, Weenig RH, Phillips PK, Nguyen TH, et al. Lymphocytic infiltrates and sub-clinical epithelial tumor extension in patients with chronic leukemia and solid-organ transplantation. *Dermatol Surg* 2003; 29: 129–134.
- Muhleisen B, Petrov I, Gachter T, Kurrer M, Scharer L, Dummer R, et al. Progression of cutaneous squamous cell carcinoma in immunosuppressed patients is associated with reduced CD123+ and FOXP3+ cells in the perineoplastic inflammatory infiltrate. *Histopathology* 2009; 55: 67–76.
- Hoyo E, Kanitakis J, Euvrard S, Thivolet J. Proliferation characteristics of cutaneous squamous cell carcinomas developing in organ graft recipients. Comparison with squamous cell carcinomas of nonimmunocompromised hosts by counting argyrophilic proteins associated with nucleolar organizer regions. *Arch Dermatol* 1993; 129: 324–327.
- Haeffner AC, Zepter K, Elmets CA, Wood GS. Analysis of tumor-infiltrating lymphocytes in cutaneous squamous cell carcinoma. *Arch Dermatol* 1997; 133: 585–590.
- Hussein MR, Ahmed RA. Analysis of the mononuclear inflammatory cell infiltrate in the non-tumorigenic, pre-tumorigenic and tumorigenic keratinocytic hyperproliferative lesions of the skin. *Cancer Biol Ther* 2005; 4: 819–821.
- Bravo Soto JA, Esteban de la Rosa RJ, Luna del Castillo JD, Cerezo Morales S, Garcia Olivares E, Osuna Ortega A, et al. Effect of mycophenolate mofetil regimen on peripheral blood lymphocyte subsets in kidney transplant recipients. *Transplantation Proc* 2003; 35: 1355–1359.
- Lebec H, Roger R, Blot C, Burleson GR, Bohuon C, Pallardy M. Immunotoxicological investigation using pharmaceutical drugs. In vitro evaluation of immune effects using rodent or human immune cells. *Toxicology* 1995; 96: 147–156.
- Claudatus JC, Jr., d'Ovidio R, Lospalluti M, Meneghini CL. Skin tumors and reactive cellular infiltrate: further studies. *Acta Derm Venereol* 1986; 66: 29–34.
- Fernandez-Bussy R, Cambazard F, Mauduit G, Schmitt D, Thivolet J. T cell subsets and Langerhans cells in skin tumours. *Eur J Cancer Clin Oncol* 1983; 19: 907–913.
- Gatter KC, Morris HB, Roach B, Mortimer P, Fleming KA, Mason DY. Langerhans' cells and T cells in human skin tumours: an immunohistological study. *Histopathology* 1984; 8: 229–244.
- Habets JM, Tank B, van Joost T. Characterization of the mononuclear infiltrate in Bowen's disease (squamous cell carcinoma in situ). Evidence for a T cell-mediated antitumor immune response. *Virchows Arch A Pathol Anat Histopathol* 1989; 415: 125–130.
- Kohchiyama A, Oka D, Ueki H. Immunohistologic studies of squamous cell carcinoma: possible participation of Leu-7+ (natural killer) cells as antitumor effector cells. *J Invest Dermatol* 1986; 87: 515–518.
- Lindelöf B, Dal H, Wolk K, Malmborg N. Cutaneous squamous cell carcinoma in organ transplant recipients: a study of the Swedish cohort with regard to tumor site. *Arch Dermatol* 2005; 141: 447–451.