

## Possible Acceleration of Regression by Antibiotic Treatment in Benign Cephalic Histiocytosis with Infiltration of CD11a/CD11c+ Macrophages

Sven R. Quist, Heike Weidling, Ingolf Franke, Bernd Bonnekoh and Harald P. Gollnick

Department of Dermatology and Venereology, Otto-von-Guericke University, Leipziger Str. 44, DE-39120 Magdeburg, Germany. E-mail: squist@gmx.de  
Accepted February 15, 2010.

Benign cephalic histiocytosis (BCH) is a rare non-Langerhans' cell histiocytosis (non-LCH) first reported by Gianotti et al. (1). It is characterized by an asymptomatic spontaneous eruption of reddish to brownish macules and papules on the head, mainly on the cheeks, eyebrows, forehead, ears, and neck, which spread later to the trunk and arms (1–3). It occurs within the first 3 years in infants of both sexes, resulting in, usually spontaneous, unscarred regression (2, 3). The aetiology of BCH is unknown; however, some cases report a coincidence with metabolic disorders such as diabetes insipidus and diabetes mellitus (4, 5).

### CASE REPORT

A 1-year-old boy presented with reddish nodules around both upper and lower eyelids. The nodules increased in size and number, with a further spreading onto the cheeks, chin and forehead. Two months later, multiple, brownish to reddish nodules, up to 2 cm in size, arose all over the face, on the eyelids, cheeks, chin and forehead, partially pus-filled, and partially incised (Fig. 1 A–C). Clinical investigation showed a normally developed small child except for an innate skull deformity, treated with a head orthosis. Laboratory tests showed IgA (< 0.22 g/l; range: 0.30–1.40) and zinc (11.3  $\mu\text{mol/l}$ ; range: 11.5–15.3) deficiency and activated natural killer (NK) cells in peripheral blood count, but normal values for sex hormones and cortisol, which could exclude acne infantum in the context of an androgenital syndrome. Antinuclear as well as autoimmune antibodies and circulating immune complexes were absent. Microbiology from purulent material of the nodules was positive for *Staphylococcus aureus*. Histological results upon skin biopsy from the forehead and right cheek were compatible with a non-LCH and the subtype of benign cephalic histiocytosis. Histology and immune histochemistry demonstrated granulomatous inflammation with xantho-

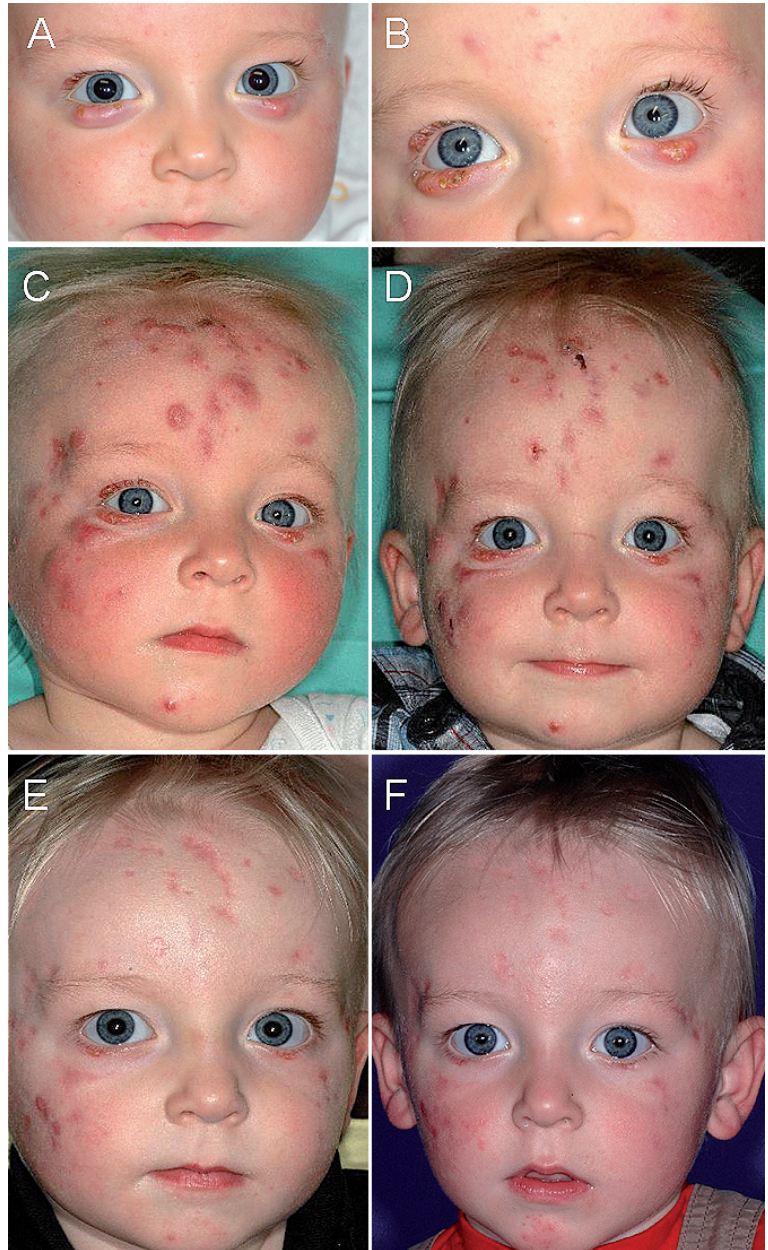


Fig. 1. (A–C) Development and regression of benign cephalic histiocytosis, (D) after 3, (E) 6 and (F) 9 months. Photos are published after permission from the parents.

matous macrophages positive for CD68 with co-expression of CD11a and CD11c (Fig. 2), negative for S100, CD23 (FcER II) and CD1a. Proliferation rate confirmed by Ki67 staining was moderate (15%). In contrast to low plasma IgA levels, high IgA expression was observed in skin biopsies. The patient was treated

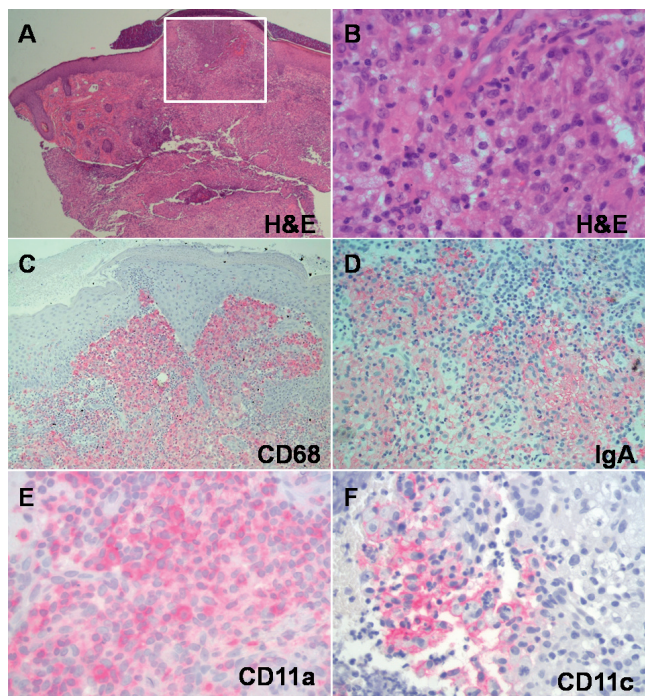


Fig. 2. Histology of benign cephalic histiocytosis with infiltrates positive for CD68, IgA, CD11a and CD11c (A ( $\times 40$ ), C ( $\times 100$ ), D ( $\times 200$ ), B, E, F (all  $\times 400$ )).

with cefuroxime for 1 week, followed by erythromycin, and further examined at 3-monthly intervals. After 3 months initial regression of the nodules was observed, which was almost complete at 6 and complete at 9 months (Fig. 1 D–F).

## DISCUSSION

We report here, for the first time, that infiltrates of histiocytes and macrophages in BCH highly express the 150 kDa glycoprotein CD11c, a member of the  $\alpha$ -subunit of  $\beta_2$  integrin-family with co-expression of CD11a (LFA-1). CD11c is expressed on monocytes, highly on tissue macrophages and immature myeloid cutaneous dendritic cells, on granulocytes and plays a role in mediating adherence of granulocytes and monocytes to endothelium and fibrinogen by ligands such as ICAM-1, iC3b, and fibrinogen (6). In the lung, CD11c-positive dendritic cells have been shown to expand early and rapidly after exposure to super antigens such as *S. aureus*, whereas NK cells were absent upon stimulation (7). Human CD11c-positive monocyte-derived dendritic cells within sites of eosinophilic airway inflammation exposed to dust mite allergens such as Der p1, produce high amounts of Th2-selective chemokines, indicating that these cells act as effectors for a proper Th2 immune response (8, 9). However,

NK cells are activated in response to *Staphylococcus aureus* exposure via a Th1 immune response (10). Despite high expression of CD11c with co-expression of CD11a on macrophages and activation in peripheral blood cells, only a very low level of dermal NK cells were observed in the dermis, suggesting a Th2-directed immune response to bacterial challenge with *S. aureus*. This may explain the initiation of regression observed 3 months after antibiotic treatment, which is below the average of 2 years (with an onset range of 8–48 months) reported in the literature (2). Antibiotic treatment was required because of IgA deficiency and bacterial superinfection, and this might have resulted in an early complete regression (reported range of remission in the literature: 9–108 months (2)).

## REFERENCES

- Gianotti F, Caputo R, Ermacora E. Singulière "histiocytose infantile à cellules avec particules vermiformes intracytoplasmiques. Bull Soc Fr Dermatol Syphiligr 1971; 78: 232–233.
- Jih DM, Salcedo SL, Jaworsky C. Benign cephalic histiocytosis: a case report and review. J Am Acad Dermatol 2002; 47: 908–913.
- Dadzie O, Hopster D, Cerio R, Wakeel R. Benign cephalic histiocytosis in a British-African child. Pediatr Dermatol 2005; 22: 444–446.
- Saez-De-Ocariz M, Lopez-Corella E, Duran-McKinster C, Orozco-Covarrubias L, Ruiz-Maldonado R. Benign cephalic histiocytosis preceding the development of insulin-dependent diabetes mellitus. Pediatr Dermatol 2006; 23: 101–102.
- Weston WL, Travers SH, Mierau GW, Heasley D, Fitzpatrick J. Benign cephalic histiocytosis with diabetes insipidus. Pediatr Dermatol 2000; 17: 296–298.
- Zaba LC, Fuentes-Duculan J, Steinman RM, Krueger JG, Lowes MA. Normal human dermis contains distinct populations of CD11c+BDCA-1+ dendritic cells and CD163+FXIIIa+ macrophages. J Clin Invest 2007; 117: 2517–2525.
- Muralimohan G, Rossi RJ, Vella AT. Recruitment and in situ renewal regulate rapid accumulation of CD11c+ cells in the lung following intranasal superantigen challenge. Int Arch Allergy Immunol 2008; 147: 59–73.
- van Rijt LS, Jung S, Kleinjan A, Vos N, Willart M, Duez C, et al. In vivo depletion of lung CD11c+ dendritic cells during allergen challenge abrogates the characteristic features of asthma. J Exp Med 2005; 201: 981–991.
- Wedi B, Wieczorek D, Stunkel T, Breuer K, Kapp A. Staphylococcal exotoxins exert proinflammatory effects through inhibition of eosinophil apoptosis, increased surface antigen expression (CD11b, CD45, CD54, and CD69), and enhanced cytokine-activated oxidative burst, thereby triggering allergic inflammatory reactions. J Allergy Clin Immunol 2002; 109: 477–484.
- Haller D, Serrant P, Granato D, Schiffrin EJ, Blum S. Activation of human NK cells by staphylococci and lactobacilli requires cell contact-dependent costimulation by autologous monocytes. Clin Diagn Lab Immunol 2002; 9: 649–657.