

CLINICAL REPORT

Hepatocellular Carcinoma in Variegate Porphyrria: A Serious Complication

Xiaoye SCHNEIDER-YIN^{1*}, Anne-Moon VAN TUYLL VAN SEROOSKERKEN^{2-5*}, Philip WENT⁶, Wojciech TYBLEWSKI⁷, Pamela POBLETE-GUTIÉRREZ²⁻⁵, Elisabeth I. MINDER¹ and Jorge FRANK²⁻⁵

¹Zentrallabor and Swiss Porphyrin Reference Laboratory, Stadtspital Triemli, Zürich, Switzerland, ²Department of Dermatology, ³Maastricht University Centre for Molecular Dermatology (MUCMD), ⁴Euregional Porphyrria Centre Maastricht and ⁵GROW – School for Oncology and Developmental Biology, Maastricht University Medical Centre (MUMC), The Netherlands, ⁶Institute of Pathology, Stadtspital Triemli, Zürich, and ⁷Department of Internal Medicine, Spital Limmattal, Schlieren, Switzerland

*The first two authors contributed equally to this manuscript and should be considered as first authors.

Variegate porphyria is an acute hepatic porphyria resulting from a partial deficiency of protoporphyrinogen oxidase, the penultimate enzyme in haem biosynthesis. Cutaneous symptoms and acute neurovisceral attacks are well-known clinical characteristics of the disease. Less studied, however, is the risk of developing hepatocellular carcinoma, an aggressive type of liver cancer. We describe here two Swiss patients with variegate porphyria and this serious complication. Common risk factors, including alcohol over-consumption or chronic hepatitis, were absent in both patients. Interestingly, one patient carried mutation 1082–1083insC in the *PPOX* gene, a prevalent sequence deviation in the Swiss variegate porphyria population, which was also found in a French patient with variegate porphyria and hepatocellular carcinoma. Recent studies indicate that individuals with acute hepatic porphyria have a 36- to 61-fold increased risk of manifesting hepatocellular carcinoma. The incidence rate ratio in the Swiss population was estimated to be 34, comparable with those found in the French and Finnish populations. Because this tumour is associated with a rising mortality, we suggest regular screening for hepatocellular carcinoma in all patients with variegate porphyria. Key words: porphyria; haem biosynthesis; acute hepatic porphyria; variegate porphyria; hepatocellular carcinoma.

(Accepted February 11, 2010.)

Acta Derm Venereol 2010; 90: 512–515.

Jorge Frank, Maastricht University Centre for Molecular Dermatology (MUCMD), Department of Dermatology, P. Debyelaan 25, PO Box 5800, NL-6202 AZ Maastricht, The Netherlands. E-mail: j.frank@mumc.nl

Variegate porphyria (VP; OMIM 176200) is one of the acute hepatic porphyrias. The disease results from an autosomal dominantly inherited deficiency of protoporphyrinogen oxidase (PPOX; EC 1.3.3.4), the seventh enzyme in the haem biosynthetic pathway (1, 2).

Affected individuals can develop both cutaneous and potentially life-threatening neurovisceral symptoms. Skin findings include increased photosensitivity, ab-

normal skin fragility, blistering of sun-exposed areas, erosions, milia, scarring, and hypertrichosis. Neurovisceral symptoms commonly comprise acute attacks of abdominal pain, nausea, vomiting, muscle weakness, tachycardia, hypertension, electrolyte disturbances, and constipation. These clinical signs can progress to hemi- and tetraplegia, respiratory failure, and coma (1, 2).

Biochemical analyses are mandatory to make a correct diagnosis of VP because the skin symptoms encountered cannot be differentiated clinically or histologically from those observed in porphyria cutanea tarda (PCT) or hereditary coproporphyria (HCP) (1). Likewise, the neurological symptoms encountered can also be observed in other forms of acute hepatic porphyrias, such as acute intermittent porphyria (AIP) and HCP (3). Heterozygous mutations in the *PPOX* gene, which is located on chromosome 1q22, are responsible for a reduction in enzyme activity of approximately 50%. However, only approximately 20% of the VP mutation carriers will develop clinical symptoms due to incomplete penetrance of the disease (4).

A rather uncommon, but serious, complication in the acute hepatic porphyrias is hepatocellular carcinoma (HCC). In this study, we report on the occurrence of HCC in two Swiss patients with VP.

CASE REPORTS

Patient 1

In September 2006, a then 82-year-old Swiss woman was referred to our porphyria outpatient clinic with cutaneous symptoms, consisting of blistering, increased skin fragility and itching on the hands and forearms (Fig. 1). These alterations had developed in the summer of 2005. However, the occurrence of the first clinical signs of the disease most likely dated back to 1952 when she was 28 years old and had undergone appendectomy. The patient recalled passing dark urine after surgery and was subsequently hospitalized for 3 months. Although the medical records of that hospitalization were no longer available, the symptoms described by the patient were suggestive of an acute neurovisceral attack of porphyria. Indeed, she received a diagnosis of “porphyria” and was advised to avoid porphyrinogenic drugs. Thereafter, she remained free of acute symptoms.

Since the diagnosis had been established more than 50 years ago without further classification of the exact type of porphyria, we conducted a series of biochemical analyses in order to

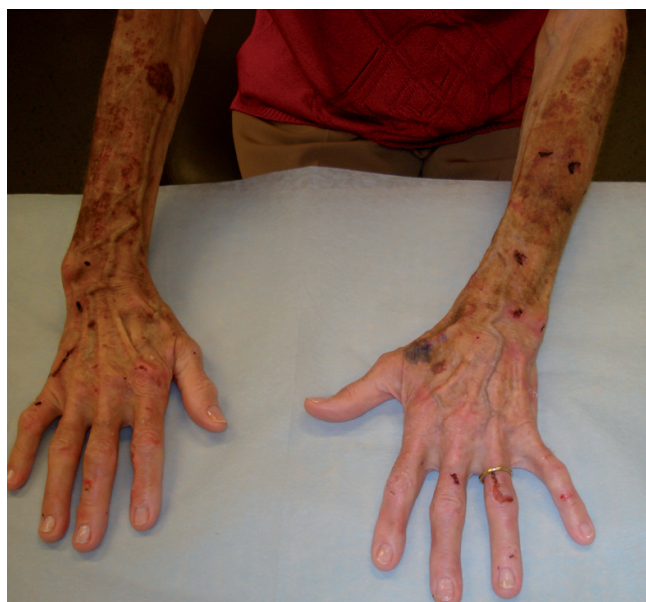

Fig. 1. Haemorrhagic blisters, erosions, crusts and milia on the back of the hands and the distal forearms of patient 1.

confirm and refine the previous diagnosis. As shown in Table I, urinary porphyrin precursors, δ -aminolaevulinic acid (ALA) and porphobilinogen (PBG) were within the normal range. Urinary porphyrins were slightly increased. In addition, an elevated content of coproporphyrin isomer III was observed in the faeces. Plasma fluorescence emission scan identified a peak at 624–626 nm, which is characteristic for VP. Subsequent molecular analysis of the *PPOX* gene revealed a frameshift mutation, 1082–1083insC, stop+18, thereby confirming the diagnosis at the molecular level (data not shown).

In February 2006, 6 months after the occurrence of cutaneous symptoms, a tumour of 10×12×15 cm was discovered in the right hepatic lobe by ultrasonography. Based on ultrasonic imaging of the liver and a massively elevated serum α -foetoprotein level (17'055 μ g/l; normal < 7), a diagnosis of HCC was made. Haematological analysis revealed a microcytic and hypochromic anaemia at the time of tumour diagnosis. In addition, her serum iron concentration was decreased to 5.5 μ mol/l (normal 10.6–28.3) and serum transferrin saturation to 9% (normal 23–46%). Since the tumour was no longer operable and her general condition did not allow for chemo-/radiotherapy, she received palliative care. The patient died in October 2007, 20 months after the initial diagnosis of HCC.

Autopsy revealed multiple and partial necrotic nodules, in addition to a hypertrophic, irregular macronodular cirrhosis of the liver (Fig. 2a). Microscopic examination of the tumour showed a multifocal, moderately differentiated hepatocellular

Table I. Results of biochemical analyses in the two variegate porphyria patients studied

Analyses ^a	Patient 1	Patient 2
Urinary porphyrin precursors		
Aminolaevulinic acid (<1.25 μ mol/mmol creatinine)	1.6	not done
Porphobilinogen (1.25 μ mol/mmol creatinine)	0.3	not done
Urinary porphyrins		
Uroporphyrin (<3.9 μ mol/mmol creatinine)	5.9	8.7
Heptacarboxyl porphyrin (<1.0 μ mol/mmol creatinine)	1.3	1.3
Hexacarboxyl porphyrin (<1.0 μ mol/mmol creatinine)	2.2	<0.01
Pentacarboxyl porphyrin (<1.0 μ mol/mmol creatinine)	2.6	0.4
Coproporphyrin isomer I (<8.4 μ mol/mmol creatinine)	5.6	1.5
Coproporphyrin isomer III (<17.8 μ mol/mmol creatinine)	25.0	6.7
Faecal porphyrins		
Coproporphyrin isomer I (<20 nmol/g dry weight)	15.4	8.1
Coproporphyrin isomer III (<12 nmol/g dry weight)	24.4	14.6
Protoporphyrin IX (<80 nmol/g dry weight)	62.8	8.5
Plasma fluorescence scan (peak at 624–626 nm)	Positive	Positive

^aReference ranges are given in parentheses. Pathological values are in bold.

carcinoma (G2) (Fig. 2b). The pancreas was slightly fibrotic and displayed a peripancreatic fat necrosis as the result of acute pancreatitis. Non-specific cutaneous ulcers and petechiae were found on the extremities, head and neck.

Patient 2

A Swiss female developed blistering and increased skin fragility at the sun-exposed areas of her body at the age of 80 years. No previous history of porphyria was recorded. Laboratory analysis revealed increased levels of uroporphyrin and heptacarboxyl porphyrin in urine, and coproporphyrin isomer III in the faeces. A peak was detected at 624–626 nm by plasma fluorescence emission scanning (Table I). Based on the clinical symptoms and biochemical findings, a diagnosis of VP was made. Genetic testing was not performed.

The patient's medical history revealed a diagnosis of HCC made by liver biopsy at the age of 75 years. She was treated with microwave thermal ablation. Besides VP and HCC, the patient also suffered from hypertension, coronary heart disease, and renal insufficiency. Three years later, a second tumour was discovered in the right lobe of the liver by ultrasonography. Another ultrasonic imaging performed when the patient was 81 years old, showed that the cancer at the initial site had grown to 10 cm in diameter and the second tumour to 8 cm in diameter. The patient died at the age of 82 years, 2 years after the occurrence of cutaneous symptoms, due to progression of HCC. No autopsy was performed.

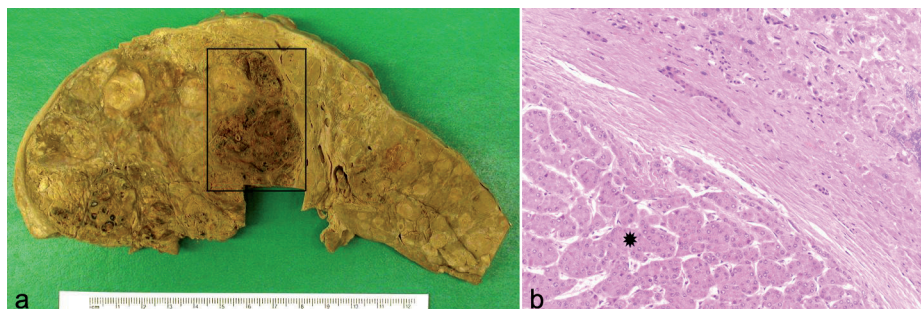


Fig. 2. Hepatocellular carcinoma in patient 1. (a) A section of alcohol fixed liver shows a haemorrhagic and necrotic hepatocellular carcinoma (area inside the rectangular frame) surrounded by irregular cirrhotic nodules and fibrotic bands. (b) Microscopic image shows a moderately differentiated hepatocellular carcinoma (asterisk) and residual cirrhotic liver tissue (haematoxylin and eosin; original magnification \times 20).

DISCUSSION

HCC represents the most frequent type of primary liver cancer, with approximately 500,000 new cases per year worldwide. Although the incidence of HCC in industrialized countries is lower than that in Africa and Asia, a marked increase in this tumour and its related mortality have been observed both in the USA and Europe during recent years (5). Well-known risk factors in the latter continent comprise alcohol over-consumption, chronic infection with hepatitis B (HBV) and C (HCV) viruses, and cirrhosis (5, 6).

Recently, the autosomal dominantly inherited acute hepatic porphyrias AIP, VP, and HCP have also been implicated as risk factors for the development of HCC (7–10). These three types of porphyria are due to a partial catalytic deficiency of specific enzymes in the haem biosynthetic pathway (1, 2). Since the first report on the concomitant occurrence of HCC and AIP in 1984, several mortality studies and case-control studies have demonstrated an association between this type of primary liver cancer and the acute hepatic porphyrias in Europe (7–10).

An association between HCC and AIP, the most common type of acute hepatic porphyria, was first suggested by Lithner & Wetterberg (7). In a study of 245 Finnish patients with acute hepatic porphyria, HCC was found in 6 of the 184 AIP patients (3%) (8). A more recent prospective cohort study conducted in France involved 430 AIP patients and asymptomatic individuals. In the AIP cohort, 5 patients had HCC, reflecting a 1% incidence of HCC. According to the French study, patients with an acute hepatic porphyria in general had a 36-fold increased risk of manifesting HCC (10). In the Finnish study, this risk was 61-fold when compared with the general population (8).

Interestingly, fewer patients with HCC have been reported in VP than in AIP to date. In the afore-mentioned two cohort studies comprising 61 Finnish and 136 French VP patients, respectively, only one VP patient in each cohort developed HCC (8, 10). Two additional VP patients who manifested HCC were reported in Great Britain (11, 12). Apparently, all six known cases of VP with associated HCC, including the two in this study, were of European origin (8, 10–12). To date, no VP patients with HCC have been reported in other countries with a large VP population, such as South Africa.

In two large studies on the overall mortality of HCC conducted in Europe and Switzerland, the majority of individuals with HCC were male (5, 13). In Switzerland the male-to-female ratio was 4:1 (13). Thus far, the overall gender ratio of acute porphyria-related HCC is 1:1.5, calculated from a total of 11 male and 16 female patients with either AIP, VP or HCP in the Finnish (5 males and 2 females), Swedish (3 males and 6 females), French (3 males and 4 females) and Swiss (4 females) studies

(8–10, 14). Single case reports were excluded from this calculation because of the potential reporting bias.

Currently, 30 unrelated VP index patients and families are known in the Swiss Porphyrin Reference Laboratory and Porphyria Outpatient Clinic in Zürich. In addition, seven individuals from these families were diagnosed as asymptomatic mutation carriers, giving rise to a total of 37 individuals affected with VP. The two Swiss VP cases associated with HCC were observed during a period of 16 years since the clinic began to operate in 1993 (14). The incidence of this tumour in our VP cohort is therefore 0.3% (incidence/patient and carriers/year). Thus, VP constitutes an important risk factor for the development of HCC, which is in agreement with the finding of the previous French and Finnish studies. Of note, the incidence of HCC in our AIP cohort of 111 patients and 94 asymptomatic carriers during the same observation period was only 0.06%, i.e. two cases of HCC were identified among the 205 individuals (14).

The overall incidence rate ratio for HCC in acute porphyria in the Swiss population was therefore estimated to be 34 (4 cases of HCC among a total of 242 individuals with either AIP and VP during a 16-year observation period; and an Age Standardised Mortality Rate (ASMR) of 2.9 for primary liver cancer in the Swiss population, according to Mullhaupt et al., was used) (13, 14). Although this number was obtained from a relatively small patient population, it is comparable with those observed in the French and Finnish studies, i.e. incidence rate ratios of 36 and 61 in the French and Finnish populations, respectively (8, 10).

Besides VP, no other risk factors for HCC, such as alcohol over-consumption and chronic hepatitis were identified in either of our patients. However, autopsy revealed liver cirrhosis in patient 1, indicating that chronic hepatic damage existed prior to cancer development. The subclinical/clinical VP, i.e. previous history of VP symptoms, seemed to be the only explanation for liver cirrhosis and HCC in this patient. In patient 2, however, HCC was diagnosed before VP symptoms appeared. A similar observation was made in the French study, in that 3 of the 7 patients who developed HCC were asymptomatic of acute hepatic porphyria (10). So far, the exact pathomechanism that underlies carcinogenesis in the acute porphyrias remains elusive (10, 11). The fact is that both patients and asymptomatic mutation carriers of acute hepatic porphyrias are at risk of developing HCC.

A unique molecular feature shared by many Swiss VP patients is the recurrent mutation 1082–1083insC, stop+18 apparently due to a founder effect (15, 16). To date, 21 of the 30 patients with VP have undergone DNA testing. Mutation 1082–1083insC was identified in 14 of the 21 individuals studied, giving a prevalence of 67% (14). Interestingly, the same mutation was also reported in the VP French patient with HCC (Table II) (10). Hence, the possibility of mutation 1082–1083insC

Table II. Overview of the six known cases of variegate porphyria (VP) associated with hepatocellular carcinoma (HCC)

Pat. no/ Sex	Age at diagnosis (years)	Age at death (years)	VP clinical symptoms	Mutation in the PPOX gene	Staging of HCC	Cirrhosis in the liver	Reference
1/M	66	Unknown	Not mentioned specifically	Unknown	G1	No	Kauppinen & Mustajoki, 1988 (8)
2/F	70	71	Cutaneous lesion only	Unknown	G1	Unknown	Tidman, et al., 1989 (11)
3/F	79	80	Cutaneous lesion only	Unknown	Unknown	Unknown	Grabczynska, et al., 1996 (12)
4/F	54	Alive 16 mo. later	Cutaneous lesion only	1082–1083ins C	G1	No	Andant, et al., 2000 (10)
5/F	81	83	Both cutaneous and neurological symptoms	1082–1083ins C	G2	Yes	This study
6/F	75	82	Cutaneous lesion only	Unknown	Unknown	Unknown	This study

being associated with a high incidence of HCC or a possible genotype-phenotype correlation certainly deserves further exploration (5, 13).

Based on the two patients presented here and the experience of other European porphyria centres, an acute hepatic porphyria should be excluded in patients with HCC who do not reveal any of the well-known risk factors for development of this type of primary liver cancer. Currently, the evolving role of the acute hepatic porphyrias, including VP, in the aetiopathogenesis of this tumour may be underestimated; a notion that is supported by previous reports (8, 10, 11). Because HCC is associated with a considerable and rising mortality in the Swiss and in European populations and its prognosis depends on an early therapeutic intervention, we strongly believe that a regular screening for early diagnosis of HCC would be advisable in patients with VP or other types of acute porphyria. However, the optimal age for implementation of such a screening programme remains to be determined. According to the French and the Finnish studies, the youngest case of HCC was a 37-year-old female patient with AIP (8, 10). The majority of the patients had their initial HCC diagnosis made after the age of 50 years. In our porphyria centre, we perform an annual HCC-screening among all patients and asymptomatic carriers of AIP, VP and HCP aged ≥ 47 years. The programme includes ultrasonography of the liver and serum α -fetoprotein concentration. Now that the potentially life-threatening neurovisceral attacks can be largely avoided due to early diagnosis and preventative measures, serious complications such as HCC should be given more attention in the management of acute hepatic porphyrias.

ACKNOWLEDGEMENTS

JF is a board member of the European Porphyria Initiative (EPI) and was, in part, supported by grant number A04155HS, GIS-Institut des Maladies rares: Network on rare diseases to the European Porphyria Initiative (EPI), and a grant from the European Union to the European Porphyria Network (EPNET), Program of Community Action in the Field of Public Health, project no. 2006107 and a grant from the Research Committee of the Heinrich-Heine University Düsseldorf, Germany, project no. 9772425.

EIM is also a board member of the EPI and a recipient of grants from the Hartmann-Müller Stiftung (no. 1187) and from the Velux Stiftung (project no. 480).

REFERENCES

1. Bickers DR, Frank J. The porphyrias. In: Wolff K, Goldsmith LA, Katz SI, Gilchrist BA, Paller A, Leffell DJ, editors. Fitzpatrick's dermatology in general medicine, 7th edn, vol. 2. New York: McGraw Hill, 2007: p. 1228–1256.
2. Kauppinen R. Porphyrias. *Lancet* 2005; 365: 241–252.
3. Nordmann Y, Puy H. Human hereditary hepatic porphyrias. *Clin Chim Acta* 2002; 325: 17–37.
4. Kirsch R, Meissner P, Hift R. Variegated porphyria. *Sem Liver Dis* 1998; 18: 33–41.
5. Bosetti C, Levi F, Boffetta P, Lucchini F, Negri E, La Vecchia C. Trends in mortality from hepatocellular carcinoma in Europe, 1980–2004. *Hepatology* 2008; 48: 137–145.
6. Hardell L, Bengtsson NO, Jonsson U, Eriksson S, Larsson LG. Aetiological aspects on primary liver cancer with special regard to alcohol, organic solvents and acute intermittent porphyria, an epidemiological investigation. *Br J Cancer* 1984; 50: 389–397.
7. Lithner F, Wetterberg L. Hepatocellular carcinoma in patients with acute intermittent porphyria. *Acta Med Scand* 1984; 215: 271–274.
8. Kauppinen R, Mustajoki P. Acute hepatic porphyria and hepatocellular carcinoma. *Br J Cancer* 1988; 57: 117–120.
9. Andersson C, Bjersing L, Lithner F. The epidemiology of hepatocellular carcinoma in patients with acute intermittent porphyria. *J Intern Med* 1996; 240: 195–201.
10. Andant C, Puy H, Bogard C, Faivre J, Soulé JC, Nordmann Y, et al. Hepatocellular carcinoma in patients with acute hepatic porphyria: frequency of occurrence and related factors. *J Hepatology* 2000; 32: 933–939.
11. Tidman MJ, Higgins EM, Elder GH, MacDonald DM. Variegated porphyria associated with hepatocellular carcinoma. *Br J Dermatol* 1989; 121: 503–505.
12. Grabczynska SA, McGregor JM, Hawk JL. Late onset variegated porphyria. *Clin Exp Dermatol* 1996; 21: 353–356.
13. Mülhaupt B, Junker C, Wuest E, Renner EL. Mortality from primary liver cancer in Switzerland from 1975 to 1994. *Swiss Med Wkly* 2008; 138: 313–316.
14. Schneider-Yin X, Harms J, Minder EI. Porphyria in Switzerland, 15 years experience. *Swiss Med Wkly* 2009; 139: 198–206.
15. Schneider-Yin X, Minder EI. Swiss patients with variegated porphyria have unique mutations. *Swiss Med Wkly* 2006; 136: 515–519.
16. Van Tuyl R, Serooskerken A, Schneider-Yin X, Schimmel R, Bladergroen R, Barman J, et al. Identification of a recurrent mutation in the protoporphyrinogen oxidase gene in Swiss patients with variegated porphyria: clinical and genetic implications. *Cell Mol Biol (Noisy-le-grand)* 2009; 55: 96–101.