

## QUIZ SECTION

### Nodular Rash in a Male Patient: A Quiz

Rym Benmously Mlika<sup>1</sup>, Emna Gouider<sup>2</sup>, Houda Hammami<sup>1</sup>, Nedra Sliti<sup>1</sup>, Salima Ben Jennet<sup>1</sup>, Hela Ben Abid<sup>2</sup>, Incaf Mokhtar<sup>1</sup> and Samy Fenniche<sup>1</sup>

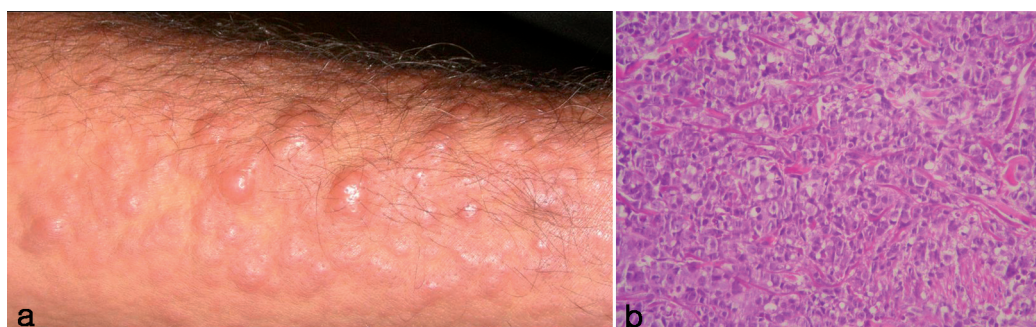
<sup>1</sup>Department of Dermatology, Habib Thameur Hospital, No. 8, Ali Ben Aayed Street, 1008 Monfleury and <sup>2</sup>Department of Hematology, Aziza Othmana Hospital, Tunis, Tunisia. E-mail: rym.benmously@rns.tn

A 66-year-old male patient presented to our dermatology department with a 2-month history of a nodular eruption involving the face and the limbs, which was associated with lethargy.

On clinical examination, the patient was found to have widespread papules over the face and multiple reddish nodules covering the arms and the forearms (Fig. 1a). Red-coloured infiltrated plaques were present on the upper part of the back. No gingival hyperplasia, adenopathy or splenomegaly was found.

Pathological laboratory findings were as follows: white blood cell count 32,000/ $\mu$ l, macrocytic anaemia 10 g/dl, and thrombocytopaenia 125,000/ $\mu$ l. A skin biopsy from the arm revealed a dense and diffuse infiltrate of cells within collagen bundles (Fig.1b). These cells stained positively with lysozyme.

*What is your diagnosis? See next page for answer.*



*Fig. 1. (a) Multiple reddish nodules covering the arms and forearms. (b) Dense, diffuse infiltrate of leukaemic cells within collagen bundles.*

doi: 10.2340/00015555-0860

## ANSWERS TO QUIZ

### Nodular Rash in a Male Patient: Comment

*Acta Derm Venereol* 2010; 90: XX–XX (contd).

#### **Diagnosis: Leukaemia cutis as the initial presentation of acute myelogenous leukaemia.**

Bone marrow examination revealed a diagnosis of acute myelogenous leukaemia, type 4, according to the French–American–British (FAB) classification (1). Immunophenotyping of leukaemic cells in the bone marrow showed intense immunoeexpression of HLA DR+, MPO+, CD38+, CD33+, CD65+, CD15+, CD4+, CD14+ and CD36+. On karyotype, chromosomal analysis showed trisomy 8 and trisomy 21 in all analysed mitoses.

Pulmonary and hepatic infiltrations were seen on computed tomography scan. According to these data, the patient was treated with hydroxyurea, but he died 15 days after the diagnosis was made. Skin lesions were the first clinical sign of the disease.

As in our patient, the most common presentations of leukaemia cutis are erythematous papules and nodules (2, 3). Infiltrated hemorrhagic plaques and perifollicular acneiform papules are also seen. Other less frequent forms of presentation of leukaemia cutis include erythroderma, prurigo-like eruption, psoriasis-like lesions (4), genital ulcer (5), fingertip hypertrophy, and localized cutaneous hyperpigmentation.

Leukaemia cutis has been reported to occur in 2% of patients with acute myelogenous leukaemia (6).

Most studies (2) have confirmed the highest incidence of cutaneous leukaemic infiltrates in acute myelomonocytic (M4), acute monocytic leukaemias (M5), chronic lymphocytic leukaemia and chronic myeloid leukaemia.

The mean time from diagnosis of leukaemia to the development of leukaemia cutis is 3 months in patients with acute myelogenous leukaemia. In our patient, leukaemia cutis was present at the time of diagnosis, and this enabled the diagnosis of leukaemia. There are also cases with cutaneous infiltration by leukaemic cells but without detectable blasts in the peripheral blood; a situation known as aleukaemic leukaemia cutis.

Our patient received palliative chemotherapy due to the advanced stage of the disease, which extended not only to the skin, but also to the lungs and the liver, associated with pejorative karyotype markers.

#### REFERENCES

1. Bennett JM, Catovsky D, Daniel MT, Flandrin G, Galton DA, Gralnick HR, Sultan C. Proposals for the classification of the acute leukaemias. French-American-British (FAB) co-operative group. *Br J Haematol* 1976; 33: 451–458.
2. Watson KM, Mufti G, Salisbury JR, du Vivier AW, Creamer D. Spectrum of clinical presentation, treatment and prognosis in a series of eight patients with leukaemia cutis. *Clin Exp Dermatol* 2006; 31: 218–221.
3. Su WP, Buecher SA, Li CY. Clinicopathologic correlations in leukaemia cutis. *J Am Acad Dermatol* 1984; 11: 121–128.
4. Ferreira M, Caetano M, Amorim I, Selores M. Leukemia cutis resembling a flare-up of psoriasis. *Dermatol Online J* 2006; 12: 13.
5. Senti G, Schleiffenbaum B, Dummera R. Vaginal ulcers as initial presentation of subacute myelomonocytic leukemia. *Dermatology* 1999; 199: 346.
6. Baer MR, Barcos M, Farrell H, Raza A, Preisler HD. Acute myelogenous leukaemia with leukaemia cutis. Eighteen cases seen between 1969 and 1986. *Cancer* 1989; 63: 2192–2200.