

## Tufted Angioma Associated with Kasabach-Merritt Phenomenon: A Therapeutic Challenge

Carla Ferrandiz-Pulido<sup>1</sup>, Jordi Mollet<sup>1</sup>, Constantino Sabado<sup>2</sup>, Berta Ferrer<sup>3</sup> and Vicente Garcia-Patos<sup>1</sup>

Department of <sup>1</sup>Dermatology, <sup>2</sup>Pediatric Oncology and <sup>3</sup>Pathology, Vall d'Hebron Hospital, Paseo Vall d'Hebron 119-129, ES-08035 Barcelona, Spain.

E-mail: 40879cjp@comb.cat

Accepted January 26, 2010.

Tufted angioma (TA) is an infrequently seen, benign vascular tumour, which was first described in 1949 (1). It is characterized clinically by a solitary tumour or infiltrated plaque thought to have a more inflammatory appearance than vascular. The great majority appear during the first 5 years of life; however, rare cases of TA presenting at birth have been noted (2, 3).

Kasabach-Merritt phenomenon (KMP) is a form of microangiopathic haemolysis, with coagulopathy related to the sequestration of platelets and coagulation factors within the tumour. The sequestration creates a form of disseminated intravascular coagulation, with the patients having both a propensity to clotting and a high risk of bleeding. It is an infrequent complication of TA, which represents a therapeutic challenge (4).

### CASE REPORT

A one-month-old female patient presented to our clinic with a rapidly enlarging plaque on the chin. This had been diagnosed as a congenital haemangioma. The infant, who had normal growth and development, had been delivered via caesarean section at 41 weeks after an uneventful pregnancy.

On examination, the patient was found to have a well-demarcated, irregularly shaped, reddish-violaceous plaque measuring 10 × 7 cm on the lower aspect of the chin (Fig. 1A). It was firm, slightly tender and warm to palpation. There was no evidence of hyperhidrosis or hypertrichosis.

Admission laboratory tests included haemoglobin (Hb) of 10.1 g/dl (normal range 11.8–14.7), a platelet count of 267 × 10<sup>9</sup>/l (normal range 147–386), and a normal standard biochemistry. Magnetic resonance imaging (MRI) and magnetic resonance angiography (MRA) demonstrated a vascular tumour, extending to the subcutaneous tissue on the anterior aspect of the neck, although no compression of the airway was identified. Chest radiography and a funduscopy were normal.

Empirical treatment was begun with prednisone (1 mg/kg, intravenously) and amoxicillin-clavulanic acid daily (50 mg/kg). Four days later the lesion showed no change in size and the platelet count had decreased to 17 × 10<sup>9</sup>/l. There were no signs of bleeding.

During the course of her admission, the patient continued to have severe thrombocytopaenia with consumption of fibrinogen (Hb 10.4 g/dl, white blood cells (WBC) 14.4 × 10<sup>9</sup>/l, platelets 17 × 10<sup>9</sup>/l, fibrinogen 0.3 g/dl and fibrin degradation product greater than 0.8 mg/dl). There was an associated subtle enlargement of the lesion (Fig. 1B). We therefore decided to increase the dose of prednisolone to 4 mg/kg/day and add acetylsalicylic acid (ASA) 5 mg/kg. A skin biopsy was performed to confirm the diagnosis.

The skin biopsy showed an unremarkable epidermis with extensive vascular proliferation within the superficial and deep dermis as well as the subcutaneous tissue, with scattered, quite well-circumscribed tufts in a 'cannonball' distribution. These nodules were composed of epithelioid and spindled basophilic endothelial and perithelial cells arranged around small, branching, slit-like capillaries. Some erythrocytes were present within the compressed lumina. No cytological atypia or mitoses were identified. Immunohistochemical stains with smooth muscle actin stained perithelial cells and CD31- and CD34-stained endothelial cells. WT-1 was negative, ruling against an infantile haemangioma. The diagnosis was thought to be consistent with TA associated with KMP.

The patient was discharged when the lesion decreased in size. At this time, the platelet count was greater than 170 × 10<sup>9</sup>/l on treatment with daily ASA 5 mg/kg and methylprednisolone 3 mg/kg.

Ten days after discharge, 2 months after the initial presentation, the patient was again admitted to hospital due to a sudden increase in size of the tumour with a concomitant drop in the platelet count to 35 × 10<sup>9</sup>/l. Vincristine therapy was begun (0.05 mg/kg intravenously every week). The size of the lesion decreased and the steroids were tapered. However, the patient's condition oscillated and therefore, cycles of vincristine (1.5 mg/m<sup>2</sup> body surface area), actinomycin D (500 µg/m<sup>2</sup>) and cyclophosphamide (300 mg/m<sup>2</sup>) (VAC) every 3 weeks were added. One month later, when the patient was to receive her third cycle of VAC, she presented with a platelet count of 15 × 10<sup>9</sup>/l associated with a subtle enlargement of the lesion. Although there were no signs of bleeding, we decided to give "mega-doses" of methylprednisolone (infusions up to 30 mg/kg). The patient responded well clinically and her platelet count normalized.

In the ensuing months, the patient's course was somewhat unstable, with platelet counts at times less than 10 × 10<sup>9</sup>/l. At age 7 months interferon (IFN)-α-2a was started for one month at a daily dose of 3 × 10<sup>6</sup> IU/m<sup>2</sup>. As this was well tolerated, she

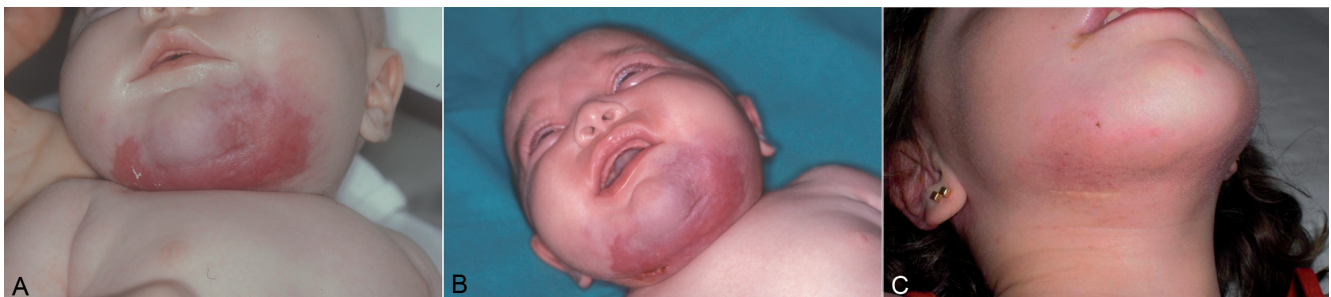

Fig. 1. (A) Tufted angioma involving the chin in a one-month-old child. (B) The patient at 2 months of age showing a subtle increase in tumour size and decrease in platelet count. (C) A subtle residual lesion on the chin of the patient at the age of 5 years.

continued treatment with  $1 \times 10^6$  IU administered 3 days per week until she completed one year of treatment. Follow-up MRI 3 months after the beginning of the treatment showed a significant decrease in tumour size. The patient had no further episodes of KMP during the year that she received interferon. One year later, the patient's vascular tumour had decreased in size dramatically and there was complete resolution of her thrombocytopenia. Fig. 2 summarizes the evolution of the KMP with regard to the treatment given.

After finishing the treatment the patient was lost to follow-up until the age of 2 years, when she was diagnosed with spastic diplegia. She is currently being followed by the rehabilitation department. Causes other than interferon- $\alpha$  iatrogenic unwanted effect were ruled out.

At 5-year follow-up, the patient has not presented with any new episodes of consumption coagulopathy and there is a subtle residual lesion on her chin (Fig. 1C). The patient is slowly starting to walk after receiving treatment with physiotherapy, tenotomies and injections of botulinum toxin.

## DISCUSSION

Therapeutic guidelines for the treatment of TA have not been established. Since spontaneous involution can occur, we feel observation seems to be the most reasonable first course of action. However, when these vascular lesions threaten life or vital functions, as KMP implies, intervention is obviously required (5). Many therapeutic modalities have been employed for KMP, with no clear evidence that any one form of treatment is superior. A multidisciplinary approach is required, with meticulous monitoring of haematological values (4).

Systemic steroids (2–4 mg prednisone every day) are generally considered the mainstay of treatment, but they are effective at shrinking the tumour in only approximately one-third of patients. Furthermore, selective amplification of glucocorticoid anti-inflammatory activity through synergistic multi-target action with antiplatelet agents, such as ASA and dipyridamole has been reported which can be useful in preventing platelet aggregation within the body of the tumour (4, 6–8).

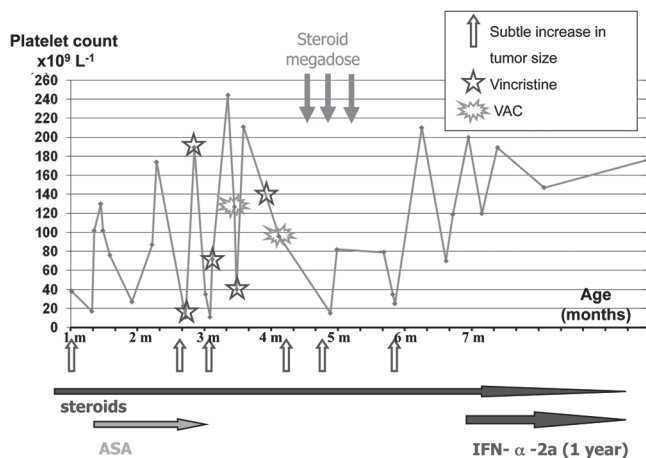


Fig. 2. Evolution of platelet count and tumour size with regard to the treatment given. VAC: vincristine, actinomycin-D, cyclophosphamide; ASA: acetylsalicylic acid; IFN; interferon.

Vincristine has been used alone or in combination with other agents in the treatment of life-threatening haemangiomas refractory to steroid treatment. Standard doses are 0.05 mg/kg in weekly intervals and should be continued until a sustained increase in platelet count has occurred.

IFN- $\alpha$  (both 2a and 2b) has been used to treat KMP that has failed to respond to systemic steroids. At a daily dose of  $3 \times 10^6$  IU/m<sup>2</sup> in subcutaneous injections it was shown to produce resolution of the coagulopathy as well as regression of the tumour (9). The main limitation of this treatment is the risk of developing serious neurological sequelae, such as spastic diplegia. Spastic diplegia has been reported to affect up to 20% of treated patients, with those under one year of age being at greater risk. A meta-analysis that included 3055 children under 12 years of age treated with IFN- $\alpha$ , led the authors to conclude that IFN- $\alpha$  should not be used in infants under one year of age, unless they have a life-threatening condition that is not responsive to any other form of treatment (10, 11). Medium-long term neurological follow-up is recommended after completion of this treatment, as spastic diplegia has been shown to present months later (12, 13).

## ACKNOWLEDGEMENTS

We would like to acknowledge Dr Sheetal Desai, Dermatology Department of New York University, for her help with the English language in this paper.

The authors declare no conflict of interest.

## REFERENCES

- Satter EK, Graham BS, Gibbs NF. Congenital tufted angioma. *Pediatr Dermatol* 2002; 19: 445–447.
- Browning J, Frieden I, Baselga E, Wagner A, Metry D. Congenital, self-regressing tufted angioma. *Arch Dermatol* 2006; 142: 749–751.
- Barco D, Baselga E, Ribé A, Alomar A. [Congenital self-limiting tufted angioma]. *Actas Dermosifiliogr* 2008; 99: 423–425 (in Spanish).
- Maguiness S, Guenther L. Kasabach-Merritt syndrome. *J Cutan Med Surg* 2002; 6: 335–339.
- Moore J, Lee M, Garzon M, Soffer S, Kim E, Saouaf R, et al. Effective therapy of a vascular tumor of infancy with vincristine. *J Pediatr Surg* 2001; 36: 1273–1276.
- Blei F, Karp N, Rofsy N, Rosen R, Greco MA. Successful and multimodal therapy for kaposiform hemangioendothelioma complicated by Kasabach-Merritt Phenomenon: case report and review of the literature. *Pediatr Hematol Oncol* 1998; 15: 295–305.
- Sadan N, Wolach B. Treatment of hemangiomas of infants with high doses of prednisone. *J Pediatr* 1996; 128: 141–146.
- Bailey JM, Makheja AN, Verma M. Corticosteroids suppress cyclooxygenase messenger RNA levels and prostanoid synthesis in cultured vascular cells. *Biochem Biophys Res Commun* 1988; 157: 1159–1163.
- Harper L, Michel JL, Enjolras O, Raynaud-Mounet N, Rivière JP, Heigele T, De Napoli-Cocci S. Successful

- management of a retroperitoneal kaposiform hemangio-endothelioma with Kasabach-Merritt phenomenon using alpha-interferon. *Eur J Pediatr Surg* 2006; 16: 369–372.
10. Barlow CF, Priebe CJ, Mulliken JB, Barnes PD, Mac Donald D, Folkman J, Ezekowitz RA. Spastic diplegia as a complication of interferon alfa-2a treatment of hemangiomas of infancy. *J Pediatr* 1998; 132: 527–530.
  11. Michaud AP, Bauman NM, Burke DK, Manaligod JM, Smith RJ. Spastic diplegia and other motor disturbances in infants receiving interferon-alpha. *Laryngoscope* 2004; 114: 1231–1236.
  12. Dubois J, Hershon L, Carmant L, Bélanger S, Leclerc JM, David M. Toxicity profile of interferon alpha-2b in children: a prospective evaluation. *J Pediatr* 1999; 135: 782–785.