

## QUIZ SECTION

## Multiple Brownish Macules on Child's Cheeks: A Quiz

Calogero Pagliarello<sup>1</sup>, Guido Massi<sup>2</sup> and Giuseppe Fabrizi<sup>3</sup><sup>1</sup>Health Services Research Unit, IDI-IRCCS, via dei Monti di Creta 104, IT-00167 Rome, <sup>2</sup>Department of Pathology, Catholic University Medical School, Rome, and <sup>3</sup>Department of Dermatology, Molise University, Campobasso, Italy. E-mail: calogero.pagliarello@libero.it

A 5-year-old Caucasian girl presented with a 6-month history of asymptomatic macules on her cheeks (Fig. 1). She had been treated with terbinafine hydrochloride 1% cream, hydrocortisone butyrate 0.1% cream and a course of amoxicillin-clavulanic acid with no improvement. Clinical examination showed multiple, scattered, rounded 2- to 4-mm in diameter macules localized on the cheeks. The lesions had regular orange-brown pigmentation. No other mucosal or cutaneous lesions were noted, and the child was otherwise well with no relevant past medical history. In particular, she had no constitutional symptoms and no evidence of lymphadenopathy or hepatosplenomegaly.

A complete blood count, erythrocyte sedimentation rate, a comprehensive metabolic panel, abdominal ultrasound

scan and systemic skeletal radiographic survey showed no abnormalities. A skin biopsy was performed for histological examination with haematoxylin and eosin staining (Fig. 2A), integrated with immunohistochemical staining with CD68 (Fig. 2B), S-100 (Fig. 2C) and CD207 (Langnerin, Fig. 2D).

What is your diagnosis? See page 558 for answer.

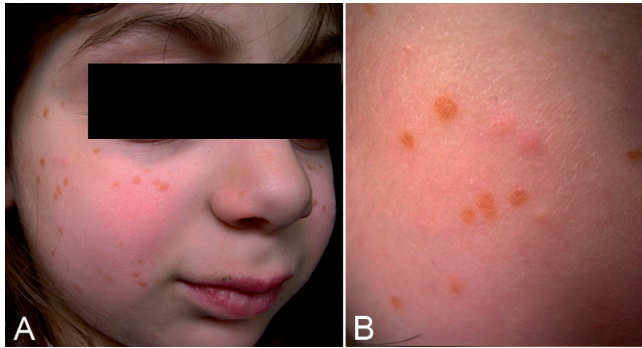

Fig. 1. (A) The child's face covered with orange-brown macules, scattered on the cheeks and periorbital region. (B) The macules are discrete and poorly circumscribed.

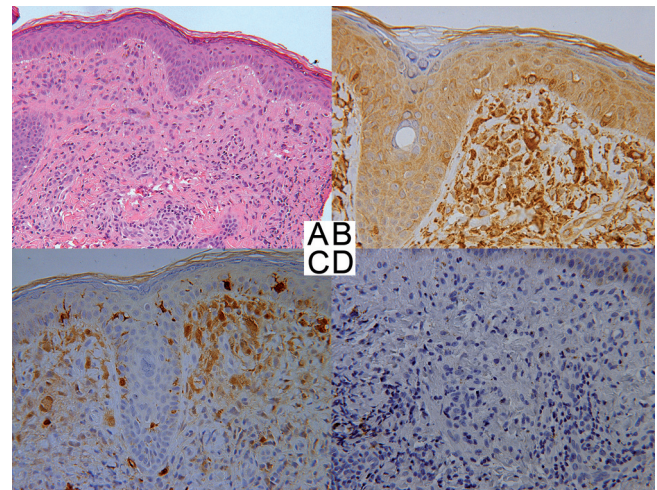


Fig. 2. (A) Within the upper part of the dermis there is an infiltration of histiocytes (haematoxylin and eosin  $\times 40$ ). Immunoreactivity for (B) CD-68, (C) S-100 and (D) CD-207.

doi 10.2340/00015555-0836

## ANSWERS TO QUIZ

**Multiple Brownish Macules on Child's cheeks: Comment**

Acta Derm Venereol 2010; 90: 555–558 (contd)

**Diagnosis: Indeterminate cell histiocytosis**

Biopsy specimen from a lesion showed a dense upper dermal infiltrate of large, round-to-ovoid, histiocytes characterized by kidney-shaped or oval nuclei and an ill-defined cytoplasm, with few admixed lymphocytes. No significant eosinophilic or plasma cells infiltration were noted. Neoplastic cells were situated immediately beneath a thinned epidermis devoid of rete ridges and were strongly positive for CD-68, positive for S-100 and negative for CD-207. Moreover, no epidermotropism, xanthomatized histiocytes or Touton giant cells were observed.

The girl's parents declined a further skin biopsy for an electron microscopy evaluation and no therapy was prescribed. After 4 years the macules have diffused all over the body and some have developed into fleshy, dome-shaped papules. No systemic involvement has been noted, as documented by extensive clinical, laboratory and radiological follow-up.

## DISCUSSION

Indeterminate cell histiocytosis (ICH) is a rare disorder characterized by the proliferation of histiocytic cells that express S-100 antigens, but, unlike Langerhans' cell histiocytosis (LCH), lack Birbeck granules. The patient reported here presented with yellow-orange macules confined to the face without visceral involvement. It should be noted that the clinical picture, with the exception of the age of patients and of the lack of regression of cutaneous lesions, shares striking similarities to that of benign cephalic histiocytosis, which represents the sole clinical differential diagnosis. Histopathological differential diagnosis includes LCH, juvenile xanthogranuloma, benign cephalic histiocytosis and the cutaneous variant of Rosai-Dorfman disease (CRDD). Besides clinical considerations, LCH can be excluded because of the lack of epidermotropism, the scarcity of eosinophils infiltrate and the absence of Birbeck granules, as documented by negativity of the CD-207 (1). Histiocytes in juvenile xanthogranuloma are vacuolated, Touton cells can be observed in the infiltrate and, finally, histiocytes are, by definition, S-100 negative; the latter feature also characterizes BCH, which can therefore be readily excluded; unlike in our case, the infiltrate in CRDD has typically a nodular appearance with emperipolesis and karyophagocytosis and presents a dense collection of plasma cells.

ICH usually presents with solitary (2, 3) or multiple asymptomatic, flesh-coloured to yellow-brown maculopapules with no site of predilection. According to the literature the clinical appearance of this case resembles one of the variants of NLCH (4). Although ICH has been described in childhood (2, 5) the mean age reported in a recent large case series was 46 years (4). In general, ICH has a good prognosis, being mostly exclusively a cutaneous disorder, but a fatal paediatric case has been described (6).

Various anecdotal treatment has been described as effective for this condition, including pure coal tar and 5% 5-fluorouracil cream (5), narrow-band ultraviolet B (7) and psoralen plus ultraviolet A phototherapy (8). Moreover, acute myeloblastic leukaemia was reported following chemotherapy for ICH (9). Taking into consideration the young age of our patient, and the presence of few cutaneous lesions limited to the face with no visceral involvement, we have chosen to not treat the child, but to monitor her clinical course closely, deferring therapy for potential progression of the disease.

## REFERENCES

1. Rezk SA, Spagnolo DV, Brynes RK, Weiss LM. Indeterminate cell tumor: a rare dendritic neoplasm. *Am J Surg Pathol* 2008; 32: 1868–1876.
2. Levisohn D, Seidel D, Phelps A, Burgdorf W. Solitary congenital indeterminate cell histiocytoma. *Arch Dermatol* 1993; 129: 81–85.
3. Berti E, Gianotti R, Alessi E. Unusual cutaneous histiocytosis expressing an intermediate immunophenotype between Langerhans' cells and dermal macrophages. *Arch Dermatol* 1988; 124: 1250–1253.
4. Ratzinger G, Burgdorf WHC, Metze D, Zelger BG, Zelger B. Indeterminate cell histiocytosis: fact or fiction? *J Cutan Pathol* 2005; 32: 552–560.
5. Rodriguez-Jurado R, Vidaurri-de la Cruz H, Duran-Mckinster C, Ruiz-Maldonado R. Indeterminate cell histiocytosis. Clinical and pathologic study in a pediatric patient. *Arch Pathol Lab Med* 2003; 127: 748–751.
6. Martin Flores-Stadler E, Gonzalez-Crussi F, Greene M, Thangavelu M, Kletzel M, Chou PM. Indeterminate-cell histiocytosis: immunophenotypic and cytogenetic findings in an infant. *Med Pediatr Oncol* 1999; 32: 250–254.
7. Ishibashi M, Ouchi T, Tanikawa A, Ishiko A. Indeterminate cell histiocytosis successfully treated with ultraviolet B phototherapy. *Clin Exp Dermatol* 2008; 33: 301–304.
8. Wang CH, Chen GS. Indeterminate cell histiocytosis: a case report. *Kaohsiung J Med Sci* 2004; 20: 24–30.
9. Vener C, Soligo D, Berti E, Gianelli U, Servida F, Ceretti E, et al. Indeterminate cell histiocytosis in association with later occurrence of acute myeloblastic leukaemia. *Br J Dermatol* 2007; 156: 1357–1361.