

## Female Pattern Hair Loss in a Patient with 17 $\alpha$ -hydroxylase Deficiency

Hsien-Yi Chiu<sup>1</sup> and Sung-Jan Lin<sup>1,2\*</sup>

<sup>1</sup>Department of Dermatology, National Taiwan University Hospital and National Taiwan University College of Medicine, No. 7 Chung-San South Road, and <sup>2</sup>Institute of Biomedical Engineering, National Taiwan University, Taipei, Taiwan. \*E-mail: drsjlin@ntu.edu.tw  
Accepted November 16, 2009.

Female pattern hair loss (FPHL) is characterized by hair loss primarily on the top of the scalp with miniaturization of hairs in the involved area and a decrease in anagen hairs. It has many similarities with male androgenetic alopecia (AGA). However, the role of androgen in FPHL is not known. We describe here a young patient with 17 $\alpha$ -hydroxylase deficiency, with extremely low levels of circulating androgen and clinical features of FPHL.

### CASE REPORT

A 20-year-old woman had a history of 17 $\alpha$ -hydroxylase deficiency, diagnosed 7 years previously. Her karyotype was 46, XY, and she was characterized clinically by female external genitalia, rudimentary testes near the orifice of bilateral internal inguinal rings and almost undetectable circulating androgens.

She visited our clinic due to progressive hair loss. Physical examination revealed non-scarring hair loss, mainly affecting the crown without fronto-temporal involvement. Her hair was generally short and thin; the frontal and parietal scalp was most severely affected, whereas the occipital scalp was relatively spared (Fig. 1b). Digital microscope (Dino-Lite™) showed miniaturized hair shafts, variation in the size of hair shafts and increased spacing between hairs over the frontal scalp and mid-scalp to the vertex (Fig. 1a). She did not have facial hirsutism, acne, or a deepened voice. A skin biopsy of the affected area revealed miniaturized hair follicles and increased vellus hairs (Fig. 1c). A slight

lymphocytic peri-infundibular infiltration was observed, but no peribulbar infiltrate was revealed. Serum testosterone, dehydroepiandrosterone sulphate and androstenedione levels were too low to be detected and 17 $\alpha$ -hydroxyprogesterone level was not analyzed at dermatologic clinic (Table I).

### DISCUSSION

Cytochrome P450 17 $\alpha$ -hydroxylase is one of the key enzymes for the synthesis of steroid hormones in the adrenal cortex and gonads (1). Patients with deficiency of this enzyme have low levels of cortisol, adrenal androgens and gonadal steroids and classically present with male pseudohermaphroditism and/or female hypogonadism (2). The clinical pattern of hair loss in our patient is consistent with FPHL. Some studies suggested that FPHL and AGA are different entities because of differences in the pattern of hair loss and the age of onset. Although the term AGA in women has been used synonymously with "FPHL", the role of androgen in FPHL has not been clearly established. Not all patients with FPHL have elevated androgen levels, and a higher incidence of elevated androgen levels is more common in women with hirsutism and/or men-

Table I. Serum hormones and potassium level in our patient with 17 $\alpha$ -hydroxylase deficiency

	Basal <sup>a</sup>	At dermatology clinic <sup>b</sup>	Normal range
FSH (mIU/ml)	86.9	96.6	1.6–9.7
LH (mIU/ml)	20.4	21.5	1.3–10.5
Testosterone (ng/ml)	<0.2	<0.2	1.3–6.1
Estradiol (pg/ml)	<20	<20	<40
Progesterone (ng/ml)	5.30	<0.2	<0.6
17-OHP (nmol/l)	1.13	ND	<15
DHEAS ( $\mu$ mol/l)	<0.81	<0.41	4.6–13.4
Androstenedione (nmol/l)	<0.35	<0.35	3.5–9.8
ACTH (pg/ml)	145	<5	10–65
Cortisol ( $\mu$ g/dl)	2.48	11.8	2.5–24
Aldosterone (ng/dl)	11.5	16.6	5–30
PRA (ng/ml/h)	0.05	5.13	1–5
K <sup>+</sup> (mmol/l)	4.6	4.3	3.5–5.3

<sup>a</sup>When 17  $\alpha$ -hydroxylase deficiency was diagnosed at the paediatric clinic.

<sup>b</sup>7 years after 17 $\alpha$ -hydroxylase deficiency was diagnosed, she presented to the dermatology clinic with hair loss and had received cortisone acetate therapy for 3 years.

ND: not determined; FSH: follicle-stimulating hormone; LH: luteinizing hormone; 17-OHP: 17-hydroxyprogesterone; DHEAS: dehydroepiandrosterone sulphate; ACTH: adrenocorticotropic hormone; PRA: plasma renin activity (at rest)

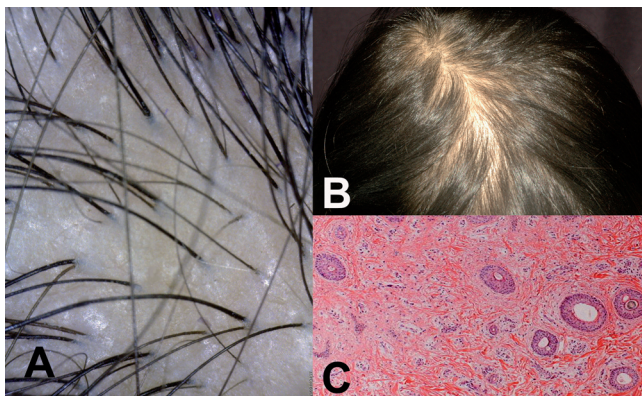


Fig. 1. (a) Decrease in hair density and obvious miniaturization of hairs over the crown (Dino-Lite™, original magnification  $\times 65$ ). (b) Hair loss mainly affects the crown. (c) Histopathology reveals miniaturized hair follicles and increased vellus hairs (haematoxylin and eosin (H&E) stain, original magnification  $\times 40$ ).

strual disturbance than that with hair loss alone (3). In our recent study report (4), a female patient receiving exogenous androgen lost her hair and responded well to finasteride therapy. This fact provides evidence of the role of androgen in some female patients with hair loss. However, most women with FPHL do not have any signs and symptoms of hyperandrogenaemia. In addition, Orme et al. (5) recently reported a young woman with hypopituitarism presenting with the clinical and histological features of FPHL in the absence of detectable levels of circulating androgens.

In conclusion, FPHL, despite the frequency in the general population, remains a poorly understood disorder. It is a clinical phenotype that is thought to have various aetiologies, all of which may be overlapping. Our report supports that hyperandrogenaemia does not necessarily lead to FPHL, and that FPHL can develop in individuals with extremely low levels of circulating androgen. Olsen (6) recommended classifying patients with FPHL into four subgroups to facilitate further clinical studies of potential new treatments: early onset with and without hyperandrogenaemia and late onset/postmenopausal with and without hyperandrogenaemia.

## ACKNOWLEDGEMENT

This work was supported in part by National Taiwan University Hospital (99S-1277 and 98S-103).

*The authors declare no conflict of interest.*

## REFERENCES

1. Rosa S, Duff C, Meyer M, Lang-Muritano M, Balercia G, Boscaro M, et al. P450c17 deficiency: clinical and molecular characterization of six patients. *J Clin Endocrinol Metab* 2007; 92: 1000–1007.
2. Mussig K, Kaltenbach S, Machicao F, Maser-Gluth C, Hartmann MF, Wudy SA, et al. 17alpha-hydroxylase/17,20-lyase deficiency caused by a novel homozygous mutation (Y27Stop) in the cytochrome CYP17 gene. *J Clin Endocrinol Metab* 2005; 90: 4362–4365.
3. Birch MP, Lashen H, Agarwal S, Messenger AG. Female pattern hair loss, sebum excretion and the end-organ response to androgens. *Br J Dermatol* 2006; 154: 85–89.
4. Hong JB, Lin SJ. A woman with iatrogenic androgenetic alopecia responding to finasteride. *Br J Dermatol* 2007; 156: 754–755.
5. Orme S, Cullen DR, Messenger AG. Diffuse female hair loss: are androgens necessary? *Br J Dermatol* 1999; 141: 521–523.
6. Olsen EA. Female pattern hair loss. *J Am Acad Dermatol* 2001; 45: S70–S80.