

QUIZ SECTION

Wrinkled Skin, Joint Pain and Dysphonia: A Quiz

Houda Hammami¹, Inés Zaraa¹, Dalenda El Euch¹, Ines Chelly², Slim Haouet², Mourad Mokni¹ and Amel Ben Osman¹
Departments of ¹Dermatology and ²Pathology, La Rabta Hospital, Jabbari, Bab Saadoun, Tunis, 1007 Tunisia. E-mail: inesrania@myway.com

A 42-year-old woman presented with generalized progressive lax skin of 10 years duration associated with dyspnoea, joint pains and dysphonia. In addition to hanging wrinkles in the nasolabial folds, the patient had striking wrinkles extending in a band-like pattern on her axillae, chest, flanks and back (Fig. 1). There were also multiple soft, erythematous or yellowish-coloured papules on her palms and soles. Her hands had a claw-like appearance, with smooth, shiny, thick, hard and erythematous skin over the fingers. The rest of the examination revealed macroglossia without superficial adenomegaly.

Histopathological examination of papular skin lesions on the palms and from the flank revealed prominent aggregates of lightly eosinophilic, amorphous material surrounding dermal vessels that stained positively with Congo red, showing green birefringence under polarized light. Elastic tissue stains revealed the absence or fragmentation of elastic fibres in the dermis.

What is your diagnosis? See next page for answer.

doi: 10.2340/00015555-0807

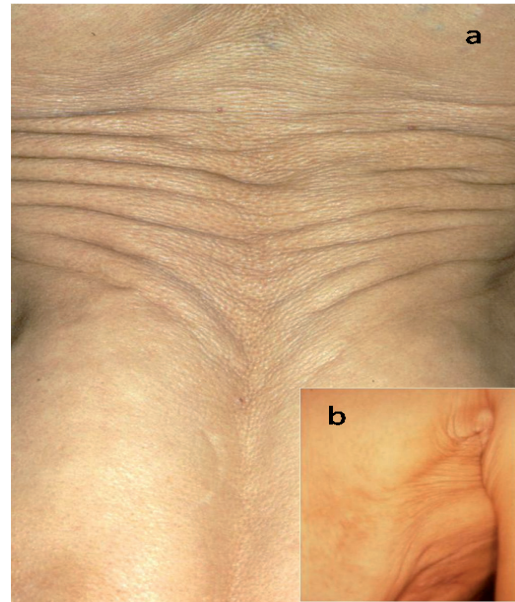


Fig. 1. Striking wrinkles on (a) the flanks and back, and (b) the axillae.

Wrinkled Skin, Joint Pain and Dysphonia: Comment

Acta Derm Venereol 2010; 90: 333–335 (contd)

Diagnosis: Generalized acquired cutis laxa, associated with primary systemic amyloidosis and monoclonal gammopathy

Serum protein electrophoresis revealed a prominent homogenous band in the mid-gamma region reacting on immunofixation as free lambda light chain. A 24-h urine protein electrophoresis was negative. A bone-marrow biopsy specimen revealed an increased number of plasma cells, which comprised 11% of the marrow cellularity. Echocardiography revealed left ventricular hypertrophy. Endolaryngeal biopsy for symptoms of dysphonia yielded the presence of amyloid deposit. Rectal and transbronchial lung biopsy showed no pathological findings.

Acquired cutis laxa (ACL) is an uncommon condition with unclear pathogenesis. The association of generalized ACL, primary amyloidosis and monoclonal gammopathy in our patient is exceptional. Eight cases of myeloma associated with generalized ACL have been reported in the literature (1–5). Generalized ACL was associated, respectively, with plasma cell dyscrasia, heavy chain deposition disease and paraproteinaemia (IgG lambda) in 4, 3 and 2 cases (1–5).

Due to the rarity of these disorders (ACL and dysglobulinaemia), a linkage has been postulated such as a possible immune-mediated elastin destruction via immunoglobulin

(Ig)G bound to dermal elastin fibres or an excessive reaction of macrophages stimulated by IgG (3). In fact, deposits of IgG on dermal elastic fibres in the skin have been reported in some patients with ACL and plasma cell dyscrasia (5) or with heavy chain deposition disease (5). Elastic fibres may also undergo destruction after binding with IgG through activation of the complement system (5). In three cases of ACL associated with myeloma, large vacuolated cells resembling macrophages were seen in the dermis. They were thought to play a role in cutis laxa (1, 5). It is hypothesized that ACL represents a paraneoplastic process of multiple myeloma (3).

REFERENCES

1. Frémont G, Kérob D, Prost-Squarcioni C, Lièvre N, Rivet J, Tancrède E, et al. Acquired cutis laxa and myeloma: large vacuolated cells in the dermis. *Ann Dermatol Venereol* 2007; 134: 548–551.
2. Gupta A, Helm TN. Acquired cutis laxa associated with multiple myeloma. *Cutis* 2002; 69: 114–118.
3. McCarty MJ, Davidson JM, Cardone JS, Anderson LL. Cutis laxa acquisita associated with multiple myeloma: a case report and review of the literature. *Cutis* 1996; 57: 267–270.
4. Appiah YE, Onumah N, Wu H, Elenitsas R, James W. Multiple myeloma-associated amyloidosis and acral localized acquired cutis laxa. *J Am Acad Dermatol* 2008; 58: S32–S33.
5. Harrington CR, Beswick TC, Susa JS, Pandya AG. Acquired cutis laxa associated with heavy chain deposition disease. *J Am Acad Dermatol* 2008; 59: S99–S101.