

## Livedoid Vasculopathy Associated with Plasminogen Activator Inhibitor-1 Promoter Homozygosity (4G/4G) and Prothrombin G20210A Heterozygosity: Response to t-PA Therapy

Joana Antunes<sup>1</sup>, Paulo Filipe<sup>1</sup>, Marisa André<sup>1</sup>, Ana Fraga<sup>1</sup>, Gabriel Miltenyi<sup>2</sup> and Manuel Marques Gomes<sup>1</sup>

<sup>1</sup>Clinica Universitária de Dermatologia, Hospital de Santa Maria, Av. Prof. Egas Moniz 1649-028, and <sup>2</sup>Genomed: Centro de Diagnóstico de Medicina Molecular, Universidade de Lisboa, Lisbon, Portugal. E-mail: joana\_antunes@hotmail.com

Accepted August 17, 2009.

Sir,

Livedoid vasculopathy (LV) is an uncommon cutaneous disease affects primarily the small blood vessels of the upper and mid dermis, and manifests clinically as livedo reticularis and recurrent shallow ulcerations on the lower extremities, that heal with irregular, ivory-white, atrophic scars. Histopathological findings classically include thickening and hyalinization of dermal vessels, with focal thrombosis. Although its pathogenesis is not yet fully understood, it is clear that LV may result from a procoagulant state (1). A number of auto-immune disorders and coagulation anomalies have been reported in association with LV, e.g. antiphospholipid syndrome (2), protein C deficiency (3), factor V Leiden mutation (4), prothrombin gene G20210A mutation (5), hyperhomocysteinaemia (6), plasminogen activator inhibitor-1 (PAI-1) polymorphism (7), Sjögren syndrome (8) and cryofibrinogenaemia (6). There is no systematic therapeutic approach to LV, but traditional treatment options include antiplatelet drugs (aspirin and dipyridamole), low-molecular-weight heparin, warfarin (4, 6) and pentoxifylline. Recent case series have been published reporting successful treatment of LV with hyperbaric oxygen therapy (HOT) (9), intravenous immunoglobulins (IVIg) (10) and psoralen-ultraviolet light. There are also anecdotal reports advocating the use of rituximab, carbamazepine and nifedipine.

### CASE REPORT

A 25-year-old female patient had since 10 years mottled bluish-red discoloration of the upper and lower limbs, which

worsened on exposure to cold. She also had recurrent painful ulcerations around the malleoli which healed by leaving stellate, porcelain-white, depressed, atrophic scars, with surrounding hyperpigmentation and telangiectasias. Three skin biopsies had been performed over the years, all showing thickened dermal blood vessels and focal hyalinization, and she had therefore been diagnosed with LV. No additional diagnostic investigation had been undertaken. She was intermittently medicated with aspirin, dipyridamole and pentoxifylline. Deflazacort would be added whenever the condition worsened. She came to our inpatient clinic with a 4-month history of painful ulcerations, cyanosis and necrosis of the distal end of three toes (Fig. 1a). She had been taking her regular therapy and had already been prescribed iloprost for 5 days, without clinical improvement.

Tests included complete blood count, erythrocyte sedimentation rate, prothrombin time, activated partial thromboplastin time, lupic anticoagulant, plasminogen, alpha 2-antiplasmin, protein S, protein C, resistance to activated protein C, antithrombin III, antiphospholipid antibody, anticardiolipin antibody, anti-beta 2 glycoprotein-1, antinuclear antibody, cryoglobulins, cryofibrinogen, factor V Leiden, prothrombin G20210A, homocysteine levels, tissue plasminogen activator (t-PA), PAI-1 and arterial and venous eco-Doppler.

While waiting for the laboratory results, the patient maintained treatment with aspirin 100 mg once a day, dipyridamole 75 mg three times a day and pentoxifylline 400 mg three times a day, as well as enoxaparin 60 mg twice a day, prednisolone 50 mg once a day, alprostadil 60 µg once a day, IVIg 0.5 g/kg for 5 days every 4 weeks, and Monday to Friday HOT for 90 min. However, despite this aggressive 3-month long treatment, the patient's condition continued to worsen, with the involvement of additional toes, intolerance to cold and severe pain.

Tests revealed heterozygosity for the prothrombin G20210A mutation and elevated levels of PAI-1 (85 nm/ml, normal value <47 µm/ml). PAI-1 genotyping showed homozygosity for the 4G/4G PAI-1 promoter region polymorphism (Fig. 1c). All other tests were normal.

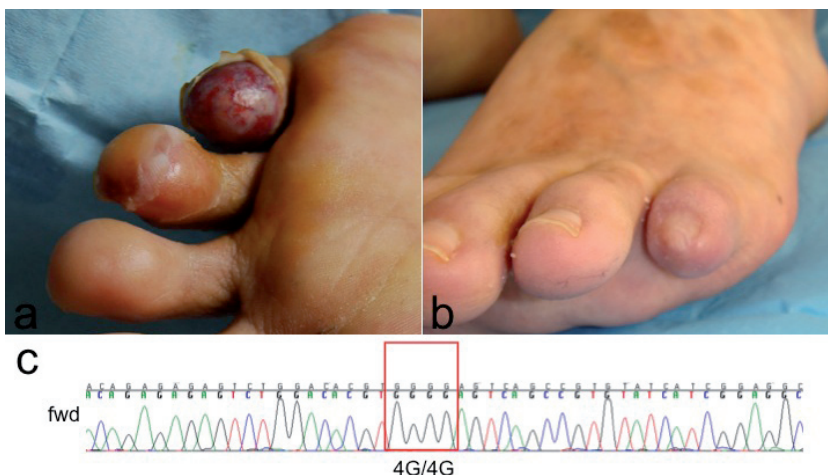


Fig. 1. (a) Shallow ulcerations and ischaemia of D4 and D5 of the left foot before treatment. (b) Resolution of the ulcerations and ischaemia 2 months after treatment with alteplase (t-Pa). Note the multiple atrophic scars with surrounding hyperpigmentation on the dorsum of the foot. (c) The 5'-3' sequence of the promoter region including the ins/del polymorphism of the PAI-1 gene. The 4G/4G homozygous polymorphism is marked with a rectangle.

Since t-PA therapy has been reported as successful treatment for LV associated with PAI-1 polymorphism (7), the patient received alteplase 10 mg once a day. Soon after the start of treatment, the patient experienced warmer extremities, less pain, livedo reticularis was less evident and there was a clearer demarcation between the ischaemic extremities and viable skin.

On the 14th day of t-PA therapy, due to a haematoma of the left iliacus muscle, alteplase infusion was suspended, as well as aspirin, dipyridamole, pentoxifylline, enoxaparin and alprostadil. Nevertheless, the clinical picture continued to improve, with progressive healing of the ulcerations and resolution of the ischaemia (Fig. 1b). The patient continued on HOT in combination with IVIg until there was complete control of the situation. After 1-year follow-up, the patient is relapse-free, and maintenance treatment consists of IVIg cycles 2 g/kg every 8 weeks.

## DISCUSSION

The current view is that LV is a primary thrombotic disturbance at the microcirculatory level, determining a local state of hypercoagulability, instead of being a vasculitic process (11).

PAI-1 is a serine protease inhibitor that suppresses fibrinolysis by specifically inactivating t-PA. High plasma concentrations of PAI-1 have been reported in association with coronary artery disease (12), ischaemic stroke and venous thrombosis. Several polymorphisms of the PAI-1 gene have been described, including a sequence length dimorphism 4G/5G (12). Subjects who are homozygous for the 4G allele (4G/4G genotype) have a higher frequency of high PAI-1 levels (13).

Prothrombin is a vitamin K-dependent proenzyme, which is converted to thrombin by activated factor X. In 1996, Poort et al. (14) described a sequence variation in the prothrombin gene (20210 G→A), which was found to be a risk factor for thrombosis (14). The prothrombin mutation 20210 A (AG genotype) leads to a normal protein, but higher prothrombin levels, compared with individuals with the GG genotype, which is the presumed mechanism of the prothrombotic phenotype (14, 15).

Both PAI-1 4G/4G genotype and prothrombin G20210A mutation are individual risk factors for thrombosis. However, individually, each of these mutations is associated with only a mild increase in the probability of a thrombotic event. The current opinion is that the PAI-1 4G allele and the prothrombin G20210A mutation increase the phenotypic expression of thrombophilia, in populations with other environmental or genetic risk factors, such as hereditary protein S deficiency or factor V Leiden (15).

To our knowledge, this is the first report of a patient with LV with PAI-1 promoter homozygosity 4G/4G and prothrombin G20210A mutation heterozygosity, which probably conferred a cumulative or synergistic effect. Given the marked improvement in the skin lesions after therapy with t-PA, a therapeutic approach targeting one of the pathophysiological defects, we recommend that a systematic search for prothrombotic risk factors should be undertaken in patients with LV, since it may influence the course of the disease, as well as the treatment strategy.

As was the case of our patient, a successful outcome resulted from combination treatment with IVIg, HOT and t-PA.

## REFERENCES

- Hairston B, Davis D, Pittelkow M, Ahmed I. Livedoid Vasculopathy: further evidence for procoagulant pathogenesis. *Arch Dermatol* 2006; 142: 1413–1418.
- Acland K, Darvay A, Wakelin S, Russell-Jones R. Livedoid vasculitis: a manifestation of the antiphospholipid syndrome? *Br J Dermatol* 1999; 140: 131–135.
- Boyvat A, Kundakci N, Babikir M, Gurgey E. Livedoid vasculopathy associated with heterozygous protein C deficiency. *Br J Dermatol* 2000; 143: 840–842.
- Kavala M, Kocaturk E, Zindanci I, Turkoglu Z, Altintas S. A case of livedoid vasculopathy associated with factor V Leiden mutation: successful treatment with oral warfarin. *J Dermatolog Treat* 2008; 19: 121–123.
- Gotlib J, Kohler S, Reichert P, Oro AE, Zehnder JL. Heterozygous prothrombin G20210A gene mutation in a patient with livedoid vasculitis. *Arch Dermatol* 2003; 139: 1081–1083.
- Browning C, Callen J. Warfarin therapy for livedoid vasculopathy associated with cryofibrinogenemia and hyperhomocysteinemia. *Arch Dermatol* 2006; 142: 75–78.
- Deng A, Gocke CD, Hess J, Heyman M, Paltiel M, Gaspari A. Livedoid vasculopathy associated with plasminogen activator inhibitor-1 promoter homozygosity (4G/4G) treated successfully with tissue plasminogen activator. *Arch Dermatol* 2006; 142: 1466–1469.
- Cardoso R, Gonçalo M, Tellechea O, Maia R, Borges C, Silva JA, Figueiredo A. Livedoid vasculopathy and hypercoagulability in a patient with primary Sjögren syndrome. *Int J Dermatol* 2007; 46: 431–434.
- Juan WH, Chan YS, Lee JC, Yang LC, Hong HS, Yang CH. Livedoid vasculopathy: long-term follow-up results following hyperbaric oxygen therapy. *Br J Dermatol* 2006; 154: 251–255.
- Kreuter A, Gambichler T, Breuckmann F, Bechara FG, Rotterdam S, Stücker M, Altmeyer P. Pulsed intravenous immunoglobulin therapy in livedoid vasculitis: an open trial evaluating 9 consecutive patients. *J Am Acad Dermatol* 2004; 51: 574–579.
- Zanini M, Wulkan C, Bertino D, Ito L. Livedoid vasculopathy or vasculitis? *An Bras Dermatol* 2003; 78: 755–757.
- Kohler H, Grant P. Plasminogen-activator inhibitor type 1 and coronary heart disease. *N Engl J Med* 2000; 342: 1792–1801.
- Martínez-Calatrava MJ, Martínez-Larrad MT, Zabena C, González-Sánchez JL, Fernández-Pérez C, Serrano-Ríos M. The 4G/4G PAI-1 genotype is associated with elevated plasma PAI-1 levels regardless of variables of the metabolic syndrome and smoking status. A population-based study in Spanish population. *Diabetes Obes Metab* 2007; 9: 134–135.
- Poort S, Rosendaal F, Reitsma P, Bertina R. A common genetic variation in the 3'-untranslated region of the prothrombin gene is associated with elevated plasma prothrombin levels and an increase in venous thrombosis. *Blood* 1996; 88: 3698–3703.
- Doggen C, Cats V, Bertina R, Rosendaal F. Interaction of coagulation defects and cardiovascular risk factors: increased risk of myocardial infarction associated with factor V Leiden or prothrombin 20210A. *Circulation* 1998; 97: 1037–1041.