

QUIZ SECTION

Unusual Features of Peristomal Erosion: A Quiz

Koji Adachi, Nanako Yamada, Yuichi Yoshida and Osamu Yamamoto

Division of Dermatology, Department of Sensory and Motor Organs, Faculty of Medicine, Tottori University, 86 Nishi-cho, Yonago-shi, Tottori 683-8503, Japan. E-mail: koujiadachi@grape.med.tottori-u.ac.jp

A 64-year-old Japanese man with a permanent ileostomy was referred to our department for evaluation of peristomal erosion. He had undergone total proctocolectomy for familial polyposis coli 27 years previously. Since then, he had continued self-care of the stoma and suffered from repeated peristomal erosions. Physical examination revealed a radial, irregular, orange-red erosion around a concave stoma on the right side of his abdomen (Fig. 1a). On dermoscopic examination, the stoma area presented as a white reticular pattern embedded in milky-red homogeneous area (Fig. 1b). Some hairpin vessels and dotted vessels were observed at the periphery of the stoma, (Fig. 1c). Biopsy specimens of the erosion showed columnar epithelial cells and goblet cells in continuity with the epidermis (Fig. 1d). There was dense infiltration of plasma cells, neutrophils, lymphocytes and eosinophils in the upper dermis (Fig. 1e).

What is your diagnosis? See next page for answer.

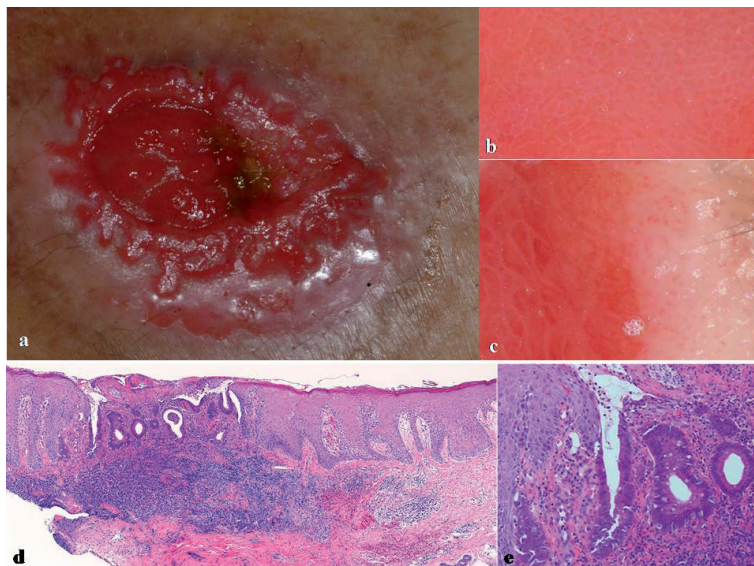


Fig. 1. (a) Ileostomy stoma on the right abdomen with ulcer. (b) Dermoscopy of the stoma. (c) Dermoscopy of the peristomal area. (d and e) Histology of a skin sample of the peristomal area (haematoxylin and eosin stain; original magnification: (d) $\times 40$, (e) $\times 400$).

doi: 10.2340/00015555-0755

Unusual Features of Peristomal Erosion: Comment

Acta Derm Venereol 2010; XX–XX (contd.)

Diagnosis: Intestinal epithelium on a peristomal erosion.

One of the most important causative factors in peristomal erosion is irritant dermatitis, particularly due to leakage of faeces, particularly in the case of a short or concave stoma (1, 2). The intestinal epithelium is thought to be more stable and have greater tolerance to faeces than skin. Thus, the intestinal epithelium was probably autotransplanted at the peristomal erosion as a kind of defence reaction to the excrement.

Dermoscopy is now used widely as a tool for diagnosing many pigmented and non-pigmented cutaneous lesions (3). However, little is known about the dermoscopic features of the mucosal area. In our case, dermoscopy of the stoma revealed a white reticular pattern in a milky-red homogenous area. Those structures became irregularly shaped and larger in the peristomal erosion, which reflects the structures of the intestinal epithelium in the lesion.

Silver nitrate cauterization, cauterization with a cautery knife, cryotherapy, and carbon dioxide laser therapy have been reported in the Japanese literature to be effective treatments (4). In the present case cryotherapy was performed with liquid nitrogen 10 times every 2 weeks, and the erosion disappeared. In addition, the size of the pouch was adjusted

appropriately to the stoma shape and the character of the faeces was controlled by the intervention of a continence nurse. There was no recurrence after treatment.

In addition, protection of the peristomal skin from exposure to faeces is very important for preventing recurrence. In our case, the patient had been suffering from peristomal erosion for approximately 8 years, but he continued with self-treatment. Therefore, appropriate stoma care was necessary. The type of pouch was changed and appropriate care was given by a wound ostomy and continence nurse. It is important that clinicians understand the mechanism of peristomal erosion and provide appropriate treatment for patients with peristomal erosion in order to improve their quality of life.

REFERENCES

1. Herlufsen P, Olsen AG, Carlsen B, Nybaek H, Karlsmark T, Laursen TN, et al. Study of peristomal skin disorders in patients with permanent stomas. *Br J Nurs* 2006; 15: 854–862.
2. Lyon CC, Smith AJ, Griffiths CEM, Beck MH. The spectrum of skin disorders in stoma patients. *Br J Dermatol* 2000; 143: 1248–1260.
3. Campos-do-Carmo G, Ramos-e Silva M. Dermoscopy: basic concepts. *Int J Dermatol* 2008; 47: 712–719.
4. Takagi Y, Toyohara T, Takahashi J. Sougou Syoukaki Care 2008; 10: 82–87. [in Japanese].