

## QUIZ SECTION

### Papular Skin Lesions in the Retroauricular Area: A Quiz

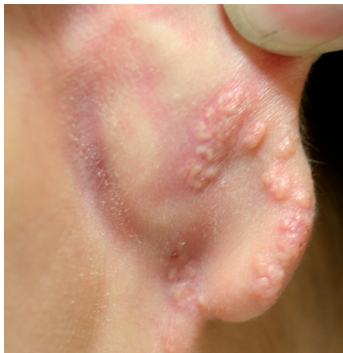Hei Sung Kim, Hyun Jong Lee, Jun Young Lee, Hyung Ok Kim and Young Min Park\*

Department of Dermatology, College of Medicine, The Catholic University of Korea, Seoul St. Mary's Hospital, #505 Banpo-Dong, Seocho-Gu, Seoul 137-701, Korea. \*E-mail: yymmpark6301@hotmail.com

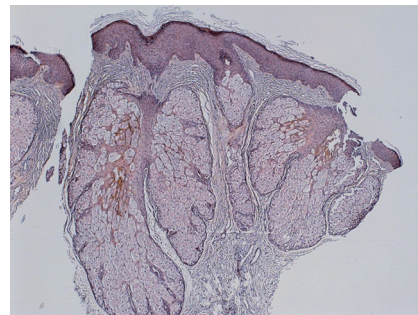
A 16-year-old Korean male presented with asymptomatic skin lesions on the posterior aspect of the right ear which he had first noticed 5 years previously (Fig. 1). He was otherwise healthy and denied any family history of similar skin problems. Our initial impression was naevus sebaceous, epidermal naevus or milia en plaque. For differentiation, a skin biopsy was taken from a representative yellow papule. Histological examination showed mild acanthosis, hyperplastic sebaceous glands with mature sebocytes grouped

in a grape-like pattern around a central duct. No papillomatosis or dilated apocrine glands were seen (Fig. 2). The patient underwent photodynamic therapy with Metvix® cream following epidermal ablation and Er:YAG fractional laser. There was some improvement after two sessions of photodynamic therapy, but the patient was subsequently lost to follow-up.

*What is your diagnosis? See next page for answer.*



*Fig. 1.* Well-demarcated, 3–6 mm diameter, skin-coloured to yellowish, centrally umbilicated papules, with the majority coalescing into plaques.



*Fig. 2.* Mild acanthosis, hyperplastic sebaceous glands with mature sebocytes grouped in a grape-like pattern around a central duct (haematoxylin and eosin; H&E, ×40).

doi: 10.2340/00015555-0740

## ANSWERS TO QUIZ

### **Papular Skin Lesions in the Retroauricular Area: Comment**

*Acta Derm Venereol* 2009; 80: xx–xx (contd)

*Diagnosis:* **Premature sebaceous hyperplasia en plaque**

Sebaceous hyperplasia commonly presents as solitary or multiple, small, yellowish, individual papules on the face, particularly on the forehead or cheeks of middle-aged to elderly individuals. Premature sebaceous hyperplasia is a benign proliferation of the sebaceous gland with an onset age varying from birth to puberty with histological findings identical to those of sebaceous hyperplasia (1).

The most commonly affected areas for both senile and premature sebaceous hyperplasia are the forehead and the mid-line of the back, which are sun-exposed areas. Reports of sebaceous hyperplasia on atypical locations, such as the areolas, nipples, penis, neck and chest, have been made, but to date there have been no reports of sebaceous gland hyperplasia on the retroauricular area (2–5).

The other unusual finding in our patient was the presence of grouped hyperplastic sebaceous glands in a plaque pattern. This had some similarities in clinical appearance with milia en plaque, which denotes a closely grouped, tiny, skin-coloured to white papules (milia), over an erythematous background. The term sebaceous hyperplasia en plaque was first mentioned by Chong et al. (6), who descri-

bed five cases of grouped, plaque-like sebaceous glands. Previously, cases of sebaceous hyperplasia presenting as a plaque were simply reported as sebaceous hyperplasia or giant sebaceous hyperplasia (7, 8), which we consider inappropriate as giant sebaceous hyperplasia refers to a single sebaceous gland with a diameter of over 1 cm.

### REFERENCES

1. Choi MJ, Kim JW, Koh BK. Solitary premature sebaceous gland hyperplasia associated with acneiform eruption. *Acta Derm Venereol* 2004; 84: 483–484.
2. Hammerton MD, Shrank AB. Superficial sebaceous hyperplasia of the areolae. *Br J Dermatol* 1993; 129: 649–650.
3. Kumar A, Kossard S. Band-like sebaceous hyperplasia over the penis. *Australas J Dermatol* 1999; 40: 47–48.
4. Jeong TJ, Shin MK, Lee MH. Linear sebaceous hyperplasia on the chest. *Clin Exp Dermatol* 2009 [E-pub ahead of print].
5. Ma HJ, Zhao G, Wang YX. Sebaceous hyperplasia of the scrotum in an adolescent boy. *Pediatr Dermatol* 2007; 24: 340–342.
6. Chong SJ, Park HJ, Oh ST, Lee JY, Cho BK. Sebaceous hyperplasia en plaque. *Ann Dermatol* 2005; 17: 75–78.
7. Oh ST, Kwon HJ. Premature sebaceous hyperplasia in a neonate. *Pediatr Dermatol* 2007; 24: 443–445.
8. Sethuraman G, Malhotra A, Khaitan BK, Verma KK, Sharma VK, Das AK, Singh MK. Pubertal giant sebaceous hyperplasia over the nose. *Clin Exp Dermatol* 2005; 30: 578–602.