

QUIZ SECTION

Cauliflower-like Lesion on the Buttock: A Quiz

Chia-Chi Tsai¹, Jie-Jen Lee¹, Chi-Kuan Chen² and Shih-Ping Cheng^{1*}

Departments of ¹Surgery and ²Pathology, Mackay Memorial Hospital, 92, Sec 2, Chung-Shan North Road, Taipei 10449, Taiwan. *E-mail: surg.mmh@gmail.com

A 38-year-old heterosexual man presented with a bulky mass lesion on his left buttock. A small polypoid lesion had been noted in the area since his childhood. It had grown slowly but steadily to a size of approximately 3 cm. In the past 2 years, however, there had been rapid growth. He denied any history of trauma or infection. His family history was insignificant. The patient was otherwise in good health. On physical examination, a huge flesh-coloured pedunculated lesion, approximately 15 × 13 cm in size, originating from the left buttock was noted (Fig. 1). It was soft in consistency and non-tender. There were no superficial changes, such as ulceration or bleeding. The shortest distance between the tumour base and the anal

verge was approximately 4 cm. His sphincter function was intact. There were no palpable lymph nodes. A wide excision with primary closure using a local rotation flap was performed. Histopathological examination showed bundles of mature fibroblasts, mild to moderate cellularity, abundant collagen stroma, and marked increase in adipose tissue entrapped between bundles of dermal collagen fibres (Fig. 2). There was no evidence of human papillomavirus (HPV) infection.

What is your diagnosis? See next page for answer.

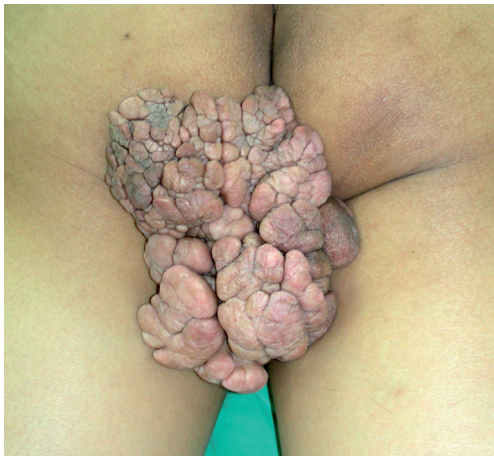

Fig. 1. A huge cauliflower-like pedunculated lesion originating from the left buttock.

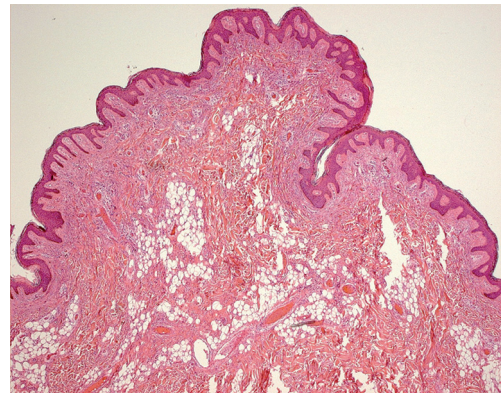


Fig. 2. Photomicrograph (haematoxylin-eosin, original magnification ×20) showing a polypoid tumour with acanthotic epidermis. The dermis is characterized by loose areolar connective tissue and ectopic adipose tissue with dilated vessels. There are no adnexal structures.

doi: 10.2340/00015555-0738

Cauliflower-like Lesion on the Buttock: Comment

Acta Derm Venereol 2009; 89: 668–671 (contd).

Diagnosis: Pedunculated lipofibroma.

Soft fibroma (also called skin tag, acrochordon or fibroepithelial polyp) is a common benign cutaneous growth (1). Three different types are described according to their clinical and histological spectrum (2). The most common type of soft fibromas is characterized by numerous tiny skin-coloured or brown papules 1–2 mm long, usually affecting the neck and axilla. The second type is characterized by single or multiple filiform lesions in varying locations, approximately 2 mm wide and 5 mm long. The third type, as seen in our patient, is large pedunculated tumours, commonly on the lower trunk, and usually 1 cm in diameter or larger.

In 1975, Mehregan et al. (3) proposed the term “pedunculated lipofibroma” for the solitary form of naevus lipomatosus cutaneus superficialis (Hoffmann-Zurhelle) in the view of its distinctive clinicopathological features. Subsequently, Nogita et al. (4) reported and reviewed 32 cases characterizing these lesions by ectopic fatty tissue in the dermis. The lesions typically present at birth or become clinically apparent in the first two decades of life. Substantially increased deposition of mucopolysaccharides in the reticular dermis and fatty tissue has been demonstrated by staining with Alcian blue. Pedunculated lipofibroma may be a hamartomatous variety of soft fibroma, although some authors argue the possibility of a fat herniation caused by a pressure mechanism (5).

The cause of soft fibromas or pedunculated lipofibromas is not known. It has been suggested that obesity is a predispo-

sing factor (6); however, our patient is relatively slim (body mass index, 22 kg/m²). Skin tags are reported to be associated with impairment of carbohydrate metabolism (7). Similarly, Nogita et al. (4) reported that 22% (7/32) of their patients had diabetes mellitus. Our patient has a normal serum glucose level. Pressure, frequent friction, and shear to the buttocks might give rise to the development of this lesion.

Generally, soft fibromas and pedunculated lipofibromas do not have malignant potential. Simple excision may be necessary for cosmetic reasons or because of irritation.

REFERENCES

1. Worm M, Skarabis W, Audring H, Sterry W, Kolde G. Nevoid bag-like soft fibromas. *Dermatology* 1999; 199: 167–168.
2. Potter TS, Sharata HH, Su WP, Hashimoto K. Pedunculated proliferative papillomatosis. *Cutis* 1996; 57: 451–452.
3. Mehregan AH, Tavafoghi V, Ghandchi A. Nevus lipomatosus cutaneus superficialis (Hoffmann-Zurhelle). *J Cutan Pathol* 1975; 2: 307–313.
4. Nogita T, Wong TY, Hidano A, Mihm MC Jr, Kawashima M. Pedunculated lipofibroma. A clinicopathologic study of thirty-two cases supporting a simplified nomenclature. *J Am Acad Dermatol* 1994; 31: 235–240.
5. Kaw P, Carlson A, Meyer DR. Nevus lipomatosus (pedunculated lipofibroma) of the eyelid. *Ophthal Plast Reconstr Surg* 2005; 21: 74–76.
6. Yosipovitch G, DeVore A, Dawn A. Obesity and the skin: skin physiology and skin manifestations of obesity. *J Am Acad Dermatol* 2007; 56: 901–916.
7. Kahana M, Grossman E, Feinstein A, Ronnen M, Cohen M, Millet MS. Skin tags: a cutaneous marker for diabetes mellitus. *Acta Derm Venereol* 1987; 67: 175–177.