

## Bowen's Disease of the Nail Matrix Presenting as Melanonychia: Detection of Human Papillomavirus Type 56

Daisuke Inokuma<sup>1</sup>, Satoru Aoyagi<sup>1</sup>, Nao Saito<sup>1</sup>, Maria Maroto Iitani<sup>1</sup>, Erina Homma<sup>1</sup>, Kokichi Hamasaka<sup>2</sup> and Hiroshi Shimizu<sup>1</sup>

<sup>1</sup>Department of Dermatology, Hokkaido University Graduate School of Medicine, N15 W7, Sapporo 060-8638, and <sup>2</sup>Hamasaka Skin Clinic, Sapporo,

Japan. E-mail: inokuma@med.hokudai.ac.jp

Accepted June 2, 2009.

Sir,

Bowen's disease (BD) is one of the most common pre-malignant conditions of the skin. It can occur at any location on the body, presenting as a reddish plaque with scales. Rare cases of presentation as lesions on the nail unit with longitudinal melanonychia have also been described (2). Trauma, exposure to radiation, and intake of arsenic have been cited as causative factors of BD (1, 2). Recently human papillomavirus (HPV), in most cases HPV type 16, has been implicated as another causal agent of BD (1). We report here a case of BD presenting as melanonychia on the nail matrix detected as HPV type 56 (HPV-56) (2, 3).

### CASE REPORT

A previously healthy 41-year-old Japanese man presented with a 2-mm-wide black streak on the nail and a 2-mm-wide, hyperkeratotic black macule on the lateral nail fold of the right index finger, which had been present for more than 2 years (Fig. 1). The Hutchinson sign was not present. There was no evidence of viral warts anywhere, including on the hands, feet and genital region, and no dark streaks in the nails of his other digits. Dermoscopic examination of the nail plate revealed longitudinal black pigmentation with

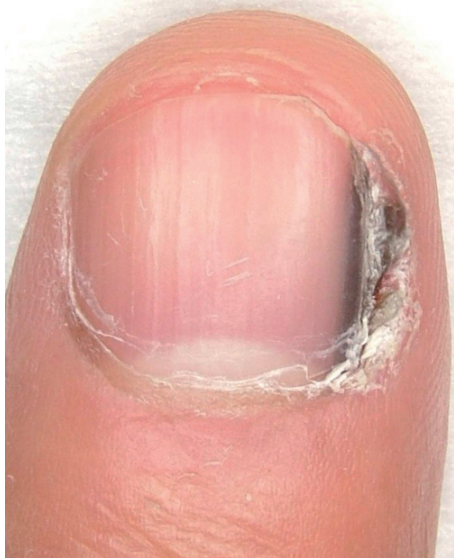

Fig. 1. A black streak on the nail and hyperkeratotic black macule on the lateral nail fold of the right index finger.

parallel regular lines. Dermoscopic findings around the nail revealed homogenous black pigmentation and hyperkeratosis without vessels. A longitudinal excisional biopsy of the nail bed and the proximal and lateral nail fold was performed. Histopathological findings revealed acanthotic epidermis with atypical dyskeratotic keratinocytes (Fig. 2a). The nuclei of the atypical cells were large, pleomorphic, hyperchromatic, and bizarre mitotic. Many granules of melanin were seen in the nail plate and the epidermis of the nail bed without increases in the number of melanocytes (Fig. 2b). The papillary dermis was not involved in the malignant process. A diagnosis of BD was made. Polymerase chain reaction (PCR) amplification for DNA of HPV-6, 11, 16, 18, 30, 31, 33, 35, 39, 45, 51, 52, 56, 59, and 66 from the tissue of the lesion was positive only for HPV-56.

### DISCUSSION

In most cases of BD with HPV, the lesions present as black papules in the genital region or as melanonychia, and the HPV detected from the lesion is typically HPV-16 (1). However, there is no information on the skin phototypes of people involved in these cases. In recent studies, however, HPV-56 has rarely been identified from BD lesions. HPV-56 was first detected from cervical intraepithelial neoplasia in 1989 (4); since then, it has frequently been detected in cervical neoplasia, in contrast to the low incidence of detection in normal cervical tissues and condylomas. At present, HPV-56 is included in the high-risk group or the mucous membrane group. In 1999, the first case of BD in an extra-genital area in which HPV-56 was detected was reported (5), and in 2003 the first case of detection of HPV-56 in the nail matrix with BD was reported (2). Since then, only two other similar cases have been reported (3). In all of these cases, the clinical features showed regular pigmented streaks and histopathological findings revealed many granules of melanin and atypical keratinocytes with large, hyperchromatic and bizarre mitotic nuclei.

In our case there were no control samples from matched locations in the same individual and, to the best of our knowledge, in others where HPV-56 has been found, there have been no control samples. In other patients with BD we examined who had no pigmentation, we did not detect HPV-56.

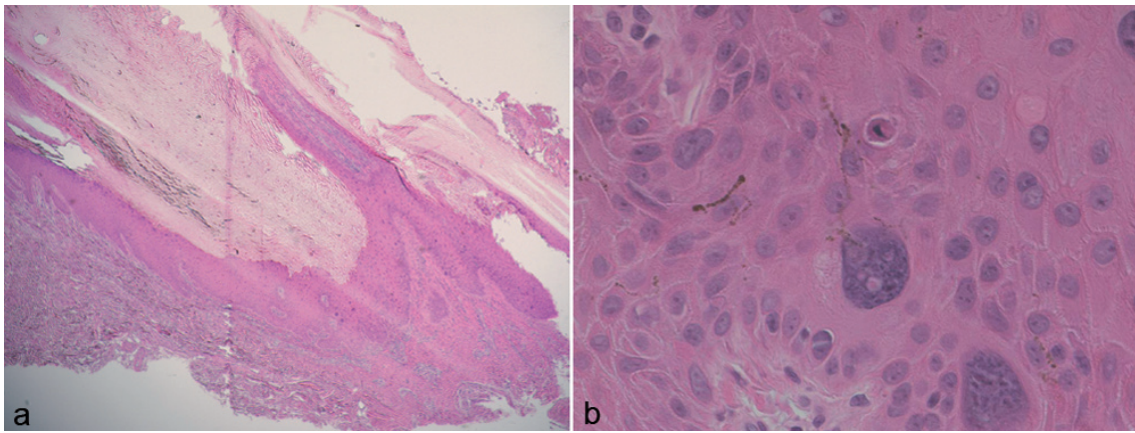


Fig. 2. (a) Acanthotic epidermis with dyskeratotic and atypical keratinocytes. (b) Large, pleomorphic, hyperchromatic, bizarre mitotic nuclei of atypical keratinocytes. Many melanin granules are seen in the nail plate and the epidermis of the nail bed. Haematoxylin and eosin (H&E) stain (a:  $\times 40$ , b:  $\times 400$ ).

We hypothesize that HPV-56 is not only associated with the pathomechanism of carcinogenesis in BD, but that it is also a causative factor of pigmentation in this disease.

*The authors declare no conflict of interest.*

#### REFERENCES

1. McHugh RW, Hazen P, Eliezri YD, Nuovo GJ. Metastatic periungual squamous cell carcinoma: detection of human papillomavirus type 35 RNA in the digital tumor and axillary lymph node metastases. *J Am Acad Dermatol* 1996; 34: 1080–1082.
2. Lambiase MC, Gardner TL, Altman CE, Albertini JG. Bowen disease of the nail bed presenting as longitudinal melanonychia: detection of human papillomavirus type 56 DNA. *Cutis* 2003; 72: 305–309; quiz 296.
3. Shimizu A, Tamura A, Abe M, Motegi S, Nagai Y, Ishikawa O, et al. Detection of human papillomavirus type 56 in Bowen's disease involving the nail matrix. *Br J Dermatol* 2008; 158: 1273–1279.
4. Lorincz AT, Quinn AP, Goldsborough MD, McAllister P, Temple GF. Human papillomavirus type 56: a new virus detected in cervical cancers. *J Gen Virol* 1989; 70: 3099–3104.
5. Uezato H, Hagiwara K, Ramuzi ST, Khaskhely NM, Nagata T, Nagamine Y, et al. Detection of human papilloma virus type 56 in extragenital Bowen's disease. *Acta Derm Venereol* 1999; 79: 311–313.