

Response of Ulcerated Necrobiosis Lipoidica to Clofazimine

Frauke Benedix, Annette Geyer, Verena Lichte, Gisela Metzler, Martin Röcken and Anke Strölin*

Department of Dermatology, University Hospital of Tuebingen, Liebermeisterstrasse 25, DE-72076 Tuebingen, Germany. *E-mail: anke.stroelin@med.uni-tuebingen.de

Accepted May 25, 2009.

Sir,

Necrobiosis lipoidica (NL) is a chronic granulomatous inflammatory disease of the skin of unknown aetiology, which can be associated with diabetes mellitus. NL is characterized by slowly growing initially erythematous plaques that turn into yellow-brown, partly telangiectatic and atrophic scars. Ulcerations occur in approximately 35% of cases.

Many therapies have been recommended for this chronic disease; nevertheless, therapeutic success is rare. We report here the successful treatment of ulcerated NL with clofazimine, without noteworthy side-effects.

CASE REPORT

A 37-year-old woman presented with a brownish maculae on the tibial side of the left lower leg, which had been present for one year. Her medical history included nicotine abuse (30 pack years) and oral antipsychotic therapy with aripiprazole. Neither diabetes mellitus nor thromboembolic diseases were reported in the patient's history or her family.

Previous treatments for suspected NL included alprostadil perfusions (60 µg/day over 10 days), medium-dose ultraviolet A1 (UVA1)-phototherapy and local treatment with chinolinosulphate and triamcinolone. During UV therapy the pre-tibial plaques ulcerated spontaneously without any trauma and were resistant to further treatment.

The patient was referred to our department with multiple, pre-tibial brownish-livid, bizarrely configured, partly sclerotic maculae and plaques, pronounced central atrophy and several fibrinous ulcerations.

Chronic venous insufficiency and peripheral arterial occlusion were excluded by digital photoplethysmography, arterial and venous dopplersonography. Laboratory tests showed normal liver enzymes, creatinine and blood count. Borrelia serology, anti-nuclear antibody screening and HbA1c were in normal ranges. Microbiological swabs detected *Staphylococcus aureus* without clinical signs of local inflammation.

The biopsy showed granulomatous inflammation involving the entire corium and the upper subcutaneous fat tissue, with homogenous necrobiosis lined by epithelioid histiocytes, foreign body giant cells and lymphoid cell aggregates with germinal centres, as well as lymphoplasmacellular infiltrations around the vessels. Histology thus confirmed the diagnosis of NL (Fig. 1a).

As the previous therapies were without effect, we started anti-inflammatory treatment with clofazimine, 100 mg/day. Local therapy included a hydrocolloid-gel, topical betamethasone dipropionate and tacrolimus, as well as compression stockings. After 4 months, considerable amelioration and healing of the ulcers was achieved. Following the increase of clofazimine to 200 mg/day, NL healed entirely within 4 weeks (Fig. 1b).

During 200 mg/day treatment with clofazimine the patient reported fatigue, xerosis cutis, slight red coloration of the urine and repeated self-limited diarrhoea without distinct impairment. Ophthalmological controls revealed dry eyes.

Following complete healing, clofazimine was reduced to 100 mg/day and the side-effects cleared without recurrence of the NL for 3 months.

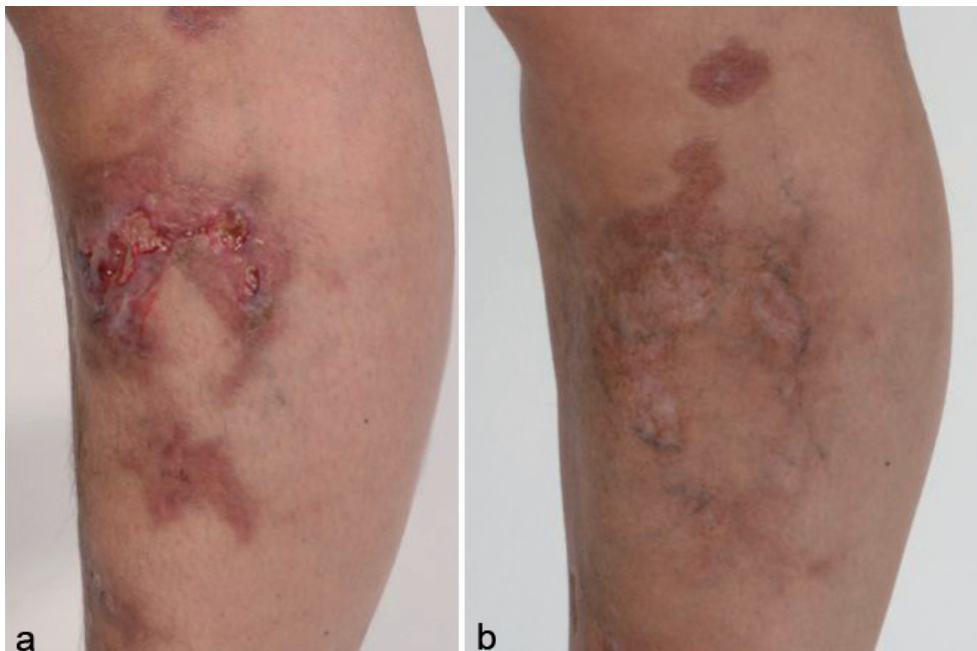


Fig. 1. (a) Left leg with pre-tibial brownish-livid, bizarrely configured, partly sclerotic maculae and slightly elevated plaques, with central atrophy and fibrinous ulcerations. (b) Complete remission of the ulcerations and amelioration of necrobiosis lipoidica after 5 months therapy with clofazimine, leading to post-inflammatory hyperpigmentation and residual atrophy.

DISCUSSION

NL was first described by Oppenheim in 1929 (1). It typically appears multiple and bilateral as yellow-brown, atrophic plaques with telangiectases on the tibial lower legs, occasionally affecting the scalp, face, upper extremity, penis or diffusely the whole body (2, 3). Ulcerations appear in one-third of patients, often after minor trauma (4). Lifelong skin controls are inevitable in NL due to the risk of squamous cell carcinoma after 6–40 years (5).

Possible pathogenetic causes include vascular factors (microangiopathy, basement membrane thickening, abnormal platelet function), decreased number of cutaneous nerves or plasma lipoproteins, abnormal collagen, and sweat gland dysfunction. Abnormal leukocyte function, immune complex mechanisms (4) and T-cell-mediated hypersensitive immune reactions have also been suspected to be responsible for NL (6).

Until now, no reliable treatment or controlled trials exist for NL. Local anti-inflammatory treatments (6, 7) as well as systemic rheological or immunosuppressive drugs have been successfully applied in single patients (8–10), but failed to show significant improvement in a controlled study (11). In 1989, Mensing (12) reported 20 patients with either disseminated granuloma annulare or NL treated with clofazimine 200 mg/day over 6–12 months, leading to complete remission in 30% and improvement >50% in another 30% of cases without serious side-effects.

Clofazimine (Lamprene) is a rhinophenatine dye used against leprosy since 1962 (13), which is also effective against atypical mycobacteriosis. *In vitro* clofazimine shows antigranulomatous effects, interactions with neutrophil granulocytes and macrophages, inhibits mitogen-induced stimulation of peripheral blood mononuclear cells (13) and stimulates phagocytosis (14) as well as pro-inflammatory enzymes. It is a lipophilic substance with an elimination half-life of 70 days. Adverse effects mostly affect discoloration of the skin, the gastrointestinal tract and the eyes.

Clofazimine accumulation in fatty tissue and subsequent oxidation probably accounts for the reddening of UV-exposed skin. Moreover, temporary red discoloration may occur in the conjunctiva, tears, nasal secretes, sweat, sputum, faeces, urine, sperm, breast milk and hair. Besides discoloration, ichthyosis is the second most frequent side-effect.

Nausea, vomiting and self-limiting diarrhoea affect up to 50% of patients. Clofazimine rarely causes hyperglycaemia and might lead to headache, tiredness and dysgeusia. Very rare, but serious and sometimes even fatal, side-effects after several months of high-dose therapy (> 100 mg daily) are small bowel enteropathy and ileus due to eosinophilic enteritis or crystal deposition and splenic infarction.

Ophthalmological side-effects are: transient discoloration, sicca-symptoms and, very rarely, corneal crystal deposits usually not affecting the vision (15). Due to the side-effects, clofazimine should not be taken for longer than 3 months in a dose over 100 mg per day.

As our patient presented with ulcerated NL that was resistant to various treatments, we administered clofazimine, leading to complete remission within 5 months and only minimal side-effects. As ulcerated NL is a therapeutic challenge, further studies are necessary to investigate reliable therapy regimens for this frequently disabling disease.

The authors declare no conflict of interest.

REFERENCES

- Oppenheim M. Eigentümlich disseminierte Degeneration des Bindegewebes der Haut bei einem Diabetiker. *Z Hautkr* 1929; 32.
- Nguyen K, Washenik K, Shupack J. Necrobiosis lipoidica diabetorum treated with chloroquine. *J Am Acad Dermatol* 2002; 46: S34–S36.
- Peyri J, Moreno A, Marcoval J. Necrobiosis lipoidica. *Semin Cutan Med Surg* 2007; 26: 87–89.
- Lowitt MH, Dover JS. Necrobiosis lipoidica. *J Am Acad Dermatol* 1991; 25: 735–748.
- Clayton TH, Harrison PV. Successful treatment of chronic ulcerated necrobiosis lipoidica with 0.1% topical tacrolimus ointment. *Br J Dermatol* 2005; 152: 581–582.
- Lim C, Tschuchnigg M, Lim J. Squamous cell carcinoma arising in an area of long-standing necrobiosis lipoidica. *J Cutan Pathol* 2006; 33: 581–583.
- Goette DK. Resolution of necrobiosis lipoidica with exclusive clobetasol propionate treatment. *J Am Acad Dermatol* 1990; 22: 855–856.
- Darvay A, Acland KM, Russell-Jones R. Persistent ulcerated necrobiosis lipoidica responding to treatment with cyclosporin. *Br J Dermatol* 1999; 141: 725–727.
- Reinhard G, Lohmann F, Uerlich M, Bauer R, Bieber T. Successful treatment of ulcerated necrobiosis lipoidica with mycophenolate mofetil. *Acta Derm Venereol* 2000; 80: 312–313.
- Drosou A, Kirsner RS, Welsh E, Sullivan TP, Kerdel FA. Use of infliximab, an anti-tumor necrosis alpha antibody, for inflammatory dermatoses. *J Cutan Med Surg* 2003; 7: 382–386.
- Statham B, Finlay AY, Marks R. A randomized double blind comparison of an aspirin dipyridamole combination versus a placebo in the treatment of necrobiosis lipoidica. *Acta Derm Venereol* 1981; 61: 270–271.
- Mensing H. Clofazimine – therapeutic alternative in necrobiosis lipoidica and granuloma annulare. *Hautarzt* 1989; 40: 99–103.
- Arbiser JL, Moschella SL. Clofazimine: a review of its medical uses and mechanisms of action. *J Am Acad Dermatol* 1995; 32: 241–247.
- Barry VC, Belton JG, Conalty ML, Denny JM, Edward DW, O'Sullivan JF, Twomey D, Winder F. A new series of phenazines (rimino-compounds) with high antituberculosis activity. *Nature* 1957; 179: 1013–1015.
- Ohman L, Wahlberg I. Letter: ocular side-effects of clofazimine. *Lancet* 1975; 2: 933–934.