

QUIZ SECTION

Facial Purpura and Scrotal Swelling: A Quiz

Masato Mizuashi¹, Ryuhei Okuyama^{1*}, Noriko Matsumura², Kentaro Sugisaki³ and Setsuya Aiba¹

¹Department of Dermatology, Tohoku University Graduate School of Medicine, 1-1 Seiryomachi, Aoba-ku, Sendai, 980-8574 and Divisions of

²Dermatology and ³Nephrology, Sendai Shakaihoken Hospital, Sendai, Japan. *E-mail: rokuyama@mail.tains.tohoku.ac.jp

A 56-year-old Japanese man was treated with systemic corticosteroids in a local hospital for a 6-year history of purpuric eruptions affecting the upper and lower eyelids, neck and upper chest. He had frequent relapses of the eruptions, together with fever and knee joint pain. One year previously, he had presented with haemorrhagic diverticula in his colon, which were surgically resected. Two months previously, he had presented with haematuria and proteinuria.

Examination revealed a purpuric maculopapular rash with prominent oedema on bilateral upper and lower eyelids, and palpable purpuric macules, 2–5 mm in diameter, scattered on the neck and upper chest (Fig. 1a). Laboratory examinations showed an increased white blood cell count of 9250/mm³ and elevated anti-streptolysin-O titre of 316 mg/dl (normal range <160 mg/dl). Serum IgA was increased (541 mg/dl; normal range 91–391 mg/dl). Liver and renal function tests showed normal values except blood urea nitrogen: 22 mg/dl (normal range <15 mg/dl). Skin biopsy from the upper eyelid revealed massive perivascular cell infiltrate composed of neutrophils in the upper and mid-dermis, which was associated with nuclear dust, necrosis of endothelial cells and fibrinoid degeneration (Fig. 1b). IgA deposition was observed along the small blood vessel walls in the upper dermis by direct immunofluorescence staining.

He was treated with infusion of polyclonal immunoglobulin (20 g/day for 5 days) together with tonsillectomy,

which led to improvement of his symptoms. However, 4 months after the treatment, oedematous swelling and tenderness developed in the scrotum together with fever.

What is your diagnosis? See next page for answer.

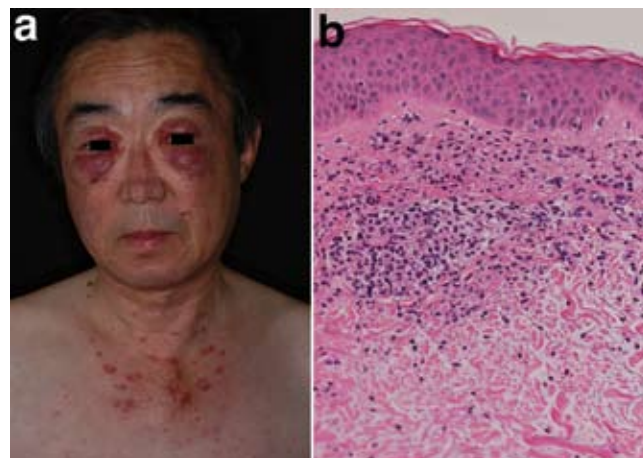


Fig. 1. (a) Clinical features of the purpuric maculopapular eruption on the face and upper chest, and (b) histopathological features of the purpuric skin (haematoxylin-eosin stain; $\times 200$).

doi: 10.2340/00015555-0700

Facial Purpura and Scrotal Swelling: Comment

Acta Derm Venereol 2009; 89: xx–xx (contd.)

Diagnosis: Henoch-Schönlein purpura

Henoch-Schönlein purpura (HSP) is a common vasculitis characterized by the presence of palpable purpuras distributed chiefly on the lower legs, and is occasionally associated with nephritis, bowel angina and gastrointestinal bleeding. Severe clinical symptoms, including renal dysfunction, frequently occur in adulthood (1, 2). Based on the facial eruption, we should consider the possibility of Sweet's disease. However, purpuric skin eruptions showed leukocytoclastic vasculitis with IgA deposition, and IgA nephropathy developed simultaneously, which did not occur in Sweet's disease. Facial rash without the involvement of lower legs occurs in a small number of childhood cases (3). According to Tancrede-Bohin et al. (4), the spread of purpura to the trunk occurred in 58% of patients with HSP with renal dysfunction. Furthermore, it was suggested that IgA glomerulonephritis was associated with purpura above the waist together with a recent history of infection and pyrexia.

The incidence of scrotal manifestation was reported to range from 2% to 38% of HSP cases (5). The scrotal wall,

epididymis, testis, testicular appendage and spermatic cord are usually involved. The scrotal manifestation usually disappears within one month and does not require aggressive treatment.

REFERENCES

1. Blanco R, Martinez-Taboada VM, Rodriguez-Valverde V, Garcia-Fuentes M, Gonzalez-Gay MA. Henoch-Schonlein purpura in adulthood and childhood: two different expressions of the same syndrome. *Arthritis Rheum* 1997; 40: 859–864.
2. Ilan Y, Naparstek Y. Henoch Schonlein purpura in children and adults: is it one entity? *Semin Arthritis Rheum* 2002; 32: 139–140.
3. Nussinovitch M, Prais D, Finkelstein Y, Varsano I. Cutaneous manifestations of Henoch-Schonlein purpura in young children. *Pediatr Dermatol* 1998; 15: 426–428.
4. Tancrede-Bohin E, Ochonisky S, Vignon-Pennamen MD, Flageul B, Morel P, Rybojad M. Schonlein-Henoch purpura in adult patients. Predictive factors for IgA glomerulonephritis in a retrospective study of 57 cases. *Arch Dermatol* 1997; 133: 438–442.
5. Hara Y, Tajiri T, Matsuura K, Hasegawa A. Acute scrotum caused by Henoch-Schonlein purpura. *Int J Urol* 2004; 11: 578–580.